

# BjP

## Belgian Journal of Paediatrics

Publication of the Belgian Society of Paediatrics



BELGISCHE VERENIGING  
VOOR KINDERGENEESKUNDE  
SOCIÉTÉ BELGE DE PÉDIATRIE

### 2022 - Volume 24 - number 2 - June



#### Articles

Pulse oximetry to screen for critical congenital cardiopathy in neonates: current practices in Flanders

Postnatal cytomegalovirus infection in extremely preterm infants receiving raw mother's own milk: clinical course and neurodevelopment at two years

Invasive meningococcal disease and vaccination in Belgium: a critical review of the current vaccination strategy

#### Case Reports

Case series of Multisystem Inflammatory Syndrome in Children (MIS-C) after a SARS-CoV-2 infection

Vacuum delivery: 2 cases of subgaleal haemorrhage

Pneumococcal endocarditis in a 10-year-old child with Marfan syndrome: case report

Rubella vaccine associated cutaneous granulomatous disease as initial manifestation of an inborn error of immunity: a case report

Early infantile epileptic encephalopathy: unique characteristics on brain MRI leading towards diagnosis of SLC13A5 gene mutation. Case report and literature review

Self-Limiting Sternal Tumour of Childhood: a case report

Borrelial Lymphocytoma in children: don't miss this skin marker of Lyme Disease

Familial hemophagocytic lymphohistiocytosis type 3: case report

A case report of a rare cause of hypophosphatemic rickets-cystinosis

Pituitary stalk interruption syndrome. Case report and literature study

Painful proptosis and compressive optic neuropathy in an 11-year-old girl with tuberculosis

#### Made In Belgium

Long-term outcomes of hypospadias: Urological and psychosexual function and endocrine-reproductive capacity

#### Paediatric Cochrane Corner

Music therapy for autistic people

Belgische Vereniging voor Kindergeneeskunde  
Soci t  Belge de P diatrie

QUARTERLY

ISSN 2466-8907 (printed version)

ISSN 2566-1558 (digital version)

V.U./E.R. S. C. Chantrain (CHC-Li ge), M. Raes (KUL)

UZ Leuven, Herestraat 49, 3000 Leuven

E-mail: BJ-Ped@hotmail.com



jusqu'à 3 ans

# Nouvel emballage 100% recyclable Toujours notre même formule au plus proche du lait maternel

**DUO BIOTIK**

HMO's 2'FL & 3'GL  
Prébiotiques scGOS:lcFOS (9:1)  
Postbiotiques  
β-palmitate  
ARA & DHA

- Soutient le système immunitaire** (1-6)
- Selles molles proches de celles des bébés allaités** (7-8)
- Digestion facile** (8-9)

**Important :** l'allaitement maternel est l'alimentation idéale pour les bébés.  
Information destinée exclusivement au corps (para)médical. E.R.: N.V. Nutricia België - Quai des Usines 160 - 1000 Bruxelles

(1) Roberfroid M, et al. British Journal of Nutrition. 2010;104(S2):S1-S63; (2) Boehm G, et al. Arch. Dis Child. 2002;86:F178-81; (3) Bruzzese E, et al. Clin Nutr. 2009;28(2):156-161; (4) Knol J, et al. J Pediatr Gastroenterol Nutr. 2003;36:566; (5) Knol J, et al. J Pediatr Gastroenterol Nutr. 2005;40:36-42; (6) Tims S, et al. J Pediatr Gastroenterol Nutr. 2018;66(S2):1-1177; (7) Rodriguez-Herrera A, et al. J Pediatr Gastroenterol Nutr. 2016a;62:Abstract G-P-230:422; (8) Havlicekova, et al. Nutrition Journal. 2016;15:28; (9) Garçette K, et al. Med. Enfance. 2007;27:3-7.

## Editorial Board

### Founding editors

L. Corbeel, W. Proesmans

### Chief Editors

C. Chantrain, M. Raes

### Associate Editors

C. Barrea, O. Danhaive, I. Decuyper, S. De Rechter,  
E. Duval, N. Francotte, L. Hoste, L. Panneel, A. Rochtus,  
K. Van De Maele, Y. Vandenplas, K. van Hoeve, A. Vuckovic,  
M. Wojciechowski

### Secretariat

N. Meignen

### Universities

G. Buyse (UZ Leuven), MC Seghaye (ULG),  
P. Smeesters (ULB), S. Van Daele (UZ Gent)  
I. Gies (VUB), S. Moniotte (UCL), S. Verhulst (UZA)

### BVK-SBP Executive Committee

M. Raes, President  
F. Smets, Vice-president  
G. Buyse, Secretary  
P. Smeesters, Secretary  
D. Dewolf, Treasurer  
A. Malfroot, Past-president  
D. Van Gysel, International societies

### Associations

A. Bael (VVK)  
P. Philippet (GBPF)

### Belgian Academy of Paediatrics

A. De Guchteneere, President  
S. Moniotte, vice-president  
T. Jonckheer, Secretary  
P. Philippet, treasurer

## Contents

• <b>Editorial</b>	89
• <b>Articles</b>	
<b>Pulse oximetry to screen for critical congenital cardiopathy in neonates: current practices in Flanders</b> R. Cornelissen, K. Allegaert	91
<b>Postnatal cytomegalovirus infection in extremely preterm infants receiving raw mother's own milk: clinical course and neurodevelopment at two years</b> H. Dumonceau, A.-B. Johansson, A. Vuckovic	94
<b>Invasive meningococcal disease and vaccination in Belgium: a critical review of the current vaccination strategy</b> D. Tuerlinckx, M. Raes, M. Wojciechowski, W. Mattheus, L. Derycker, K. Billiaert, J.-M. Heine, J. Y Verbakel	103
• <b>Case Reports</b>	
<b>Case series of Multisystem Inflammatory Syndrome in Children (MIS-C) after a SARS-CoV-2 infection</b> M. Geeurickx, S. Vermaning, T. Crijnen, I. Gerard, E. Vanderschaeghe, A. Raaijmakers	111
<b>Vacuum delivery: 2 cases of subgaleal haemorrhage</b> M. Rosimont, S. Tribolet, N. Henny, R. Viellevoe, L. Rauw, P. Petit, V. Rigo	116
<b>Pneumococcal endocarditis in a 10-year-old child with Marfan syndrome: case report</b> L. Thienpont, P. Van Gyseghem, C. Fricx, A. Bondue, N. Arribard, H. Demanet, C. Joris, F. Vermeulen, M. Rodesch	120
<b>Rubella vaccine associated cutaneous granulomatous disease as initial manifestation of an inborn error of immunity: a case report</b> S. Schroven, M. Ulicki, M. De Bruyne, J. Van Kampen, C. Bonroy, V. Siozopoulou, V. Bordon, J. Leysen, F. Haerynck, K. Vanden Driessche	124
<b>Early infantile epileptic encephalopathy: unique characteristics on brain MRI leading towards diagnosis of SLC13A5 gene mutation. Case report and literature review</b> D. Dinneweth, P. Snijder, C. van der Starre, D. Roofthoof, L. Smit	128
<b>Self-Limiting Sternal Tumour of Childhood: a case report</b> S. Schipper, K. de Schaetzen	133
<b>The medical and ethical challenges of extremely low birth weight infants with severe comorbidity: a case report of a 26 weeks old neonate with Maple Syrup Urine Disease</b> P. Debouver, L. Garabedian, P. Verloo, A. Keymeulen	135
<b>Borrelial Lymphocytoma in children: don't miss this skin marker of Lyme Disease</b> V. Kaisina, M. Hoyoux, S. Vaessen, V. Bernier	138
<b>Familial hemophagocytic lymphohistiocytosis type 3: case report</b> L. Guérit, S. Balbeur, N. Bilem, B. Brichard, C. Boulanger	140
<b>A case report of a rare cause of hypophosphatemic rickets-cystinosis</b> M. Vandenbroucke, F. Depasse, N. Ranguelov, E. Cavatorta, O. Gilliaux	143
<b>Pituitary stalk interruption syndrome. Case report and literature study</b> A. Jeunen, L. Sevenants, T. Deprest, K. Casteels	147
<b>Painful proptosis and compressive optic neuropathy in an 11-year-old girl with tuberculosis</b> L. Saikali, H. Segers, F. Vermeulen, P. Demaerel, I. Casteels	150
• <b>Made In Belgium</b>	
<b>Long-term outcomes of hypospadias: Urological and psychosexual function and endocrine-reproductive capacity</b> Lloyd J.W. Tack	155
• <b>Paediatric Cochrane Corner</b>	
<b>Music therapy for autistic people</b> A.-C. Vanhove, T. Bekkering, F. Cools	158
• <b>Editorial Policy</b>	159



HET LEVEN  
IS GEEN  
KINDERSPEL

LA VIE  
N'EST PAS  
UN JEU  
D'ENFANT

DE BVK BEDANKT ZIJN PARTNERS  
VOOR HUN STEUN

LA SBP REMERCIE SES PARTENAIRES  
POUR LEUR SOUTIEN



We care for children



BELGISCHE VERENIGING  
VOOR KINDERGENEESKUNDE  
SOCIÉTÉ BELGE DE PÉDIATRIE

## Editorial

There was no specific theme for this June issue of the Belgian Journal of Paediatrics. So, we have decided to make it a « Special Holiday Edition ». We have used the characters of the Belgian comic strip to illustrate it with humor and derision because, yes, holidays are a serious business!

Holidays are a parenthesis that allows us all to change our rhythm, to do other activities, to travel and to discover other horizons, to spend time together... in few words... to recharge our batteries!

But a quick search on pubmed made us realize that vacations also need the attention of the medical community and particularly of the pediatric world. By typing the keywords "children" and "vacation" into the pubmed search engine, we obtained 243 references that deal with positive or negative aspects of this time of the year.

As illustrated by our cartoonist Serge Ernst, intense or prolonged sun exposure may have many effects. To prevent adverse events such as sunburns and long-term risk of skin cancer, protection with sunscreen is necessary. In paediatrics, this is widely relayed to families. However, this raises the question of vitamin D status and risk of deficiency. A recent consensus paper published in the British Journal of Dermatology concludes that the judicious use of daily broad-spectrum sunscreens with high ultraviolet (UV) A protection will not compromise vitamin D status in healthy people. However, photo-protection strategies for patients with photosensitivity disorders that include high sun-protection factor sunscreens with high UVA protection, along with protective clothing and shade-seeking behaviour are likely to compromise vitamin D status. Therefore, sunscreens remain highly recommended to prevent sunburn and screening for vitamin D status and supplementation are recommended in patients with photosensitivity disorders (1).

Outdoor activities and travel are also associated with an increased risk of insect bites, infections with unusual germs or parasites and trauma. Several studies in trauma centers of various European and North American countries register a peak of paediatric fractures in spring and summer. This corresponds to an increase in physical activity. However, some analyses reveal a lower incidence in July corresponding to a low level of sport activities during the summer vacations. This decrease could also be attributed to families going on vacation in the countryside or travelling abroad (2). Surprisingly, several papers show that children's physical activity decreases during school vacations. Less structured days and reduced participation in organized activities may explain part of this decrease (3). Similarly, emerging evidence suggests that children become fatter and less fit over the summer holidays. A recent Australian study revealed that holidays are characterised by longer sleep and higher TV and videogame time, lower vigorous activity, and lower total daily energy expenditure. Uncompensated by dietary adjustments, these differences result in an accumulation of about 650 g of fat over a six-week holiday period (4).

Studies of mental health and cognitive development have shown that time away from school may also be at risk for regression, particularly in social settings where school stimulation is not replaced by adequate supervision (5). This trend was unfortunately observed by many during the COVID 19 pandemic containment measures. Holidays have also an effect on treatment adherence. For instance, Leggett and co reported that medication adherence was reduced during school holidays and on weekends in children with type 1 diabetes (6).

The message of this editorial is certainly not to minimize the need and the benefits of vacations for children, adults, and family life. The points we put forward emphasize the importance of prevention campaigns about vacations. It is useful to accompany our patients and their parents in these changes of rhythm and environment of life. Vacations show the fundamental role of school and teachers. Holidays are an awareness of the responsibilities of parents and grandparents. They underline the place of the family unit in the sustainable development of our children and our societies.

This holiday edition is also the opportunity to highlight the work of our colleagues during these last months. We publish 2 research articles about pulse oximetry to screen for critical congenital cardiopathy in neonates (by Ria Cornelissen and Karel Allegaert) and postnatal cytomegalovirus infection in extremely preterm infants receiving raw milk (by Helene Dumonceau, Anne-Britt Johansson, and Aline Vukovic). The Made in Belgium sections summarize the Ph.D. thesis of Lloyd Tack from UZ Ghent about long-term outcomes of hypospadias with a particular focus on urological and psycho-social function and endocrine reproductive capacity. Several case reports are also published in the fields of paediatric endocrinology, infectiology and neonatology and neurology. We finish this issue on an original touch with the Cochrane Corner reviewing the interest of therapy for autistic people.

On behalf of the editorial board, we wish you a fruitful reading and resourcing summer holidays.

**Christophe Chantrain and Marc Raes**

### References

1. Passeron T, Bouillon R, Callender V, Cestari T, Diepgen TL, Green AC, et al. Sunscreen photoprotection and vitamin D status. *Br J Dermatol.* 2019;181(5):916-31.
2. Lund AR, Faergemann C, Lauritsen JM. A population-based study of seasonal variation in children's fractures. *Dan Med J.* 2021;68(10):A12200934.
3. Emm-Collison LG, Lewis S, Reid T, Matthews J, Sebire SJ, Thompson JL, et al. Physical Activity during the School Holidays: Parent Perceptions and Practical Considerations. *Int J Environ Res Public Health.* 2019;16(10):1697.
4. Olds T, Maher C, Dumuid D. Life on holidays: differences in activity composition between school and holiday periods in Australian children. *BMC Public Health.* 2019;19(Suppl 2):450.
5. Kromydas T, Campbell M, Chambers S, Boon MH, Pearce A, Wells V, et al. The effect of school summer holidays on inequalities in children and young people's mental health and cognitive ability in the UK using data from the millennium cohort study. *BMC Public Health.* 2022;22(1):154.
6. Leggett C, Giles L, Anderson JJA, Doogue M, Couper J, Pena AS. Adherence to metformin is reduced during school holidays and weekends in children with type 1 diabetes participating in a randomised controlled trial. *Arch Dis Child.* 2019;104(9):890-4.

**Uw vragen of commentaar  
Vos questions ou commentaires**



BELGISCHE VERENIGING  
VOOR KINDERGENEESKUNDE  
SOCIÉTÉ BELGE DE PÉDIATRIE

**Comité de rédaction - Redactieraad  
M. Raes - Chr Chantrain**

Gasthuisberg - Kindergeneeskunde

Herestraat 49 - 3000 Leuven

E-mail BJJ-Ped@hotmail.com

PUBLIEKSPRIJS €86.52

# VACCINEER MET VERTROUWEN TEGEN MenB

  
**BEXSERO**  
Meningokokken groep B-vaccin  
(rDNA, component, geadsorbeerd)

**BEXSERO is geïndiceerd voor de actieve immunisatie van personen van 2 maanden en ouder tegen invasieve meningokokkenziekte veroorzaakt door *Neisseria meningitidis* groep B.**

**VERKORTE SAMENVATTING VAN DE PRODUCTENMERKEN:** Gelieve de Samenvatting van de Productkenmerken te raadplegen voor de volledige informatie over het gebruik van dit geneesmiddel. **NAAM VAN HET GENEESMIDDEL:** Bexsero suspensie voor injectie in voorgevulde spuit. Meningokokken groep B (rDNA, component, geadsorbeerd) - EU/1/12/812/001; EU/1/12/812/002; EU/1/12/812/003; EU/1/12/812/004. Farmacotherapeutische categorie: meningokokkenvaccins. ATCode: J07AH09. **KWALITATIEVE EN KWANTITATIEVE SAMENSTELLING:** Een dosis (0,5 ml) bevat: **Recombinant *Neisseria meningitidis* groep B NHBAfusie-eiwit<sup>1,2,3</sup>:** 50 microgram. - **Recombinant *Neisseria meningitidis* groep B NadA-eiwit<sup>1,2,3</sup>:** 50 microgram. - **Recombinant *Neisseria meningitidis* groep B fHbpfusie-eiwit<sup>1,2,3</sup>:** 50 microgram. **Buitenmembraanvesikels (BMV) van *Neisseria meningitidis* groep Bstam NZ98/254, gemeten als hoeveelheid totaal eiwit dat PorA P1.4 bevat<sup>1,2</sup>:** 25 microgram. <sup>1</sup> Geproduceerd in *E. coli* cellen door recombinant-DNA-technologie. <sup>2</sup> Geadsorbeerd aan aluminiumhydroxide (0,5 mg Al<sup>3+</sup>). <sup>3</sup> NHBA (*Neisseria* heparinebindend antigeen), NadA (*Neisseria* adhesine A), fHbp (factor B-bindend eiwit). Voor de volledige lijst van hulpstoffen, zie rubriek 6.1 van de volledige SPK. **Therapeutische indicaties:** Bexsero is geïndiceerd voor de actieve immunisatie van personen van 2 maanden en ouder tegen invasieve meningokokkenziekte veroorzaakt door *Neisseria meningitidis* groep B. Bij het vaccineren moet rekening worden gehouden met het effect van invasieve ziekte bij verschillende leeftijdsgroepen, evenals met de variabiliteit van de epidemiologie van antigenen voor groep B stammen in verschillende geografische gebieden. Zie rubriek 5.1 van de volledige SPK voor informatie over bescherming tegen specifieke groep B stammen. Dit vaccin dient te worden gebruikt in overeenstemming met officiële aanbevelingen. **Dosering en wijze van toediening: Dosering: Tabel 1. Samenvatting van de dosering: Leeftijd bij eerste dosis: Zuigelingen van 2 tot en met 15 maanden: Primaire immunisatie:** Drie doses, elk van 0,5 ml. **Intervallen tussen primaire doses:** Niet minder dan 1 maand. **Booster:** Ja, één dosis tussen 12 en 15 maanden oud met een interval van ten minste 6 maanden tussen de primaire serie en de boosterdosis<sup>1,2,3,4</sup>. - **Primaire immunisatie:** Twee doses, elk van 0,5 ml. **Intervallen tussen primaire doses:** Niet minder dan 2 maanden. **Booster:** Ja, één dosis tussen 12 en 15 maanden oud met een interval van ten minste 6 maanden tussen de primaire serie en de boosterdosis<sup>1,2,3,4</sup>. - **Leeftijd bij eerste dosis: Zuigelingen van 6 tot en met 11 maanden: Primaire immunisatie:** Twee doses, elk van 0,5 ml. **Intervallen tussen primaire doses:** Niet minder dan 2 maanden. **Booster:** Ja, één dosis in het tweede levensjaar met een interval van minimaal 2 maanden tussen de primaire serie en de boosterdosis<sup>1,2,3,4</sup>. - **Leeftijd bij eerste dosis: Kinderen van 12 tot en met 23 maanden: Primaire immunisatie:** Twee doses, elk van 0,5 ml. **Intervallen tussen primaire doses:** Niet minder dan 2 maanden. **Booster:** Ja, één dosis met een interval van 12 tot en met 23 maanden tussen de primaire serie en de boosterdosis<sup>1,2,3,4</sup>. - **Leeftijd bij eerste dosis: Kinderen van 2 tot en met 10 jaar: Adolescenten (11 jaar of ouder) en volwassenen<sup>5</sup>:** Primaire immunisatie: Twee doses, elk van 0,5 ml. **Intervallen tussen primaire doses:** Niet minder dan 1 maand. **Booster:** Een boosterdosis dient overwogen te worden bij personen met een blijvend risico op blootstelling aan meningokokkenziekte, op basis van officiële aanbevelingen<sup>4, 6</sup>. - <sup>1</sup> De eerste dosis moet niet worden gegeven op de leeftijd jonger dan 2 maanden. De veiligheid en werkzaamheid van Bexsero bij zuigelingen jonger dan 8 weken zijn nog niet vastgesteld. Er zijn geen gegevens beschikbaar. <sup>2</sup> In geval van uitstel mag de booster niet later dan op een leeftijd van 24 maanden worden gegeven. <sup>3</sup> Zie rubriek 5.1 van de volledige SPK. De noodzaak voor en tijdsplanning van een boosterdosis na dit vaccinatie-schema is niet vastgesteld. <sup>4</sup> Zie rubriek 5.1 van de volledige SPK. <sup>5</sup> Gegevens over volwassenen ouder dan 50 jaar ontbreken. **Wijze van toediening:** Het vaccin wordt toegediend via een diepe intramusculaire injectie, bij voorkeur in het anterolaterale gedeelte van de dij bij zuigelingen, of in de streek van de deltaspier van de bovenarm bij oudere personen. Als meer dan één vaccin tegelijk wordt toegediend, moeten afzonderlijke injectieplaatsen worden gebruikt. Het vaccin mag niet intraveneus, subcutaan of intradermaal worden toegediend, en mag niet worden gemengd met andere vaccins in dezelfde spuit. Voor instructies over het hanteren van het vaccin voorafgaand aan toediening, zie rubriek 6.6 van de volledige SPK. **Contra-indicaties:** Overgevoeligheid voor de werkzame stoffen) of voor een van de in rubriek 6.1 van de volledige SPK vermelde hulpstoffen). **Bijzondere waarschuwingen en voorzorgen bij gebruik:** Zoals dat voor alle vaccins geldt, dient ook toediening van Bexsero te worden uitgesteld bij personen die lijden aan een acute, ernstige, met koorts gepaard gaande ziekte. De aanwezigheid van een lichte infectie, zoals verkoudheid, mag echter niet uitstel van vaccinatie. Niet intravasculair injecteren. Zoals dat voor alle injecteerbare vaccins geldt, dienen passende medische behandeling en toezicht altijd direct beschikbaar te zijn voor het geval zich na toediening van het vaccin een anafylactische reactie voordoet. Reacties die verband houden met angst, waaronder vasovagale reacties (syncope), hyperventilatie of stressgerelateerde reacties, kunnen in relatie met vaccinatie voorkomen als psychogene reactie op de naaldinjectie (zie rubriek "Bijwerkingen"). Het is belangrijk dat er passende procedures zijn om letsel als gevolg van flauwvallen te voorkomen. Dit vaccin mag niet worden toegediend aan personen met trombocytopenie of een bloedstollingsstoornis die een contra-indicatie voor intramusculaire injectie vormt, tenzij het mogelijke voordeel duidelijk opweegt tegen het risico van toediening. Zoals dat voor alle vaccins geldt, beschermen vaccinatie met Bexsero mogelijk niet alle geïncubeerde. Bexsero wordt niet geacht bescherming te bieden tegen alle circulerende meningokokken B stammen (zie rubriek 5.1 van de volledige SPK). Zoals dat voor veel vaccins geldt, moet het medisch personeel zich ervan bewust zijn dat een temperatuursstijging kan optreden na vaccinatie van zuigelingen en kinderen (jonger dan 2 jaar). Prophylactische toediening van antipyretische medicatie dient te worden gestart volgens de lokale richtlijnen bij zuigelingen en kinderen (jonger dan 2 jaar). Personen met een immunodeficiënte, door het gebruik van immunosuppressieve therapie, een genetische stoornis, of door een andere oorzaak, kunnen een verlaagde antilichaamrespons hebben bij actieve immunisatie. Immunogeniteitsgegevens zijn beschikbaar van personen met complementdeficiëntie, asplenie of mildisfuncties (zie rubriek 5.1 van de volledige SPK). Personen met familiale complementdeficiënties (bijvoorbeeld C3- of C5-deficiënties) en personen die behandelingen ondergaan die de terminale complementactiviteit remmen (bijvoorbeeld eculizumab) hebben een hoger risico op een invasieve ziekte veroorzaakt door *Neisseria meningitidis* groep B, zelfs als deze personen antilichamen ontwikkelen na vaccinatie met Bexsero. Er zijn geen gegevens over het gebruik van Bexsero bij personen ouder dan 50 jaar en beperkte gegevens bij patiënten met chronische medische aandoeningen. Wanneer de primaire immunisatie op een zeer premature zuigelingen (geboren na < 28 weken zwangerschap) wordt toegediend, moet rekening worden gehouden met een potentieel risico op opneu en de noodzaak van controle van de ademhaling gedurende 4872 uur vooraf bij zuigelingen met een voorgeschiedenis van onvolgroeide longen. Aangezien het voordeel van vaccinatie groot is bij deze groep zuigelingen, moet vaccinatie niet worden onderhouden of uitgesteld. De dop van de injectiespuit bevat mogelijk natuurlijk rubber (latex). Hoewel het risico op het ontwikkelen van allergische reacties zeer klein is, moet het medisch personeel de voor en nadelen goed afwegen voordat dit vaccin wordt toegediend aan personen met een bekende voorgeschiedenis van overgevoeligheid voor latex. Kanamycine wordt aan het begin van het productieproces gebruikt en wordt in latere productiestadia verwijderd. Indien aanwezig, bedraagt het kanamy-

cine-niveau in het uiteindelijke vaccin minder dan 0,01 microgram per dosis. Veilig gebruik van Bexsero bij personen die gevoelig zijn voor kanamycine is niet vastgesteld. Dit middel bevat minder dan 1 mmol natrium (23 mg) per dosis, dat wil zeggen dat het in wezen natriumvrij is. **Terugvinden herkomst:** Om het terugvinden van de herkomst van biologische te verbeteren moeten de naam en het batchnummer van het toegeleide product goed geregistreerd worden. **Bijwerkingen: Overzicht van het veiligheidsprofiel:** De veiligheid van Bexsero is geëvalueerd in 17 onderzoeken, inclusief 10 gerandomiseerde gecontroleerde klinische studies met 10.565 proefpersonen (vanaf de leeftijd van 2 maanden) die minimaal één dosis Bexsero toegediend kregen. Van de personen die Bexsero toegediend kregen, waren 6.837 zuigelingen en kinderen (jonger dan 2 jaar), 1.051 kinderen (van 2 tot 10 jaar) en 2.677 adolescenten en volwassenen. Van de proefpersonen die de primaire immunisatie voor zuigelingen van Bexsero toegediend kregen, kregen 3.285 een boosterdosis in het tweede levensjaar. De meest voorkomende lokale en systemische bijwerkingen bij zuigelingen en kinderen (jonger dan 2 jaar) die in klinische studies zijn waargenomen, waren gevoeligheid en erythem op de injectieplaats, koorts en prikkelbaarheid. In klinische onderzoeken bij zuigelingen geïncubeerd op de leeftijd van 2, 4 en 6 maanden, is bij 69% tot 79% van de proefpersonen melding gemaakt van koorts (> 38°C) wanneer Bexsero gelijktijdig werd toegediend met standaardvaccins (die de volgende antigenen bevatten: 7valent meningokokkenconjugaat, difterie, tetanus, ocellulaire pertussis, hepatitis B, geïnactiveerde poliomylitis en *Haemophilus influenzae* type b) in vergelijking met 44% tot 59% van de proefpersonen die alleen de standaardvaccins kregen toegediend. Bij zuigelingen die Bexsero en standaardvaccins toegediend kregen, is ook vaker melding gemaakt van het gebruik van antipyretica. Wanneer alleen Bexsero werd toegediend, kwam koorts bij zuigelingen even vaak voor als bij standaardzuigelingenvaccins die tijdens klinische studies werden toegediend. Eventuele koorts volgde in het algemeen een voorspelbaar patroon, waarbij de meeste koortsepisoden op de dag na de vaccinatie over waren. De meest voorkomende lokale en systemische bijwerkingen waargenomen bij adolescenten en volwassenen waren pijn op de injectieplaats, malaise en hoofdpijn. Er is geen toename waargenomen in de incidentie of ernst van bijwerkingen bij opeenvolgende doses in de vaccinatie reeks. **Tabel met bijwerkingen:** Bijwerkingen (na primaire immunisatie of boosterdosis) die ten minste als mogelijk gerelateerd aan de vaccinatie kunnen worden beschouwd, zijn naar frequentie ingedeeld. **De frequentie is als volgt geclassificeerd:** Zeer vaak: (> 1/100, < 1/10) - Soms: (> 1/1.000, < 1/100) - Zelden: (> 1/10.000, < 1/1.000) - Zeer zelden: (< 1/10.000) - Niet bekend: (kan niet met de beschikbare gegevens niet worden bepaald). De bijwerkingen worden binnen elke frequentiegroep gerangschikt in aflopende volgorde van ernst. Naast de meldingen uit klinische onderzoeken, zijn ook de wereldwijd ontgang vrijgekomen meldingen over bijwerkingen van Bexsero sinds de introductie op de markt in de volgende lijst opgenomen. Aangezien deze bijwerkingen vrijwillig zijn gemeld door een populatie van onbekende omvang, is het niet altijd mogelijk om een betrouwbare schatting van de frequentie te geven en worden ze daarom hier vermeld met de frequentie Niet bekend. **Zuigelingen en kinderen (tot en met 10 jaar):** **Bloed- en lymfestelselaandoeningen:** Niet bekend: lymfadenopathie, immuunsysteemaandoeningen; Niet bekend: allergische reacties (waaronder anafylactische reacties). **Voedings- en stofwisselingsstoornissen:** Zeer vaak: eetstoornissen. **Zenuwstelselaandoeningen:** Zeer vaak: slaperigheid, ongewoon huilen, hoofdpijn. - Soms: insulinen (inclusief febrile insulinen) - Niet bekend: hypotoon-hyporesponsieve episode, meningale prikkeling (tekenen van meningale prikkeling zoals stijfheid van de nek of fotofobie zijn kort na de vaccinatie sporadisch gemeld. Deze symptomen waren mild en van voorbijgaande aard). **Bloedvataandoeningen:** Soms: bleekheid (zelden na booster) - Zelden: ziekte van Kawasaki. **Maagdarmselselaandoeningen:** Zeer vaak: diarree, braken (soms na booster). **Huid en onderhuidsaandoeningen:** Zeer vaak: huiduitslag (kinderen van 12 tot en met 23 maanden) (soms na booster) - Vaak: huiduitslag (zuigelingen en kinderen van 2 tot en met 10 jaar) - Soms: eczeem - Zelden: urticaria. **Skeletspierstelsel en bindweefselstoornissen:** Zeer vaak: artralgie. **Algemene aandoeningen en toedieningsplaatsstoornissen:** Zeer vaak: koorts (> 38°C), gevoeligheid op de injectieplaats (inclusief ernstige gevoeligheid op de injectieplaats, gedefinieerd als huilen wanneer de geïnjecteerde ledemaat wordt beweogen), erythem op de injectieplaats, zwelling op de injectieplaats, verharding op de injectieplaats, prikkelbaarheid - Soms: koorts (> 40°C) - Niet bekend: injectieplaatsreacties (inclusief uitgebreide zwelling van de geïncubeerde ledemaat, blaren op of rondom de injectieplaats en een nodus op de injectieplaats die meer dan een maand kan aanhouden). **Adolescenten (van 11 jaar en ouder) en volwassenen:** **Bloed- en lymfestelselaandoeningen:** Niet bekend: lymfadenopathie, immuunsysteemaandoeningen; Niet bekend: allergische reacties (waaronder anafylactische reacties). **Zenuwstelselaandoeningen:** Zeer vaak: hoofdpijn - Niet bekend: syncope of vasovagale reacties op een injectie, meningale prikkeling (tekenen van meningale prikkeling zoals stijfheid van de nek of fotofobie zijn kort na de vaccinatie sporadisch gemeld. Deze symptomen waren mild en van voorbijgaande aard). **Maagdarmselselaandoeningen:** Zeer vaak: misselijkheid. **Huid en onderhuidsaandoeningen:** Niet bekend: huiduitslag. **Skeletspierstelsel en bindweefselstoornissen:** Zeer vaak: myalgie. **Algemene aandoeningen en toedieningsplaatsstoornissen:** Zeer vaak: pijn op de injectieplaats (inclusief ernstige pijn op de injectieplaats, gedefinieerd als niet in staat normale dagelijkse activiteiten uit te voeren), zwelling op de injectieplaats, verharding op de injectieplaats, erythem op de injectieplaats, malaise - Niet bekend: koorts, injectieplaatsreacties (inclusief uitgebreide zwelling van de geïncubeerde ledemaat, blaren op of rondom de injectieplaats en een nodus op de injectieplaats die meer dan een maand kan aanhouden). **Melding van vermoedelijke bijwerkingen:** Het is belangrijk om na toelating van het geneesmiddel vermoedelijke bijwerkingen te melden. Op deze wijze kan de verhouding tussen voordelen en risico's van het geneesmiddel voortdurend worden gevolgd. Beroepsbeoefenaren in de gezondheidszorg wordt verzocht alle vermoedelijke bijwerkingen te melden via het nationale meldsysteem. **België:** Federaal Agentschap voor Geneesmiddelen en Gezondheidsproducten - Afdeling Vigilantie - Postbus 97 - B-1000 Brussel - Madou - Website: www.ebnijverheidsmelden.be - e-mail: odr@fagg.be. **Luxemburg:** Centre Régional de Pharmacovigilance de Nancy - Bâtiment de Biologie Moléculaire et de Biopathologie (BBB) - CHRU de Nancy - Hôpitaux de Brabois - Rue du Morvan - 54 511 Vandœuvre Les Nancy Cedex - Tél.: (+33) 3 83 65 60 85 / 87 - e-mail: crp@chru-nancy.fr ou Direction de la Santé - Division de la Pharmacie et des Médicaments - 20, rue de Bitbourg - L-1273 Luxembourg - Hamm - Tél.: (+352) 2478 5592 - e-mail: pharmacovigilance@ms.etat.lu - Link pour le formulaire: https://guichet.public.lu/fr/entreprises/sectoriel/sante/medecins/notification-ef-fets-indesirables-medicaments.html. **HOUDER VAN DE VERGUNNING VOOR HET IN DE HANDEL BRENGEN:** GSK Vaccines S.r.l. Via Fiorentina 1: 53100 Siena: Italië. **DATUM VAN DE GOEDKEURING VAN DE TEKST:** 25/02/2022 (v13). **AFLEVERINGSWIJZE:** Op medisch voorschrift. **Referentie:** SmPC Bexsero

VU: GlaxoSmithKline Pharmaceuticals s.a./n.v.  
Site Apollo Avenue Pascal, 2-4-6 1300 Wavre Belgium  
PM-BE-BEX-ADVT-210006 - Juli 2021



# Pulse oximetry to screen for critical congenital cardiopathy in neonates: current practices in Flanders

Ria Cornelissen<sup>a</sup>, Karel Allegaert<sup>b,c,d</sup>

<sup>a</sup> Department of Public Health and Primary Care, KU Leuven, Belgium

<sup>b</sup> Department of Development and Regeneration, and <sup>c</sup> Department of Pharmacy and Pharmaceutical Sciences, KU Leuven, Belgium

<sup>d</sup> Department of Hospital Pharmacy, Erasmus MC University Medical Center, Rotterdam, the Netherlands

karel.allegaert@uzleuven.be

## Keywords

newborn; critical congenital cardiopathy; pulse oximetry screening; implementation

## Abstract

Based on a survey on current practices using systematic pulse oximetry to screen for critical congenital cardiopathy in the 59 maternities in Flanders and a response rate of 91 % (54/59), we conclude that at least 48 units already have implemented systematic pulse oximetry screening. Before the Vlaamse Vereniging voor Kindergeneeskunde guideline ( $\leq 2015$ ), there were 2 maternity wards that already conducted pulse oximetry, with a steady annual increase (+4, +8, +13, +8, +11, +1) until 2021. Commonly reported barriers were limited resources (time, staff, equipment), the need of training initiatives, the presence of false-positives, the absence of echocardiographic expertise, or interference with earlier discharge.

## Introduction

Congenital cardiopathies are the most common group of congenital malformations, with a prevalence of 9.4/1000. About 15-25% of these cases are critical congenital heart diseases (CCHD), defined as a potential life-threatening duct-dependent heart lesion requiring an invasive procedure in first 28 days of life (15% -25 % of the CHD, about 17/10 000) (1). Pulse oximetry (PO) aims to identify CCHD cases as 'pre-collapse' detection is associated with improved outcome (1).

PO hereby adds to prenatal screening (ultrasound) and postnatal clinical examination. There is a progressive increase in prenatal ultrasound-based CCHD detection, but this remains below 50%, while the neonatal clinical examination also has limitations (sensitivity suggested to be 52%), so that PO is useful to close the diagnostic gap (2). However, these data are based on meta-analysis, and do not necessary reflect the setting in Flanders (prenatal screening, postnatal clinical examination).

Also when combined with neonatal clinical examination, there is an add on benefit in both sensitivity and specificity of PO. Based on a hypothetical population of 10 000 cases and 17 cases with CCHD, clinical examination itself will result in 109 positive results, of whom 9 will have a CCHD (and 8/17 cases will be missed, sensitivity 52%, specificity 98-99%). Adding PO to the screening procedure based on clinical examination will result in detection of 16/17 (+7) true cases, be it based on 216 (+107) positive results (sensitivity 92%, specificity 98%). An additional reflection on these 200 false positive cases is that 37-70% (mean 50%) of these cases have other issues, like persistent pulmonary hypertension, respiratory distress, sepsis, or non-critical congenital heart disease (3). An overview on sensitivity, specificity and false-positive ratio of PO for CCHD screening is provided in Table 1.

In the meanwhile and driven by these meta-analyses, advices, public consultations or guidelines on PO screening have been provided by different pediatric societies (US, UK, Canada), including the Vlaamse Vereniging voor Kindergeneeskunde (VVK) statement (2016) on PO as part of the short hospital stay approach (8). As this statement was published in 2016, we conducted a survey on the current practices and the perceived barriers on PO implementation in the 59 Flemish maternities 5 years after its release (8).

## Methods

Following ethical approval of the survey (MP017253, 19.01.2021) by KU Leuven, and with the logistic support of the VVK secretary in the GDPR setting (General Data Regulation Protection), an online questionnaire was repeatedly circulated (February-March 2021) to all heads of the relevant departments (pediatrics, neonatology). The questionnaire focused on current practices, the implementation pathway and perceived burdens on PO screening.

## Results

The response rate (54/59, 91%) was high. As 48/54 of the maternity wards have a systematic PO screening program, this means that at least 48/59 (81%) of the maternity wards have implemented systematic PO screening. Before the VVK guideline ( $\leq 2015$ ), there were 2 maternity wards that already conducted PO, with a steady annual increase (+4, +8, +13, +8, +11, +1, one unit has not reported on the year of implementation), until 2021. Other units only screen in the event of abnormal clinical findings ( $n=4$ ), and 2 of the responders do not have a PO strategy yet, while the majority of these maternities intend to implement systematic PO screening in the next year(s). Commonly reported barriers are limited resources (time, staff, equipment) in the absence of funding, the need for training initiatives, the presence of false-positives, the absence of echocardiographic expertise in the event of a positive screening, or interference with earlier discharge.

## Discussion

Within 5 years after the VVK guidance text on early discharge practices including PO screening was published, at least 81% of the maternity wards have developed, organized, and implemented a systematic PO screening program. There is a progressive annual increase, while the majority of units that do not yet provide this systematic PO screening have the intention to do this in the next year(s). When compared to other (European) countries, it seems that there is a trend to reach near universal screening, be it without structured efforts or imposed guidelines from authorities when compared to other regions (9). Barriers relate to 'logistics', as well as the false positive rate (table 1).

Related to this and as one of the limitations of our survey, we have not collected information on how (protocol) PO screening is conducted, and to what extent this is standardized within and between maternity wards. We further

**Table 1** : Sensitivity, specificity and false-positive ratio of pulse oximetry (PO) for critical congenital heart disease screening as reported in systematic reviews and meta-analyses (chronologically, CI = 95 % confidence interval) (4-7).

source	studies pooled	newborns (number)	sensitivity PO	specificity PO	false+ PO
Thangaratinam 2007 (4)	8	35.960	63,4% (CI: 25-98,5%)	99,8% (CI: 98-100%)	0,2% (0-2%)
Thangaratinam 2012 (5)	13	229.421	76,5% (CI: 67,7-83,5%)	99,9% (CI: 99,7-99,9%)	0,14% (0,06-0,33%)
Du 2017 (6)	22		69% (CI: 67-72%)	99% (CI: 99-99%)	
Plana 2018 (7)	19	436.758	76,3% (CI: 69,5-82%)	99,9% (CI: 99,7-99,9%)	0,14% (0,07-0,22%)

suggest to consider qualitative research in addition to the current quantitative research, with emphasis on the different health care providers involved (pediatricians, pediatric cardiologists, midwives). We are neither aware on the opinions of parents on this additional screening opportunity with a higher sensitivity, at the cost of an increase in false positives (be it that a relevant portion has another non-CCHD diagnosis). In our opinion, formal registration as valid screening technique within the existing framework of preventive medicine and screening practices, and subsequent reimbursement are needed to create a qualitative, sustainable setting.

#### Conflict of interest

The authors have no conflict of interest to declare.

#### Acknowledgements

We are grateful to the VVK for their secretarial support, and are even more grateful to all responders, as the value of a survey largely depends on the response rate. This paper is a summary of a master thesis youth health care, and this pdf document is available upon request to the corresponding author.

#### REFERENCES:

1. Ismail AQT, Cawsey M, Ewer AK. Newborn pulse oximetry screening in practice. *Arch Dis Child Educ Pract Ed.* 2017;102(3):155-61.
2. Aranguren Bello HC, Londoño Trujillo D, Troncoso Moreno GA, Dominguez Torres MT, Taborda Restrepo A, Fonseca A, et al. Oximetry and neonatal examination for the detection of critical congenital heart disease: a systematic review and meta-analysis. *F1000Res.* 2019;8:242.
3. Roberts TE, Barton PM, Auguste PE, Middleton LJ, Furmston AT, Ewer AK. Pulse oximetry as a screening test for congenital heart defects in newborn infants: a cost-effectiveness analysis. *Arch Dis Child.* 2012;97(3):221-6.
4. Thangaratinam S, Daniels J, Ewer AK, Zamora J, Khan KS. Accuracy of pulse oximetry in screening for congenital heart disease in asymptomatic newborns: a systematic review. *Arch Dis Child Fetal Neonatal Ed.* 2007;92(3):F176-80.
5. Thangaratinam S, Brown K, Zamora J, Khan KS, Ewer AK. Pulse oximetry screening for critical congenital heart defects in asymptomatic newborn babies: a systematic review and meta-analysis. *Lancet.* 2012;379(9835):2459-64.
6. Du C, Liu D, Liu G, Wang H. A meta-analysis about the screening role of pulse oximetry for congenital heart disease. *Biomed Res Int.* 2017;2017:2123918.
7. Plana MN, Zamora J, Suresh G, Fernandez-Pineda L, Thangaratinam S, Ewer AK. Pulse oximetry screening for critical congenital heart defects. *Cochrane Database Syst Rev.* 2018;3(3):CD011912.
8. Vlaamse Vereniging voor Kindergeneeskunde. Vroeg ontslag uit de materniteit [Internet]. Genk; 2015 [cited 2021 May 25]. Available from: [https://vvkkindergeneeskunde.be/userfiles/files/VROEG\\_ONTSLAG\\_UIT\\_DE\\_MATERNITEIT\\_07032016.pdf](https://vvkkindergeneeskunde.be/userfiles/files/VROEG_ONTSLAG_UIT_DE_MATERNITEIT_07032016.pdf).
9. Martin GR, Ewer AK, Gaviglio A, Hom LA, Saarinen A, Sontag M, et al. Updated strategies for pulse oximetry screening for critical congenital heart disease. *Pediatrics.* 2020;146(1):e20191650.

# ANTHELIOS DERMO-PEDIATRICS 50+

UNE GAMME COMPLÈTE POUR PROTÉGER  
LA PEAU DÉLICATE DES ENFANTS ET DES BÉBÉS

**PROTÉGEZ LEUR PEAU DÈS LEUR PLUS JEUNE ÂGE.**



## HAUTE EFFICACITÉ

- Protection solaire large spectre : anti-UVB et anti-UVA
- Photostabilité
- Très résistant à l'eau



## EXCELLENTE TOLÉRANCE

- Testée sous contrôle pédiatrique
- Enfants ayant une peau sensible et à tendance atopique



## TEXTURES ADAPTÉES

- Faciles à appliquer pour une protection uniforme
- Absorption rapide. Sans traces blanches.
- Ne pique pas les yeux

### NOUVEAU Eco-pack



#### LAIT PPD 38

30ml CNK: 3622-248  
100ml CNK: 2737-872  
250ml CNK: 3478-674



#### WET SKIN PPD 25

250ml CNK: 3478-690



#### SPRAY PPD 36

200ml CNK: 3969-185



#### AÉROSOL PPD 36

125ml CNK: 3969-193



#### BABY PPD 39

50ml CNK: 3173-143



# Postnatal cytomegalovirus infection in extremely preterm infants receiving raw mother's own milk: clinical course and neurodevelopment at two years

Hélène Dumonceau, Anne-Britt Johansson, Aline Vuckovic

aline.vuckovic@huderf.be

## Keywords

Human cytomegalovirus, Breast milk, Pasteurization, Extremely low birth weight infants, Neurological outcomes

## Abstract

**Objective.** To investigate neonatal manifestations and neurological outcomes after postnatal cytomegalovirus (CMV) infection in extremely preterm infants receiving raw mother's own milk.

**Methods.** This was a retrospective analysis of 45 lactating mothers and their 53 infants born  $\leq 28$  weeks gestational age. Maternal serologies and screening for CMV in infants were obtained. CMV-positive and CMV-negative groups were compared regarding clinical course, raw mother's own milk intake, as well as growth, neurological, and hearing outcomes until 24 months corrected age.

**Results.** Maternal seroprevalence was 90%. CMV viraemia occurred at a median age of 33.4 weeks in 10 infants, all born to CMV-seropositive mothers. CMV-positive infants were more exposed to daily raw mother's own milk (70% vs. 28%;  $P = .02$ ). Five infants with a history of prolonged ventilation and systemic corticosteroids increased their ventilator needs concurrently with CMV infection. The rates of bronchopulmonary dysplasia, necrotizing enterocolitis and retinopathy were similar in both groups. There was no fatal outcome among CMV-positive infants. However, hospital stay was prolonged by 26 days on average ( $P = .02$ ). At 24 months, 7 CMV-positive infants and 22 CMV-negative infants scored similarly on Bayley-III scales. Sensorineural hearing loss was not detected after CMV infection.

**Interpretation.** Postnatal CMV infection in extremely preterm infants had no impact on hearing and neurodevelopment within the first 2 years of life. However, postnatal CMV infection might worsen respiratory status and increase length of hospital stay.

## Introduction

Mother's own milk (MOM) is encouraged in preterm infants since its immunomodulating and nutritional properties combine to decrease inflammation, thereby attenuating the risk of bronchopulmonary dysplasia, retinopathy of prematurity, and necrotizing enterocolitis (1). Breast milk is also beneficial in long-term health and psychomotor development (1).

Various pathogens can be transmitted through breast milk, including cytomegalovirus (CMV) (1,2). In industrialized countries, CMV seroprevalence varies between 50 and 90% in pregnant women (2). During lactation, most seropositive mothers experience viral reactivation in the mammary glands, which begins around day 3 postpartum and peaks for 4–8 weeks (2,3). Once infected, full-term newborns usually remain asymptomatic, likely due to the complete transplacental transfer of maternal anti-CMV antibodies. By contrast, CMV transmission can reach 20–35% in preterm infants receiving raw MOM (4,5). Approximately 20% of very low birth weight (VLBW;  $< 1500$  g) infants will develop self-limited illness ranging from abnormal laboratory findings to clinical deterioration mimicking sepsis (4,5). Despite high transmission and infection rates, deaths have rarely been reported (4). These reassuring outcomes were recently challenged by observations in extremely preterm ( $\leq 28$  weeks gestational age) and/or extremely low birth weight (ELBW;  $< 1000$  g) infants (4,5). In this category, postnatal CMV infection was more frequent and more often associated with severe acute disease (6). Increased risks of bronchopulmonary dysplasia and retinopathy of prematurity were also reported (7–9). By contrast with the well-known neurodevelopmental sequelae of congenital CMV infection, conflicting long-term outcomes are reported after postnatal CMV infection in VLBW infants (10–12). While neurological outcomes and sensorineural hearing seem preserved in toddlers and preschool children (11–13), older children can possibly display subtle alterations of cognitive performances (10,14,15).

Strategies of CMV inactivation in MOM, such as freezing and pasteurization, are used to limit transmission at the price of detrimental effects on the nutritional and immunological quality of milk (16). In 2012, considering contemporary evidence, the American Academy of Pediatrics recommended promotion of raw MOM in all preterm infants (1). However, the possibility of severe illness and emerging uncertainties regarding long-term outcomes have led some scientific committees to argue against the administration of raw MOM to the most immuno-incompetent infants (2,16,17). In 2016, the Belgian Superior Health Council recommended systematic pasteurization of MOM expressed from CMV-seropositive mothers until 32 weeks postmenstrual age for infants born  $\leq 28$  weeks gestational age and/or with an ELBW (18). Whether this recommendation might be excessive remains questionable when balancing the risks of postnatal CMV infection with the benefits of raw MOM.

Therefore, this retrospective study conducted in a Belgian neonatal intensive care unit (NICU) before the implementation of the national guidelines recapitulates the evolution of a previous cohort of extremely preterm infants, regularly receiving raw MOM from their CMV-seropositive mothers, and screened for CMV infection. The first aim was to describe the characteristics of postnatal CMV infection in this vulnerable cohort. Because follow-up data are scarce in ELBW infants, the second aim was to compare neonatal comorbidities and neurodevelopmental outcomes until 24 months corrected age in infected and non-infected infants.

## Materials and methods

### Study population

This was a retrospective study including all infants born  $\leq 28$  weeks gestational age and admitted to the NICU of Queen Fabiola Children's University Hospital (Brussels, Belgium) between June 1, 2014 and December 31, 2018.

Exclusion criteria were death before screening for CMV, congenital CMV (defined as a positive culture in urine within the first 3 weeks of life), incomplete data due to transfer to another hospital, major congenital anomaly, exclusive formula milk, and unknown maternal CMV status. Medical records were reviewed by 2 investigators (H.D. and A.V.). The Institutional Review Board approved the study protocol (No. 19/19). The need for parental informed consent was waived due to retrospectively collected data. Anonymity was preserved.

#### *Local particularities regarding mother's own milk handling*

Due to local organization and adaptation of infrastructures in our milk bank, the Belgian 2016 recommendations were implemented in January 2019. Before this date and during the study period, raw MOM expressed in the NICU was directly administered within the first hour of expression or transported to the milk bank where bacteriological cultures were performed. In the case of a negative culture, raw MOM was stored at 4°C for a maximum of 4 days before being frozen at -18°C. Holder pasteurization was applied (i.e., 62.5°C for 30 minutes then back under 10°C within less than 2 hours) if MOM cultures showed > 10<sup>6</sup> CFU/mL for saprophytic strains including coagulase-negative staphylococci, and/or < 10<sup>4</sup> CFU/mL for pathogenic bacteria including *Staphylococcus aureus*, *Streptococcus agalactiae*, *Streptococcus pneumoniae*, and the *Enterobacteriaceae* family. MOM was discarded in any case of *Bacillus sp* and/or if > 10<sup>4</sup> CFU/mL for pathogenic bacteria. MOM expressed outside the NICU was transported to the milk bank for pasteurization.

After birth, raw colostrum was administered for 3 days. In addition to parental nutrition, enteral feeds increased by 20 mL/kg/day according to tolerance. When reaching 60 mL/kg/day of feeding volume, MOM was enriched with multicomponent fortifier (PreNAN human milk fortifier, Nestlé, Vevey, Switzerland). Fortification was not individualized given the unavailability of a bedside infrared analyzer. Parental nutrition was stopped when enteral feeding volumes reached 120 mL/kg/day. Volumes of fortified MOM were then increased to 160–180 mL/kg/day. In the case of insufficient MOM, pasteurized donor milk was offered as the best alternative. Otherwise, preterm formula milk (PreNAN, Nestlé) was administered.

#### *Data collection*

Demographics and perinatal characteristics were collected, such as gestational age and anthropometric data at birth, cause of prematurity, antenatal steroids, type of delivery, 5-minute Apgar score, Clinical Risk Index for Babies, and maternal sociodemographic data. CMV surveillance included maternal serology obtained during the last trimester of pregnancy or immediately after delivery, screening in urine scheduled on a weekly basis, and age at positive screening. Postnatal CMV infection was defined as detection of viraemia after 21 days of life with a previous negative culture. The onset of viraemia was calculated as the date at mid-point between the last negative and the first positive viral culture. Clinical and laboratory findings were retrieved in a 7-day period before and after identified CMV viraemia.

Regarding feeding practice, the type of milk at discharge was recorded. The number of feeds containing raw MOM was counted for each day between day 3 of life and 32 weeks postmenstrual age. These data were used to calculate the proportion of days where infants were fed raw MOM at least once a day and the proportion of days where infants were exclusively fed raw MOM.

Characteristics of postnatal management were obtained throughout the NICU stay, including duration of invasive ventilation, systemic corticosteroid use, and administration of leukoreduced blood components. Comorbidities were retrieved, such as death before 36 weeks postmenstrual age, bronchopulmonary dysplasia defined as ventilatory and/or oxygen needs at 36 weeks postmenstrual age, retinopathy of prematurity<sup>3</sup> stage 3, necrotizing enterocolitis<sup>3</sup> stage 2 according to Bell criteria, intraventricular hemorrhage<sup>3</sup> grade 3 according to the Papile classification, periventricular leukomalacia, and proven late-onset sepsis. Variables were obtained at discharge, including length of stay, anthropometric data, brain imaging, auditory evoked potentials, fundus examination, and electroencephalogram.

At 12 months and 24 months corrected age, infants were classified as having normal or abnormal neurological findings. The level of disability in children with cerebral palsy was based on the Gross Motor Function Classification

System. Beside anthropometric data, cognitive, language and motor functions were evaluated with the Bayley Scales of Infant and Toddler Development—Third edition by the same pediatrician responsible for the follow-up of preterm infants. Infants were screened for auditory and visual impairment at least once during the first 24 months of life. Hearing was investigated by wideband tympanometry and auditory evoked potentials. Sensorineural hearing loss was defined as a threshold > 20 dB (19).

#### *Statistical analyses*

Data were expressed as numbers and percentage or median and interquartile range (IQR). Two-group comparisons were performed between CMV-positive and CMV-negative groups, and between asymptomatic and symptomatic infants in the CMV-positive group. Because most data were not normally distributed, the Mann-Whitney U test was used to compare continuous variables between the two groups. Fisher's exact test was applied to categorical variables. Statistical analyses were performed using GraphPad Prism 8.0 (GraphPad Software, San Diego, CA). Significance of two-tailed tests was considered at  $P < .05$ .

## **Results**

### *Study population*

Seventy-five infants born to 63 mothers were initially considered (Figure 1). Twenty-two infants were excluded because of death or transfer before 21 days of life with unknown CMV status ( $n = 13$ ), incomplete data ( $n = 5$ ), major congenital anomaly ( $n = 1$ ), or no breastfeeding ( $n = 3$ ). Among the 53 included infants born to 45 mothers, 10 (19%) were diagnosed with CMV viraemia (CMV-positive group), while 43 infants remained negative (CMV-negative group). Both groups displayed comparable perinatal and demographic characteristics (Table 1). All CMV-positive infants were singletons. After discharge, 7 CMV-positive infants and 22 CMV-negative infants completed their follow-up until 24 months corrected age (Figure 1). One infant with postnatal CMV infection was only evaluated at 24 months corrected age.

### *Screening for CMV and characteristics of postnatal infection*

Maternal seroprevalence was 91% ( $n = 41/45$ ). The screening for CMV viraemia started at a median of 7 days (IQR 3.7–7.2) in the CMV-positive group and was performed 6 times (IQR 4–8) during the NICU stay. In the CMV-negative group, the first analysis was obtained at 8 days (IQR 4–13;  $P = .17$ ) and a median number of 5 analyses (IQR 4–7) were done ( $P = .35$ ). No infant was diagnosed with congenital CMV infection. The 5 infants born to 4 CMV-seronegative mothers did not acquire CMV infection.

In the CMV-positive group, viraemia was detected at 8 weeks (IQR 6.4–8.4) after birth, which corresponded to 34.5 weeks postmenstrual age (IQR 32–35.3). Based on the date of the last negative culture, the onset of CMV viraemia was estimated at 33.4 weeks postmenstrual age (IQR 32.3–35). There was no positive screening before 31 weeks postmenstrual age. Five infants developed mild signs of illness such as fever and/or increased ventilator or oxygen needs, corresponding to an incidence of 12% of symptomatic ELBW infants born to CMV-seropositive mothers. Endotracheal intubation was not required. There was no severe acute illness or death. Thrombocytopenia (minimum 80,000/mm<sup>3</sup>) and neutropenia (minimum 400/mm<sup>3</sup>) occurred in one and 3 infants respectively. Liver enzymes remained within the normal range, with a median value for GOT of 25 IU/L (IQR 21–31) and a median value for GPT of 11 IU/L (IQR 9–13). The level of C-reactive protein was reported in 3 febrile infants and was < 20 mg/L. No antiviral therapy was administered because CMV-positive infants were either mildly affected or not symptomatic.

### *Breastfeeding practice*

Between day 3 and day 15 of life all CMV-positive infants received raw MOM every day, whereas 56% of CMV-negative infants were daily fed raw MOM (Table 2). The proportion of days where infants received raw MOM at least once a day was also higher in the CMV-positive group (Table 2). Likewise, the proportion of days where raw MOM was the only type of feeding given tended to be twofold higher in CMV-positive infants (69% vs. 37%;  $P = .054$ ). The rate of exclusive breastfeeding decreased over time, resulting in 30% of infants from both groups exclusively fed breast milk at discharge (Table 2).

### *Neonatal comorbidities*

Figure 1 : Study flow diagram. GA, gestational age; CA, corrected age.

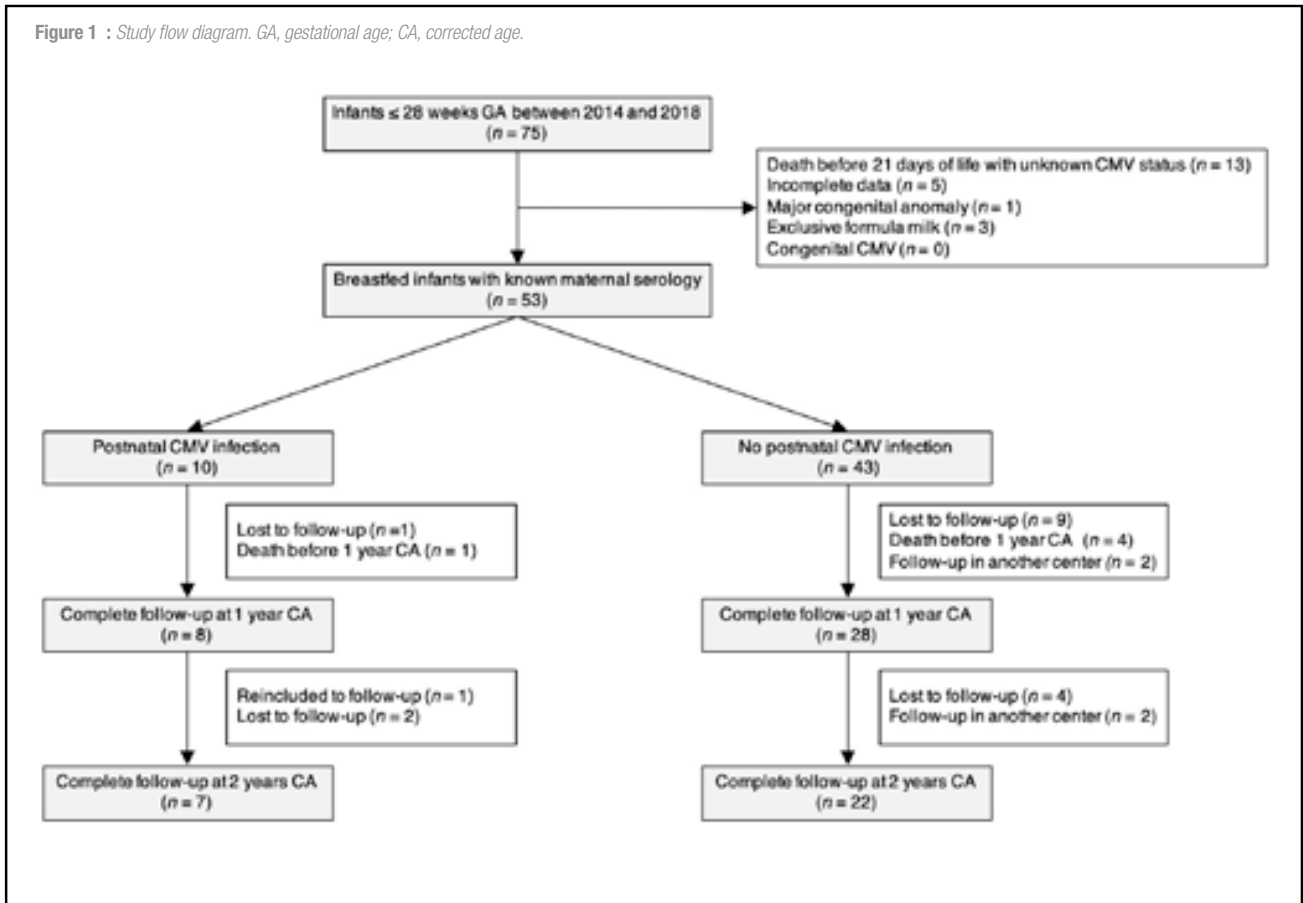


Table 1. : Demographic and perinatal characteristics of extremely preterm infants according to the diagnosis of postnatal CMV infection

	CMV-positive (n = 10)	CMV-negative (n = 43)	P value
<b>Maternal variables</b>			
CMV seropositivity, n (%)	10 (100)	38 (88)	.57
Age, years, median (IQR)	28.1 (24–33.3)	29.5 (24.3–32.3)	.82
Education < high school, n (%)	2 (20)	8 (19)	.99
Singleton, n (%)	10 (100)	24 (56)	.009
Chorioamnionitis, n (%)	1 (10)	5 (12)	.99
Pre-eclampsia, n (%)	3 (30)	4 (9)	.11
Placenta abruption/previa, n (%)	0	4 (9)	.99
Antenatal steroids, n (%)	9 (90)	41 (95)	.47
Cesarean section, n (%)	6 (60)	31 (72)	.47
Outborn delivery, n (%)	0	3 (7)	.99
<b>Infant variables</b>			
Male gender, n (%)	5 (50)	24 (56)	.99
Gestational age (weeks), median (IQR)	26.7 (25.8–27.2)	27 (26.1–27.7)	.18
Birth weight (g), median (IQR)	765 (695–1008)	885 (770–1075)	.25
Small for gestational age, n (%)	0	3 (7)	.99
Microcephaly, n (%)	0	2 (5)	.99
5-min Apgar score, median (IQR)	9 (6.8–9)	8 (7–9)	.29
CRIB, median (IQR)	4.5 (1.8–7.3)	3 (1–6.3)	.53

CRIB, Clinical Risk Index for Babies; IQR, interquartile range. Chorioamnionitis was diagnosed based on histology and/or microbiology. Small for gestational age and microcephaly were defined respectively as birth weight and head circumference Z-scores < -1.29 based on the 2013 Fenton growth charts.

**Table 2. :** Feeding practices in extremely preterm infants according to the diagnosis of postnatal CMV infection

	CMV-positive (n = 10)	CMV-negative (n = 43)	P value
Parenteral nutrition (full or partial), days, median (IQR)	10.5 (9–15.3)	11 (10–18)	.74
Infants receiving daily raw MOM			
From day 3 to 15, n (%)	10 (100)	24 (56)	.009
From day 16 to 32 weeks postmenstrual age, n (%)	7 (70)	12 (28)	.024
% of days with raw MOM intake			
At least for one feed per day, median (IQR)	100 (91–100)	74 (59–100)	.014
For all feeds per day, median (IQR)	69 (49–80)	37 (21–73)	.054
Feeding at discharge*			.17
Exclusive breastfeeding, n (%)	3 (30)	12 (28)	
Mixed feeding, n (%)	4 (40)	6 (14)	
Formula milk, n (%)	3 (30)	22 (51)	

IQR, interquartile range; MOM, mother's own milk. \*Including 40 infants alive at discharge in the CMV-negative group.

**Table3. :** Neonatal outcomes of extremely preterm infants according to the diagnosis of postnatal CMV infection

	CMV-positive (n = 10)	CMV-negative (n = 43)	P value
<b>Outcomes before discharge</b>			
Invasive ventilation, n (%)	9 (90)	34 (79)	.66
Invasive ventilation, days, median (IQR)	10 (1–23.5)	4 (1–16.5)	.49
Systemic corticosteroids, n (%)	6 (60)	12 (28)	.07
Leukoreduced blood transfusions, n (%)			.74
1 transfusion	4 (40)	11 (25.6)	
2 transfusions	2 (20)	11 (25.6)	
≥ 3 transfusions	2 (20)	11 (25.6)	
Day of life at the first blood transfusion, median (IQR)	19 (15–45)	19 (10.3–24.5)	.38
Late-onset proven sepsis, n (%)	2 (20)	9 (21)	.99
Necrotizing enterocolitis ≥ grade 2, n (%)	0	3 (7)	.99
Moderate to severe BPD, n (%)*	6 (60)	20 (50)	.72
Intraventricular hemorrhage ≥ grade 3, n (%)	0	2 (4.7)	.99
Periventricular leukomalacia, n (%)	0	3 (7)	.99
Any retinopathy, n (%)	3 (30)	6 (14)	.34
Retinopathy ≥ grade 3, n (%)	0	2 (5)	.99
Death before 36 weeks postmenstrual age, n (%)	0	3 (7)	.99
<b>Outcomes at discharge*</b>			
Length of stay, days, median (IQR)	108 (83–146)	82 (67–100)	.02
Postmenstrual age, median (IQR)	41.4 (38.5–46.6)	37.7 (37–40.9)	.02
Weight, g, median (IQR)	2815 (2520–4560)	2720 (2383–3000)	.31
Head circumference, cm, median (IQR)	34.4 (33.2–37.6)	33.5 (32–35)	.08
Abnormal brain imaging, n (%)	2 (20)	17 (42)	.28
Abnormal EEG, n (%)	2 (20)	3 (7)	.26
Abnormal auditory evoked potentials			.31
Abnormal transmission, n (%)	1 (10)	3 (7)	
Cochlear impairment, n (%)	0	1 (2)	
Abnormal central conduction, n (%)	2 (20)	8 (20)	

EEG, electroencephalogram; IQR, interquartile range. Abnormal brain imaging included persistent periventricular echogenicity, subependymal hemorrhage, ventriculomegaly, and focal parenchymal lesions. \*Including 40 infants alive at discharge in the CMV-negative group.

CMV-positive and CMV-negative infants were similarly treated in terms of mechanical ventilation and patent ductus arteriosus management (Table 3). The rate of leukoreduced blood cell transfusions and the timing of the first transfusion were superimposable in both groups (Table 3). Systemic corticosteroids were used twice as often in CMV-positive infants, but this trend failed to reach statistical significance (Table 3). Three CMV-negative infants died before 36 weeks postmenstrual age of bacterial sepsis ( $n = 2$ ) and complications of intraventricular hemorrhage ( $n = 1$ ). At discharge, there were no differences in the rate of retinopathy of prematurity, bronchopulmonary dysplasia, and necrotizing enterocolitis (Table 3). Especially, none of the CMV-infected infant was diagnosed with severe retinopathy requiring treatment or proven necrotizing enterocolitis. Besides, CMV-positive and CMV-negative infants had comparable growth, brain imaging, electroencephalogram, and auditory evoked potentials (Table 3). However, the length of NICU stay was higher in CMV-positive infants, resulting in an increased postmenstrual age at discharge (Table 3).

Subgroup analyses within the CMV-positive group were performed to understand this finding better (Table 4). As compared to asymptomatic infants who remained clinically stable, those who experienced clinical deterioration during CMV infection had a history of prolonged invasive ventilation requiring systemic corticosteroids. All of them were diagnosed with moderate or severe bronchopulmonary dysplasia and stayed longer in the NICU. Symptomatic and asymptomatic infants exhibited similar gestational age, birth weight, timing of viruria, and growth characteristics at discharge (Table 4).

#### *Long-term neurodevelopment*

At 12 months and 24 months corrected age, growth pattern, neurological examination, and Bayley-III scores were similar in CMV-positive and CMV-negative groups (Table 5). In the CMV-negative group, hearing was not evaluated in 6 infants. In the remaining infants, one was diagnosed with sensorineural hearing loss, and 2 were diagnosed with conductive hearing loss. Eight CMV-positive infants were evaluated at least once until 24 months corrected age. No sensorineural hearing loss was detected, and transmission was impaired in 3 infants. Overall, hearing tests did not differ between the groups ( $P = .39$ ; Fisher's exact test). Severe bilateral visual deficit was diagnosed in one CMV-negative infant, while CMV-positive infants did not show any deficit ( $P = .99$ ; Fisher's exact test). Finally, albeit the very small sample size precludes from any robust conclusion, growth and neurodevelopmental outcomes at 12 months and 24 months corrected age appeared similar in infants with symptomatic and asymptomatic postnatal CMV infection (Table 6).

## **Discussion**

In this 4-year retrospective study focusing on extremely preterm infants mostly fed raw MOM during the first weeks of life and regularly screened for CMV, postnatal CMV viruria occurred in one-fifth of cases after 32 weeks postmenstrual age. Although infected and non-infected infants shared analogous outcomes, postnatal CMV infection was associated with a prolonged NICU stay without altering growth, hearing, or neurodevelopment until 24 months corrected age. These observations are consistent with the idea that most preterm infants born to CMV-seropositive mothers could benefit from raw MOM without devastating health consequences. However, these data should be cautiously interpreted given the limited size of the cohort.

Our findings are relevant for populations with high maternal CMV seroprevalence, which typically present CMV reactivation during lactation (3). In the case of extreme prematurity, recent guidelines recommend systematic pasteurization until 32 weeks postmenstrual age for MOM expressed from CMV-seropositive mothers (16,18). This would imply the pasteurization of MOM expressed from the majority of mothers, with subsequent higher workload, organizational constraints, and costs (20). In a recent French audit, only one-fourth of neonatal units complied with the French recommendations of systematic pasteurization of MOM in VLBW infants born to CMV-seropositive mothers, which indirectly suggests difficult implementation in clinical practice (17). In Belgium, there are no official reports regarding adherence to such recommendations. One could speculate that implementation would be difficult as most Belgian NICUs do not have access to a milk bank or pasteurization (21).

In Belgium, screening for CMV antibodies throughout pregnancy is no longer recommended, considering that congenital CMV can occur after reactivation in previously CMV-seropositive women (22). This was one of the rationales for incorporating CMV screening in all preterm infants and their mothers as part of the routine monitoring in our NICU. The median onset of CMV viruria was estimated at 8 weeks of life, which was consistent with previous reports in VLBW and ELBW infants (3,5,6). Viral load in MOM, a critical factor for CMV transmission, could not be evaluated in this study and, therefore, the correlation between viro lactia and infant virologic data could not be established (3). Yet, MOM as the main source of transmission was reasonably supported by the higher proportion of raw MOM feeds received in infected infants during their first weeks of life. Besides, the systematic use of leukoreduced blood transfusions likely decreased the transmission of CMV in the present cohort, as previously reported (23). High rates of leukofiltered blood cell transfusions were similarly found in CMV-positive and CMV-negative groups, making transfusions play a minimal role in the acquisition of CMV infection. Finally, the contribution of maternal cervical secretions to postnatal CMV infection was limited by a high rate of cesarean section in this study.

Despite high reactivation rates in MOM, not all extremely preterm infants acquire CMV infection. First, the presence of lactoferrin and anti-CMV IgG might provide raw MOM with some antiviral properties, at least experimentally (2). Second, MOM handling and storage can affect CMV activity and influence the rate of postnatal transmission (2). Herein, raw MOM was predominantly administered to CMV-positive infants during the first weeks postpartum, possibly explaining the higher rate of infection than in ELBW infants mainly receiving frozen MOM (24). Third, the risk of symptomatic infection is related to the infant's immaturity, as denoted by the association with lower birth weight and earlier age at viral detection (6). In the present cohort, postnatal CMV infection was diagnosed in about 20% of extremely preterm infants. This was in line with studies including ELBW infants, but still lower than in infants born at the limit of viability (4,6).

Half of postnatal CMV infections presented as self-limited illness, while hematologic disturbances remained asymptomatic. Antiviral therapies by ganciclovir or valganciclovir have been suggested for symptomatic congenital CMV infection to improve long-term neurodevelopmental outcomes. However, such treatments were not considered in the present study given the absence of severe symptoms in our cohort, potential immunological and liver toxicity of (val) ganciclovir, as well as the absence of prospective clinical trials supporting a use for symptomatic postnatal CMV infection acquired via MOM (2). As CMV copy count in blood and evolution of laboratory tests were not monitored, our data remained inconclusive regarding the timing of recovery and possibility of long-lasting disease (6). In accordance with previous reports, postnatal CMV infection did not affect the overall rate of death, bronchopulmonary dysplasia, necrotizing enterocolitis or retinopathy of prematurity (9,11,12). The increased length of stay could suggest that CMV infection, even if mildly symptomatic, augments the need for additional support and prolongs the length of stay (8,24). Of note, among CMV-positive infants, those who exhibited respiratory deterioration concurrent with CMV infection were more often diagnosed with bronchopulmonary dysplasia than asymptomatic ones. To date, studies exploring the association between postnatal CMV infection and bronchopulmonary dysplasia have yielded controversial results (7,11,25). A toxic effect on immature lungs was hypothesized, but the causality between CMV and bronchopulmonary dysplasia was not demonstrated (26). Consistent with the timing of CMV infection in this cohort, infants eventually diagnosed with bronchopulmonary dysplasia carried a pre-existing respiratory vulnerability, which was further destabilized by the viral episode. Based on this rationale, postnatal CMV infection could be an aggravating factor of ongoing bronchopulmonary dysplasia, retinopathy of prematurity or intestinal inflammation, depending on individual frailty. Compatible with the protective role of MOM, necrotizing enterocolitis and retinopathy of prematurity were rare outcomes in the present cohort of breastfed infants. The sample size of this study was thus too small to highlight differences after CMV infection.

The debate on whether postnatal CMV infection has an adverse effect on neurodevelopment is ongoing. Several studies do not support a role for postnatal CMV infection in neurodevelopmental delay during the first 2 to 4 years of life (5,11,27). In line with the most recent and large prospective study, our

study corroborated these findings, whether or not the patients were symptomatic, and at least until 24 months corrected age (13). Likewise, a systematic review compiling hearing outcomes in more than 1500 individuals failed to show any association between postnatal CMV infection and sensorineural hearing loss (28). This contrasted with a large retrospective study showing higher rates of failed hearing screen in CMV-positive infants (8). Yet, a failed hearing screen is frequent during the neonatal period and is not necessarily indicative of sensorineural etiology (19). Moreover, cases of congenital CMV could not be formally excluded in this study (8). Finally, discrete changes in complex cognitive functions after acquired CMV infection, still scoring within normal ranges, have been identified in 6 year-old children and adolescents (10,14,15). This must draw attention to the pursuit of long-term vigilance.

Because of the aforementioned controversies in extremely preterm infants fed raw MOM, recommendations regarding MOM handling to prevent CMV transmission vary between countries, depending on whether health authorities choose to favor the precautionary or the proportionality principle (17,18,20). Holder pasteurization suppresses the risk of CMV transmission but affects nutritional and immunological properties of MOM, including decreased concentration of bile salt-stimulated lipase activity, lactoferrin, immunoglobulins, growth factors, interleukins, and cellular components (16). It is still unclear whether pasteurization might be deleterious for postnatal growth or increase the risk of late-onset sepsis or necrotizing enterocolitis (29,30). By contrast, short-term freezing preserves the main properties of breast milk, but does not suppress the risk of CMV transmission (2). Furthermore, high-temperature short-term pasteurization has been alternatively developed to decrease the impact of MOM handling on its quality (2,20). A recent prospective cohort study showed a 10-fold reduction in the proportion of postnatal CMV infection (31). Although effective, this technique requiring time, training and specific medical device is not yet used in most NICUs (20). Therefore, instead of a generalized and strict recommendations difficult to implement in most NICUs, encouraging raw MOM in all extremely preterm infants and promoting early sucking during skin-to-skin holding at any age could be an acceptable option after informed consent regarding milk treatment.

Apart from the limitations stated above, we acknowledge that the retrospective design, small sample size and high dropout rates in our study were major shortcomings. Retrospective analysis may have an impact on the quality of retrieved data. However, the follow-up of extremely preterm infants during and after the NICU stay was prospectively collected in our institution, which likely limited such bias. The small sample size was inherent to the co-existence of 19 official NICUs in Belgium sharing the management of a limited number of ELBW infants annually. We can speculate that missed appointments in the SARS-CoV-2 pandemic context could explain unavailable data at 24 months corrected age for infants born in 2018. Finally, as this retrospective study focused on a recent cohort, follow-up data are limited to the first 24 months of life. Given uncertainties regarding long-term outcomes, cognitive performances should be monitored in older children with a previous CMV infection. Nevertheless, the strengths of our study include the homogeneity of the cohort and the screening for CMV available throughout hospital stay. This led to better characterization of phenotypes and related outcomes after postnatal CMV infection in the most fragile infants. This distinguishes our study from larger cohorts that focused on symptomatic infants and mixed those with negative CMV testing and those without any testing (and possibly asymptomatic) in the same control group (7,8,11). Interpretation of such studies can be difficult as misclassification of infants could not be ruled out.

## Conclusion

In the absence of registries reporting postnatal CMV screening and long-term outcomes of CMV infection as part of the prospective surveillance of VLBW infants, recommendations for the use of raw MOM are heterogeneous in preterm infants born to CMV-seropositive mothers. Even in the case of persistent divisions about long-term risks, the evolution of extremely preterm infants after postnatal CMV infection seems globally reassuring. Therefore, reconsideration of the current Belgian guidelines and uniformization between countries regarding MOM handling could be envisaged to allow most preterm infants to benefit from raw MOM. Nevertheless, our study suggested an association between postnatal CMV infection, prolonged NICU stay, and mild

worsening of the respiratory status in ELBW infants eventually diagnosed with bronchopulmonary dysplasia. These findings raised the unresolved question of restricting MOM pasteurization in the few ELBW infants with pre-existing susceptibilities prone to deteriorate after CMV infection. Due to the timing of CMV viraemia in ELBW infants, the question whether the critical period during which pasteurization should be extended in these particularly vulnerable infants remains open.

## Acknowledgements

The authors would like to thank Camille Brans and Marjorie Debande from the Department of Dietetics at Queen Fabiola Children's University Hospital for their support in providing protocols for milk handling.

## Conflict of interest

The authors have no conflict of interest to disclose.

## REFERENCES:

1. Johnston M, Landers S, Noble L, Szucs KV, L. Breastfeeding and the use of human milk. *Pediatrics*. 2012;129(3):e827-e841.
2. Osterholm EA, Schleiss MR. Impact of breast milk-acquired cytomegalovirus infection in premature infants: Pathogenesis, prevention, and clinical consequences. *Rev Med Virol*. 2020;30(6):1-11.
3. Hamprecht K, Maschmann J, Vochem M, Dietz K, Speer CP, Jahn G. Epidemiology of transmission of cytomegalovirus from mother to preterm infant by breastfeeding. *Lancet*. 2001;357(9255):513-518.
4. Lanzieri TM, Dollard SC, Josephson CD, Schmid DS, Bialek SR. Breast milk-acquired cytomegalovirus infection and disease in VLBW and premature infants. *Pediatrics*. 2013;131(6):e1937-e1945.
5. Capretti MG, Lanari M, Lazzarotto T, Gabrielli L, Pignatelli S, Corvaglia L et al. Very low birth weight infants born to cytomegalovirus-seropositive mothers fed with their mother's milk: a prospective study. *J Pediatr*. 2009;154(6):842-848.
6. Mehler K, Oberthuer A, Lang-Roth R, Kribs A. High rate of symptomatic cytomegalovirus infection in extremely low gestational age preterm infants of 22-24 weeks' gestation after transmission via breast milk. *Neonatology*. 2014;105(1):27-32.
7. Kelly MS, Benjamin DK, Puopolo KM, Laughon MM, Clark RH, Mukhopadhyay S et al. Postnatal Cytomegalovirus Infection and the Risk for Bronchopulmonary Dysplasia. *JAMA Pediatr*. 2015;169(12):e153785.
8. Weimer KED, Kelly MS, Permar SR, Clark RH, Greenberg RG. Association of Adverse Hearing, Growth, and Discharge Age Outcomes With Postnatal Cytomegalovirus Infection in Infants With Very Low Birth Weight. *JAMA Pediatr*. 2020;174(2):133-140.
9. Martins-Celini FP, Yamamoto AY, Passos DM, do Nascimento SD, Lima EV, Di Giovanni CM et al. Incidence, Risk Factors, and Morbidity of Acquired Postnatal Cytomegalovirus Infection Among Preterm Infants Fed Maternal Milk in a Highly Seropositive Population. *Clin Infect Dis*. 2016;63(7):929-936.
10. Goelz R, Meisner C, Bevat A, Hamprecht K, Kraegeloh-Mann I, Poets CF. Long-term cognitive and neurological outcome of preterm infants with postnatally acquired CMV infection through breast milk. *Arch Dis Child Fetal Neonatal Ed*. 2013;98(5):F430-3.
11. Turner KM, Lee HC, Boppana SB, Carlo WA, Randolph DA. Incidence and impact of CMV infection in very low birth weight infants. *Pediatrics*. 2014;133(3):e609-e615.
12. Jim WT, Chiu NC, Ho CS, Shu CH, Chang JH, Hung HY et al. Outcome of Preterm Infants With Postnatal Cytomegalovirus Infection via Breast Milk: A Two-Year Prospective Follow-Up Study. *Medicine (Baltimore)*. 2015;94(43):e1835.
13. Gunkel J, de Vries LS, Jongmans M, Koopman-esseboom C, van Haastert IC, Eijsermans MCJ et al. Outcome of Preterm Infants With Postnatal Cytomegalovirus Infection. *Pediatrics*. 2018;141(2):e20170635.
14. Bevat A, Hamprecht K, Krägeloh-Mann I, Brosch S, Goelz R, Vollmer B. Long-term outcome in preterm children with human cytomegalovirus infection transmitted via breast milk. *Acta Paediatr*. 2012;101(4):e167-e172.

**Table 4 . Neonatal outcomes of extremely preterm infants diagnosed with postnatal CMV infection depending on their symptomatology**

	Asymptomatic (n = 5)	Symptomatic (n = 5)	P value
<b>Birth variables</b>			
Gestational age (weeks), median (IQR)	26.7 (25.6–27.4)	26.3 (25.6–27.1)	.65
Birth weight (g), median (IQR)	950 (690–1080)	750 (685–885)	.55
Male gender, n (%)	1 (20)	4 (80)	.21
Postmenstrual age at CMV detection, median (IQR)	34.7 (33.5–37.9)	32.1 (31.5–33.5)	.24
<b>Respiratory outcomes</b>			
Bronchopulmonary dysplasia, n (%)	1 (20)	5 (100)	.047
Invasive ventilation, n (%)	4 (80)	5 (100)	.99
Invasive ventilation, days, median (IQR)	3 (1–19)	21 (5–25)	.31
Invasive ventilation > 7 days, n (%)	1 (20)	4 (80)	.21
Systemic corticosteroids, n (%)	1 (20)	5 (100)	.047
Length of stay, days, median (IQR)	83 (73–108)	139 (109–203)	.032
<b>Growth variables at discharge</b>			
Weight (z-score), median (IQR)	-0.97 (-2.27,-0.41)	-2.23 (-2.84,-0.4)	.69
Length (z-score), median (IQR)	-1.04 (-1.77,0.23)	-2.63 (-3.2,0.19)	.42
Head circumference (z-score), median (IQR)	-0.18 (-0.92,0.44)	-1.03 (-2.1,-0.25)	.22

IQR, interquartile range. As gestational age at discharge varied between groups, growth variables were expressed as z-scores following the 2013 Fenton growth charts.

**Table 5 . Developmental outcomes at 12 months and 24 months corrected age in extremely preterm infants according to the diagnosis of postnatal CMV infection**

	12 months corrected age		P value	24 months corrected age		P value
	CMV- positive (n = 8)	CMV- negative (n = 28)		CMV- positive (n = 7)	CMV- negative (n = 22)	
<b>Growth variables</b>						
Weight, kg, median (IQR)	8.1 (7.4–10.1)	8.7 (8–9.8)	.69	11 (9.5–14)	11.7 (10.4–12.5)	.69
Head circumference, cm, median (IQR)	45.3 (43.1–48)	45.5 (44–46.9)	.8	47.5 (45–49.2)	48 (46–49.5)	.69
<b>Neurological examination</b>						
Normal, n (%)	7 (88)	23 (82)	.61	6 (86)	19 (86)	.53
Motor deficit, n (%)	1 (13)	3 (11)		1 (14)	1 (5)	
Cerebral palsy, n (%)	0	2 (7)		0	2 (9)	
<b>BSID-III*</b>						
Cognitive score, n (%)	8 (100)	26 (93)	.99	7 (100)	18 (82)	.98
≥ 85, n (%)	7 (87)	24 (92)		6 (86)	14 (78)	
< 85, n (%)	1 (13)	2 (8)		1 (14)	4 (22)	
Motor score, n (%)	7 (87)	24 (85)	.33	7 (100)	17 (77)	.99
≥ 85, n (%)	4 (57)	19 (79)		5 (71)	13 (77)	
< 85, n (%)	3 (43)	5 (21)		2 (29)	4 (23)	
Language score, n (%)	6 (75)	25 (89)	.99	6 (86)	18 (82)	.99
≥ 85, n (%)	6 (100)	22 (88)		4 (67)	11 (61)	
< 85, n (%)	0	3 (12)		2 (33)	7 (39)	

BSID-III, Bayley Scales of Infant and Toddler Development-Third edition; IQR, interquartile range. The BSID-III motor score includes fine and gross motor skills. A standardized BSID-III score < 85 indicates mild impairment. \*Excluding the 2 infants with cerebral palsy in the CMV-negative group, who could not perform the tests.

15. Brecht KF, Goelz R, Bevot A, Krägeloh-Mann I, Wilke M, Lidzba K. Postnatal human cytomegalovirus infection in preterm infants has long-term neuropsychological sequelae. *J Pediatr*. 2015;166(4):834-839.e1.
16. Picaud JC, Buffin R, Gremmo-Feger G, Rigo J, Putet G, Casper C et al. Review concludes that specific recommendations are needed to harmonise the provision of fresh mother's milk to their preterm infants. *Acta Paediatr*. 2018;107(7):1145-1155.
17. Lopes AA, Champion V, Mitanchez D. Nutrition of Preterm Infants and Raw Breast Milk-Acquired Cytomegalovirus Infection: French National Audit of Clinical Practices and Diagnostic Approach. *Nutrients*. 2018;10(8):1119.
18. Brasseur D, Rigo J, Melin P, Cossey V, Daube G, Goossens L et al. Report 8734: Recommendations on the use of raw own mother's milk for preterm infants ( $\leq$  28 weeks and/or  $<$  1000 g) in Neonatal Intensive Care Units [Internet]. Brussels: Superior Health Council; 2016 [Cited 2021 May 14]. Available from: <https://www.health.belgium.be/en/superior-health-council>.
19. Paludetti G, Conti G, Di Nardo W, De Corso E, Rolesi R, Picciotti PM et al. Infant hearing loss: from diagnosis to therapy Official Report of XXI Conference of Italian Society of Pediatric Otorhinolaryngology. *Acta Otorhinolaryngol Ital*. 2012;32(6):347-370.
20. Klotz D, Jansen S, Gebauer C, Fuchs H. Handling of Breast Milk by Neonatal Units: Large Differences in Current Practices and Beliefs. *Front Pediatr*. 2018;6:235.
21. Cossey V, Johansson AB, de Halleux V, Vanhole C. The use of human milk in the neonatal intensive care unit: practices in Belgium and Luxembourg. *Breastfeed Med*. 2012;7:302-306.
22. Van Laethem Y, Dubois J, Braeckman L, Delforge M, Donner C, de Mol P et al. Report 9262: Specific recommendations regarding the prevention of cytomegalovirus infections in mothers and newborns [Internet]. Brussels: Superior Health Council; 2015 [Cited 2021 May 14]. Available from: <https://www.health.belgium.be/en/superior-health-council>.
23. Josephson CD, Caliendo AM, Easley KA, Knezevic A, Shenvi N, Hinkes MT et al. Blood transfusion and breast milk transmission of cytomegalovirus in very low-birth-weight infants: a prospective cohort study. *JAMA Pediatr*. 2014;168(11):1054-1062.
24. Doctor S, Friedman S, Dunn MS, Asztalos EV, Wylie L, Mazzulli T et al. Cytomegalovirus transmission to extremely low-birthweight infants through breast milk. *Acta Paediatr*. 2005;94(1):53-58.
25. Mukhopadhyay S, Meyer SA, Permar SR, Puopolo KM. Symptomatic Postnatal Cytomegalovirus Testing among Very Low-Birth-Weight Infants: Indications and Outcomes. *Am J Perinatol*. 2016;33(9):894-902.
26. Prösch S, Lienicke U, Priemer C, Flunker G, Seidel WF, Krüger DH et al. Human adenovirus and human cytomegalovirus infections in preterm newborns: no association with bronchopulmonary dysplasia. *Pediatr Res*. 2002;52(2):219-224.
27. Vollmer B, Seibold-Weiger K, Schmitz-Salue C, Hamprecht K, Goelz R, Krageloh-Mann I et al. Postnatally acquired cytomegalovirus infection via breast milk: effects on hearing and development in preterm infants. *Pediatr Infect Dis J*. 2004;23(4):322-327.
28. Martinez-Gomez E, Perez-Carpena P, Flook M, Lopez-Escamez JA. A Systematic Review on the Association of Acquired Human Cytomegalovirus Infection with Hearing Loss. *J Clin Med*. 2020;9(12):4011.
29. Cossey V, Vanhole C, Eerdeken A, Rayyan M, Fieus S, Schuermans A. Pasteurization of mother's own milk for preterm infants does not reduce the incidence of late-onset sepsis. *Neonatology*. 2013;103(3):170-176.
30. Stock K, Griesmaier E, Brunner B, Neubauer V, Kiechl-Kohlendorfer U, Trawöger R. Pasteurization of breastmilk decreases the rate of postnatally acquired cytomegalovirus infections, but shows a nonsignificant trend to an increased rate of necrotizing enterocolitis in very preterm infants--a preliminary study. *Breastfeed Med*. 2015;10(2):113-117.
31. Bapistella S, Hamprecht K, Thomas W, Speer CP, Dietz K, Maschmann J et al. Short-term Pasteurization of Breast Milk to Prevent Postnatal Cytomegalovirus Transmission in Very Preterm Infants. *Clin Infect Dis*. 2019;69(3):438-344.

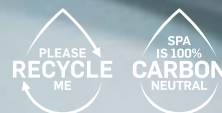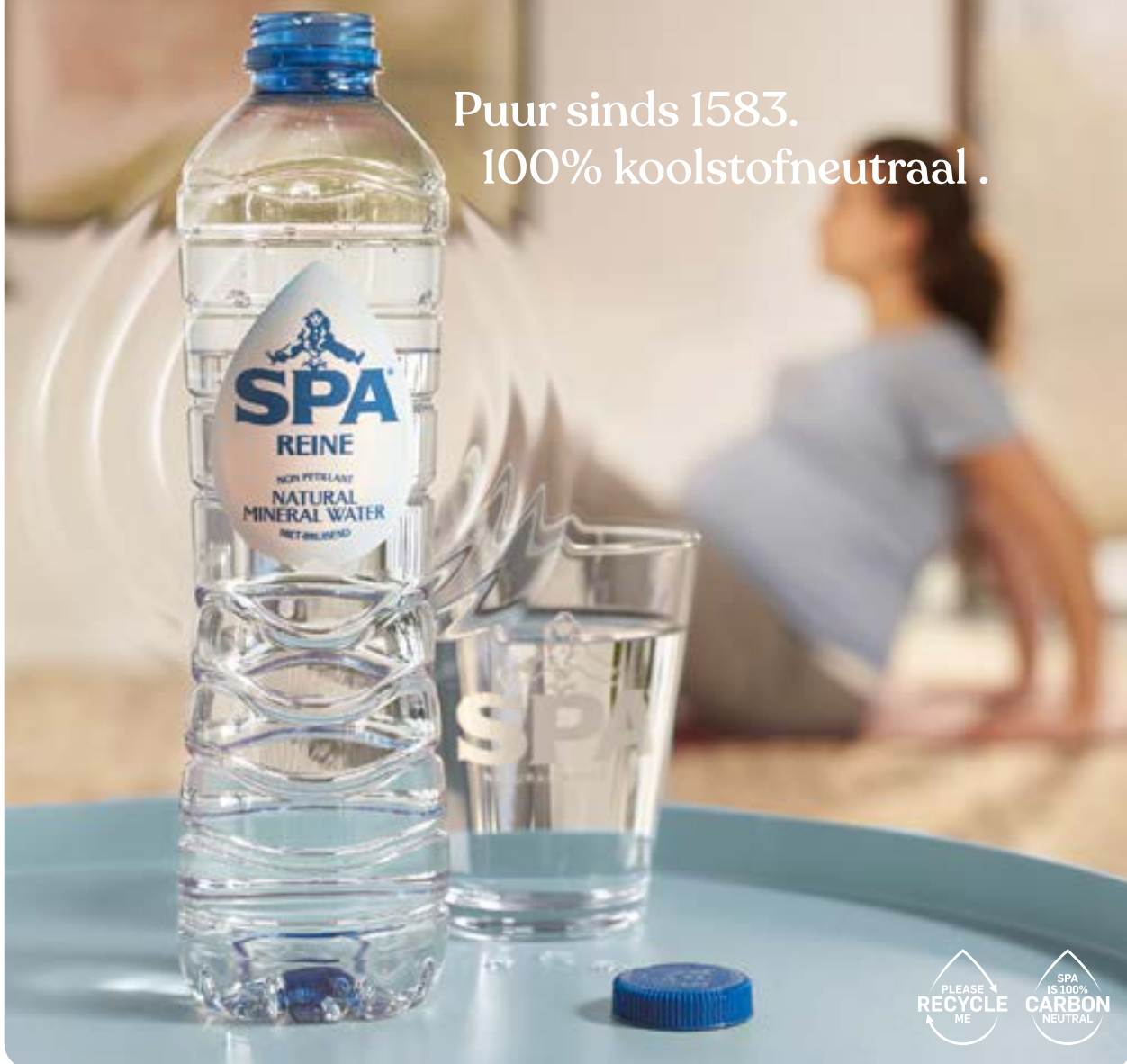**Table 6 . :** Developmental outcomes at 12 months and 24 months corrected age in extremely preterm infants with postnatal CMV infection depending on their symptomatology

	12 months corrected age		P value	24 months corrected age		P value
	Symptomatic (n = 4)	Asymptomatic (n = 4)		Symptomatic (n = 3)	Asymptomatic (n = 4)	
<b>Growth</b>						
Weight, kg, median (IQR)	7.6	9.3	.77	9.7	11.5	.38
	(7.4–10.2)	(7.1–10.8)		(9.5–9.9)	(9.8–14.7)	
Head circumference, cm, median (IQR)	44.8	45.3	.84	46	48	.38
	(43–48)	(43.6–48)		(44.5–47.5)	(45.8–50.1)	
<b>BSID-III'</b>						
Cognitive score, n (%)	4 (100)	4 (100)	.99	3 (100)	4 (100)	.43
≥ 85, n (%)	3 (75)	4 (100)		2 (67)	4 (100)	
< 85, n (%)	1 (25)	0		1 (33)	0	
Motor score, n (%)	4 (100)	3 (75)	.99	3 (100)	4 (100)	.99
≥ 85, n (%)	2 (50)	2 (67)		2 (67)	2 (67)	
< 85, n (%)	2 (50)	1 (33)		1 (33)	1 (33)	
Language score, n (%)	2 (50)	4 (100)	.99	2 (67)	4 (100)	.99
≥ 85, n (%)	2 (100)	4 (100)		2 (100)	3 (75)	
< 85, n (%)	0	0		0	1 (25)	

BSID-III, Bayley Scales of Infant and Toddler Development-Third edition; IQR, interquartile range. The BSID-III motor score includes fine and gross motor skills. A standardized BSID-III score  $<$  85 indicates mild impairment.

# Blijf puur.

Puur sinds 1583.  
100% koolstofneutraal .



## Beter drinken. Beter leven.

**SPA® REINE** is een **uiterst zuiver** natuurlijk mineraalwater dat door iedereen gedronken kan worden, op elk moment van de dag en zonder enige beperking. Het geheim van de legendarische zuiverheid? De **uiterst strenge bescherming van de omgeving** en de

jarenlange reis die het water maakt door de unieke ondergrond van de Venen. Dankzij deze ondergrondse reis verkrijgt SPA® Reine haar **unieke samenstelling**: het heeft een droogrest van slechts 38 mg per liter en is **uitermate geschikt voor de bereiding van babyvoeding**.

# Invasive meningococcal disease and vaccination in Belgium: a critical review of the current vaccination strategy

David Tuerlinckx<sup>a</sup>, Marc Raes<sup>b</sup>, Marek Wojciechowski<sup>c</sup>, Wesley Mattheus<sup>d</sup>, Laurence Derycker<sup>e</sup>, Kathleen Billiaert<sup>f</sup>, Jean-Michel Heine<sup>f</sup>, Jan Y Verbakel<sup>g,h</sup>

<sup>a</sup> CHU Dinant-Godinne, UCL Namur, Belgium

<sup>b</sup> Department of Pediatrics, Jessa Hospital, Hasselt, Belgium

<sup>c</sup> University of Antwerp, Antwerp University Hospital, department of Pediatrics, Edegem, Belgium

<sup>d</sup> National Reference Centre *Neisseria meningitidis*, Sciensano, Brussels, Belgium

<sup>e</sup> General Medicine, 5530 Godinne

<sup>f</sup> GSK, Wavre, Belgium

<sup>g</sup> Department of Public Health and Primary Care, KU Leuven, Leuven, Belgium;

<sup>h</sup> Nuffield Department of Primary Care Health Sciences, University of Oxford, Oxford, UK

david.tuerlinckx@uclouvain.be

## Keywords

*Neisseria meningitidis*; invasive meningococcal disease; Belgium; vaccines; epidemiology

## Abstract

In 2021, the World Health Organization issued a call to action to defeat meningitis by 2030. *Neisseria meningitidis* is a major cause of meningitis and septicaemia. Invasive meningococcal disease (IMD) is a severe and life-threatening disease but also vaccine-preventable. Monovalent serogroup C vaccines, quadrivalent meningococcal conjugate vaccines (MenACWY), and serogroup B vaccines (4CMenB, MenB-fHbp) have demonstrated safety and effectiveness in preventing IMD in infants through to young adults. Although the highest incidence of IMD is in infants <1 year of age, current recommendations in Belgium are not optimal and could be improved for this age-group. MenACWY is recommended for toddlers, adolescents, and risk-groups and 4CMenB on an individual basis for infants, adolescents and risk-groups. Neither MenACWY nor MenB vaccines are reimbursed. In this setting, low uptake of meningococcal vaccines is not unexpected, and meningococcal vaccines are conceivably less accessible to low-income families. A review and re-purposing of Belgium's meningococcal vaccination strategy is urgently needed. To this end we propose 6 readily achievable steps: 1) Increase awareness around disease and vaccine options amongst healthcare professionals and the public; 2) Encourage a proactive role for paediatricians and general practitioners; 3) Increase visibility of MenB vaccines in the calendar; 4) Consider reimbursement to increase coverage and avoid inequalities; 5) Learn from other countries that have successfully implemented meningococcal vaccination; 6) Optimise recommendations to protect age-groups/individuals at highest risk. The tools to prevent IMD in Belgium are available but under-utilised. Optimisation of the current meningococcal vaccination strategy could reduce the IMD burden in Belgium.

## Introduction to invasive meningococcal disease

*Neisseria meningitidis* is a major cause of bacterial meningitis and septicaemia beyond the neonatal period and in all world regions (1). The human nasopharynx is the only known reservoir for the bacterium, and transmission occurs through droplet spread or via throat secretions. Nasopharynx colonisation rates are highest in adolescents reaching up to 30-40% (2, 3). Invasive meningococcal disease (IMD) occurs when a newly acquired *N. meningitidis* strain residing in the nasopharynx is able to enter the blood stream (4).

The initial symptoms of IMD are frequently 'flu-like' and non-specific, especially in young infants and in the early stages of disease. Thus, diagnosis may be difficult until the red flag symptoms of meningitis (headache, neck stiffness, photophobia, vomiting or altered mental status) and/or meningococcaemia (purpuric rash and/or symptoms of septic shock) occur (5). The disease course is rapidly fulminant and death can occur within 24-48 hours after symptom onset. The case fatality rate is approximately 10%, despite appropriate anti-microbial therapy and intensive supportive treatment, but can reach up to 40% when meningococcaemia is present (5, 6). Higher mortality rates (16%) are reported in cases caused by serogroup W (MenW) clonal complex (or "variant") 11 (cc11) (6). In developed countries, up to 20% of survivors suffer long-term sequelae including amputation, scarring, cognitive and behavioural deficits, vision, hearing and neurological deficits,

with negative impacts on quality of life and life-time productivity (7, 8). While most cases can be prevented by vaccination, IMD has devastating consequences for patients, their families, and the broader public. Moreover, the treatment of IMD and its sequelae, and the management of outbreaks incur substantial direct and indirect costs (8).

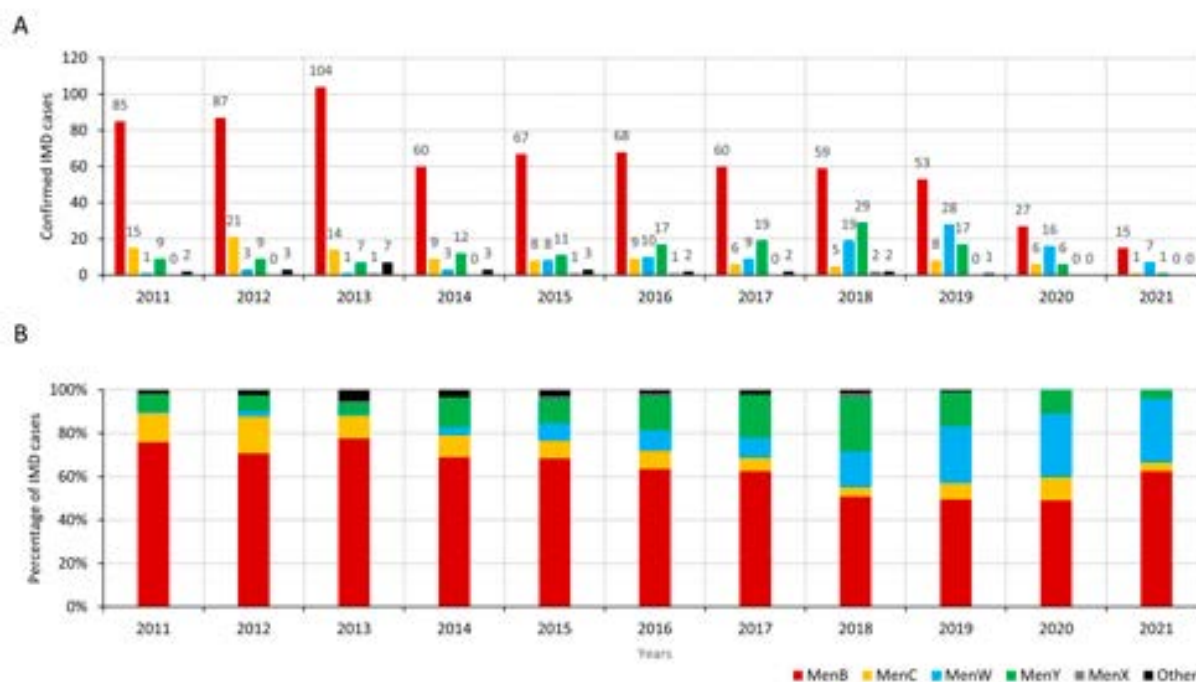## Epidemiology of IMD

Six meningococcal serogroups cause the majority of IMD: MenA, MenB, MenC, MenW, MenY and MenX, with marked temporal and regional differences in their distribution (1). According to the European Centre for Disease Prevention and Control, the number of cases caused by MenB overall decreased during the decade of 2009-2019 while cases of MenW and MenY progressively increased during the same time period. Moreover, reported cases decreased for all meningococcal serogroups for the year 2020 impacted by the SARS-CoV-2 pandemic (9). The highest incidence of IMD is in infants less than 1 year of age, with a second disease peak during adolescence, although IMD can occur at any age, including adults.

Belgian surveillance data mirror the picture across Europe (Figure 1) (10-12). From 2011 until 2021, the percentage of IMD caused by MenB progressively decreased in Belgium, plateauing at approximately 50% to 62.5% of cases since 2018. In line with trends observed elsewhere in

**Figure 1 :** A) Number B) percentage of cases of invasive meningococcal disease in Belgium from 2011 until 2021 by serogroup (11, 12). Men(B/C/W/Y/X); meningococcal serogroup (B/C/W/Y/X).

Note the continued increased in serogroup W and serogroup Y cases from 2015. Fewer cases were observed overall in 2020 and 2021 due to social distancing and hygiene measures secondary to the SARS-CoV-2 pandemic.



Europe, IMD caused by MenW and MenY has increased. The percentage of cases caused by MenY peaked in 2018 (25.0%) and appears to be reducing, whereas IMD caused by MenW has increased annually since 2014 (3.4% to 29.2% in 2021) (11, 12). The hypervirulent MenW cc11 strain originating in South America and responsible for outbreaks in the Netherlands and the United Kingdom (UK), was first observed in Belgium in 2016, and continues to cause IMD with high mortality to this day, more frequently in older age groups (6, 11). Another virulent MenW clone circulating in France (ST-9316) since 2013 was also identified in Belgium in recent years (11, 13-15). The emergence of virulent MenW clones prompted re-evaluation of meningococcal vaccination strategies in the Netherlands, UK and Belgium, with the adjustment of the vaccination calendar to reflect the changing serogroup distribution (16-18).

In 2019 the overall incidence of IMD in Belgium was approximately 1 case per 100,000 population. However, the incidence was 5-fold higher in children <5 years of age, and 15-fold higher in infants <1 year of age (19). As a result of social distancing and hygiene linked to infection mitigation strategies associated with the SARS-CoV-2 pandemic, the number of cases and incidence rate (IR) progressively decreased in all age-groups from 107 cases in 2019 (IR = 0.94 per 100,000) to 55 cases in 2020 (IR = 0.48 per 100,000) then 24 cases in 2021 (IR = 0.21 per 100,000) (11, 12). A return to previous levels is likely unless preventative actions are taken to uphold the current gains in IMD control. Furthermore, changes in serogroup circulation, emergence of more virulent meningococcal strains, potentially reduced carriage, and delays in routine vaccination related to lockdown periods may have caused a decline in meningococcal herd immunity, and an increase in the number of individuals susceptible to meningococcal infection (20). Early evidence from the UK has substantiated these concerns. There has been a sharp increase in MenB IMD observed in adolescents and young adults following relaxation of pandemic containment measures, to levels that have surpassed pre-pandemic rates (21). Post-pandemic mitigation surges in other infectious disease, such as respiratory syncytial virus infection in young children, have also been observed, leading to calls to maximise routine vaccination programs to prevent infection (22).

## Meningococcal vaccines and the Belgian meningococcal vaccination calendar

Currently available meningococcal vaccines fall into 2 groups: polysaccharide-protein conjugate vaccines and multi-component protein vaccines that include several highly expressed surface proteins as antigens (23).

### Polysaccharide-based meningococcal conjugate vaccines

The first meningococcal conjugate vaccines were monovalent MenC vaccines initially developed and licensed in response to a protracted MenC epidemic in the UK. These vaccines proved to be highly efficacious and also induced strong herd effects that reduced the incidence of IMD in unvaccinated cohorts (24, 25).

Multi-component conjugate vaccines targeting meningococcal serogroups A, C, W, and Y (MenACWY), were subsequently developed and are now used widely in many countries in infants, adolescents, individuals at high risk of IMD, and travellers to endemic regions (26). Available evidence points to high effectiveness of MenACWY vaccines against IMD, with reductions demonstrated in nasopharyngeal carriage of vaccine serogroups (27-29). The immune response to MenC induced by quadrivalent MenACWY has been shown to be similar to responses induced by monovalent MenC vaccines, suggesting that they confer similar protection (30, 31).

Monovalent MenC vaccine was recommended in Belgium from 2002 for use as a single dose at 15 months of age until 2019 (32). In 2019, the Belgian Superior Health Council replaced the monovalent vaccine with the quadrivalent MenACWY conjugate vaccine and added an additional dose at 15-16 years of age into the vaccination calendar, with catch-up vaccination in 15-19 year-olds until 2024 (32). This decision was based on several factors: 1) increasing MenW disease incidence in Belgium due to the hypervirulent cc11 strain; 2) evidence of increasing MenY disease; 3) data from studies showing waning immunity in adolescents against MenC 10 years after primary vaccination; 4) the age distribution of IMD caused by MenW and MenY; and 5) the potential for herd effects on unvaccinated individuals (17, 32, 33). According to their respective Belgian labels, the MenACWY

tetanus toxoid conjugate vaccine (*Nimenrix*, Pfizer) can be administered as 2 primary doses from 6 weeks to 5 months of age or a single primary dose as of 6 months of age, followed by a booster dose at 12 months (with at least 2 months interval between the last primary dose and booster), while the MenACWY diphtheria CRM<sub>197</sub> conjugate vaccine (*Menveo*, GSK) can be administered as a single dose from the age of 2 years (34, 35).

#### Multi-valent protein-based MenB vaccines

Prevention of MenB IMD required a different strategy because of poor immunogenicity of the MenB antigen and the potential for cross-reactivity with human neural proteins (36). Two protein-based vaccines were developed that use conserved surface proteins to induce protective immune responses.

*Bexsero* (4CMenB, GSK), contains 4 antigens: 3 surface proteins; factor H binding protein (fHbp), Neisserial Heparin Binding Antigen (NHBA), *Neisseria* adhesin A; and an outer membrane vesicle containing the Porin A P1.4 antigen previously used as a vaccine during an IMD epidemic in New Zealand (37). 4CMenB has been used in epidemic control in Canada and is implemented in 9 National Immunisation Programmes (NIPs) in the UK, Ireland, Italy, Lithuania, Malta, Czech Republic, Portugal, Andorra and San Marino, and in 3 regional programs in Spain and Australia and in a United States vaccination programme for adolescents (38). A solid body of observational studies and real-world evidence has demonstrated the safety, impact and effectiveness of 4CMenB in infants and young adults in several countries (38).

According to the Belgian product label, 4CMenB is indicated from 2 months of age (39). 4CMenB is administered in a 2+1 or 3+1 schedule in children aged 2 to 5 months of age at first dose; as a 2+1 schedule from 6 to 23 months of age at first dose; and as a 2-dose schedule from 2 years of age and older, with consideration of a booster dose for individuals at continued risk of exposure to meningococcal disease (39). In Belgium, vaccination is recommended on an individual basis for children from 2 months to 5 years of age, adolescents aged 15-19 years, and risk groups (32).

*Trumenba*, (MenB-fHbp, Pfizer) includes 2 fHbp variants. MenB-fHbp was immunogenic and well tolerated in clinical trials. MenB-fHbp was used in outbreak control in France and the United States (40-42), but real-world estimates of effectiveness are lacking.

According to the Belgian product label, MenB-fHbp is approved for use in a 2-dose or 3-dose schedule from the age of 10 years (43). In Belgium, MenB-fHbp is recommended on an individual basis for adolescents aged 15-19 years (32).

Vaccination against MenB is recommended by many countries for a large number of risk groups that include persons with asplenia, complement deficiency, complement inhibitors, or humoral immunosuppression (Table 1) (44, 45). A limited number of risk groups for MenB vaccination were listed in the 2017 Belgian MenB vaccine recommendations (46), but were not specifically defined in the 2019 updated recommendations (32).

### Obstacles to IMD control in Belgium

The tools to prevent the majority of IMD are available in vaccines that have been demonstrated to be safe and highly effective (24, 25, 28, 29, 38).

Currently available meningococcal vaccines target 5 of the 6 serogroups that cause most IMD in humans. MenW IMD has been effectively controlled in the Netherlands using a dose of MenACWY in toddlers and adolescents where coverage of 93% in toddlers and 86% in adolescents was achieved (47). While the move to MenACWY in young children and the introduction of an adolescent dose of MenACWY into the Belgian NIP is a strong step forward, the current strategy in Belgium is unlikely to achieve similar results because of sub-optimal vaccine uptake in some regions, especially in adolescents who are the main carriers of *N. meningitidis*. Additionally, the current vaccination calendar does not include MenB vaccines, and visibility and awareness of MenB vaccines is low.

Neither MenACWY nor MenB vaccines are reimbursed in Belgium for any age group and the full cost (52.60 euro for MenACWY vaccines, 86.52 euro for 4CMenB, and 76.98 euro for MenB-fHbp) is incurred by patients (48). Cost is a well-recognised barrier to meningococcal vaccine uptake and leads to health case discrimination when vaccination is only affordable for higher income families (49). A study in France showed that low household income and social disadvantage are risk factors for childhood IMD (50). Therefore, high vaccine costs can put meningococcal vaccination out of reach for families known to be at higher risk of IMD.

The rationale for many countries, including Belgium, not to include MenB vaccines in NIPs was based at the time on 1) the low incidence of MenB

**Table 1** : Specification of risk groups for vaccination against invasive meningococcal disease (IMD) caused by serogroup B (MenB)\* versus Belgium recommendations.

Populations at high risk of IMD caused by MenB	Belgian MenB vaccination recommendations (46)
Complement disorders (including properdin deficiency)	✓
Receiving complement inhibitor therapy (eculizumab or ravulizumab therapy)	✓
Asplenia/hyposplenism/ splenic dysfunction	✓
Immunocompromised individuals	✓
Primary immunodeficiency (including hypogammaglobulinemia)	✓
Autologous or allogeneic hematopoietic stem cell transplantation	✗
Solid organ transplant	✗
After bacterial meningitis and septicemia	✗
Human immunodeficiency virus infection	✗
Down Syndrome	✗
Professionally exposed (i.e., laboratory workers)	✗
During clusters/outbreaks	✗
Close contacts of cases	✗
Travellers to hyperendemic or epidemic countries	✗
Adolescents or adults exposed in big groups (universities, residence halls, military recruits)	✗
Men who have sex with men	✗

\*based on recommendations from the United States Centers for Disease Control and Prevention and the European Centre for Disease Control

IMD; 2) the difficulties of integrating a 3-dose series into infant vaccination calendars; 3) the increased likelihood of fever when co-administered with routine vaccines; 4) unfavourable cost-effectiveness; and 5) lack of data on efficacy, duration of protection and carriage (32, 44).

#### *Incidence and the under-recognised disease burden*

In Belgium, the incidence of IMD in children less than 1 year of age is 15 per 100,000 population, of which approximately 50% is due to MenB (2019) (19). This incidence rate is not far from the 2014 incidence in infants in the UK immediately prior to the introduction of routine 4CMenB vaccination (19 per 100,000 population of which 80% was due to MenB), and to the incidence of MenB IMD in the Saguenay-Lac-Saint-Jean region of Quebec of 11.4 per 100,000 ( $\leq 20$  year olds) that triggered a mass-immunisation programme (19, 51, 52). When IMD cases occur, the direct and societal costs are substantial and prolonged, lasting well past the acute treatment phase and often for a lifetime (8). It is thus regrettable that in 2019, most IMD cases in infants and children up to 5 years of age in Belgium were vaccine-preventable in a country where vaccines are readily available.

#### *Successful introduction into routine infant immunisation programmes has been demonstrated*

Countries that have introduced 4CMenB into their routine infant vaccination programmes have experienced high rates of acceptance and achieved high coverage rates. 4CMenB has been well accepted in the UK since its introduction in 2015, with 92.5% uptake of the primary immunisations in 2018 and no impact on compliance with other routine vaccinations (53, 54). 4CMenB can be co-administered with other routinely recommended vaccines (55). Concerns around acceptance of a third injection and of a higher rate of fever following co-administration have not proven to be major hurdles to implementation. A recommendation for prophylactic paracetamol administration prior to vaccination is associated with reduced rates of fever, with no clinical impact on the immune response of MenB and routine vaccines (56). Analysis of consultation rates of fever after 4CMenB vaccination found only a small increase compared to earlier years (57). In summary, the UK experience illustrates that initial concerns that were considered impediments to successful infant 4CMenB vaccination were unfounded.

#### *Updated cost-effectiveness analyses are needed*

In 2014, the Belgian Health Care Knowledge System published a cost-effectiveness analysis for MenB control in Belgium and concluded that vaccination would prevent no more than 16% of cases at high cost (58). The models' assumptions were based on a 3+1 schedule for infants whereas a 2+1 schedule is commonly employed, and the most recent real-world effectiveness and persistence data were not considered. The model also included rather low primary vaccination coverage of 55%; high rates of medical consultation and hospital admission for fever investigation; and the costs of ongoing disease surveillance. While some impacts of preventing long-term sequelae were included, the model did not include other potential benefits of 4CMenB vaccination that have since emerged, such as an impact on preventing IMD caused by other serogroups, and preliminary evidence suggesting a potential effect on preventing *Neisseria gonorrhoea* infections (38). Additionally, more precise estimates of the rates of post-vaccination fever consultations and hospitalisations are now available (57, 59). A new cost-effectiveness evaluation conducted for the UK using updated assumptions based on contemporary data and comprehensive disease burden inputs including long-term sequelae, found that 4CMenB infant vaccination at £75 per dose, can be cost-effective at a threshold of £20 000 per quality-of-life-year gained (60). Vaccine price is an important underlying assumption that has a major impact in cost-effectiveness models. On the other hand, a meta-analysis of data that did not include the updated UK analysis, did not demonstrate cost-effectiveness of MenB vaccination strategies (61). In view of the contradictory results published so far, updated health technology assessments in the Belgian context are warranted.

#### *Real-world evidence of effectiveness and impact, carriage, and safety is now available*

The published evidence demonstrating the effectiveness and impact of

4CMenB in preventing MenB IMD was collated in a review by Martinon-Torres et al, 2021 (38). Vaccine effectiveness in fully vaccinated cohorts ranged from 59%-100%, with evidence of continued protection up to 4 years after vaccination. Vaccine effectiveness was demonstrated across different age-groups and settings, including NIPs, observational studies and in outbreak control.

A prospective population-based study in Australian adolescents conclusively demonstrated that 4CMenB has no impact on nasopharyngeal carriage of meningococci, including MenB strains (62). This means that vaccination only protects the vaccinee, reinforcing the need for direct protection of at-risk groups such as infants and adolescents through individual vaccination.

Reviews of vaccine safety have not identified any safety concerns following the widespread use of 4CMenB in infants and adolescents (54, 63-65).

## **Towards a meningitis-free Belgium by 2030.**

In 2021, the World Health Organization (WHO) issued a call to action and published a road map to defeat meningitis by 2030, with the main goal to increase vaccination coverage (66). The 2030 objective is to reduce cases of vaccine-preventable bacterial meningitis by 50% and deaths by 70% compared to 2015 levels. In response to the WHO's mission, we propose the following strategy made up of 6 readily achievable steps with the aim of promoting an IMD-free Belgium by 2030 (Figure 2).

### Step 1: Increase awareness about disease and vaccine options amongst healthcare professionals and the public

Educating healthcare professionals and the public about diseases and the options available to prevent them is an important step in reducing hesitancy and improving uptake of all vaccines (67). Efforts to improve general knowledge about IMD and the available vaccine options need to employ all available communication means, including the regular media, social media, and influencers to increase reach and relevance to parents and young people.

### Step 2: Encourage a proactive role among paediatricians and general practitioners to engage in discussion with patients/parents

More awareness is needed about meningococcal vaccines and their pros and cons among vaccine providers in Belgium. General practitioners and paediatricians (supported by their professional organisations and medical societies) are a critical information gateway in recommending vaccines. Their role in informing their patients about vaccine options and encouraging their uptake is essential, particularly in the current setting of non-reimbursement.

### Step 3: Increase visibility of meningococcal vaccines currently not present in the vaccination calendar

Vaccines that are recommended by authorities, even if not reimbursed, should be clearly mentioned and made visible to healthcare professionals and the public via the vaccination calendar, which is considered to be the most reliable source of information for vaccinations. Including MenB vaccination as an option in the vaccination calendar, along with guidance on implementation such as the timing of vaccination with respect to other vaccines is a simple strategy that would provide a prompt, and a reminder to vaccine providers who might otherwise neglect or fail to remember this option.

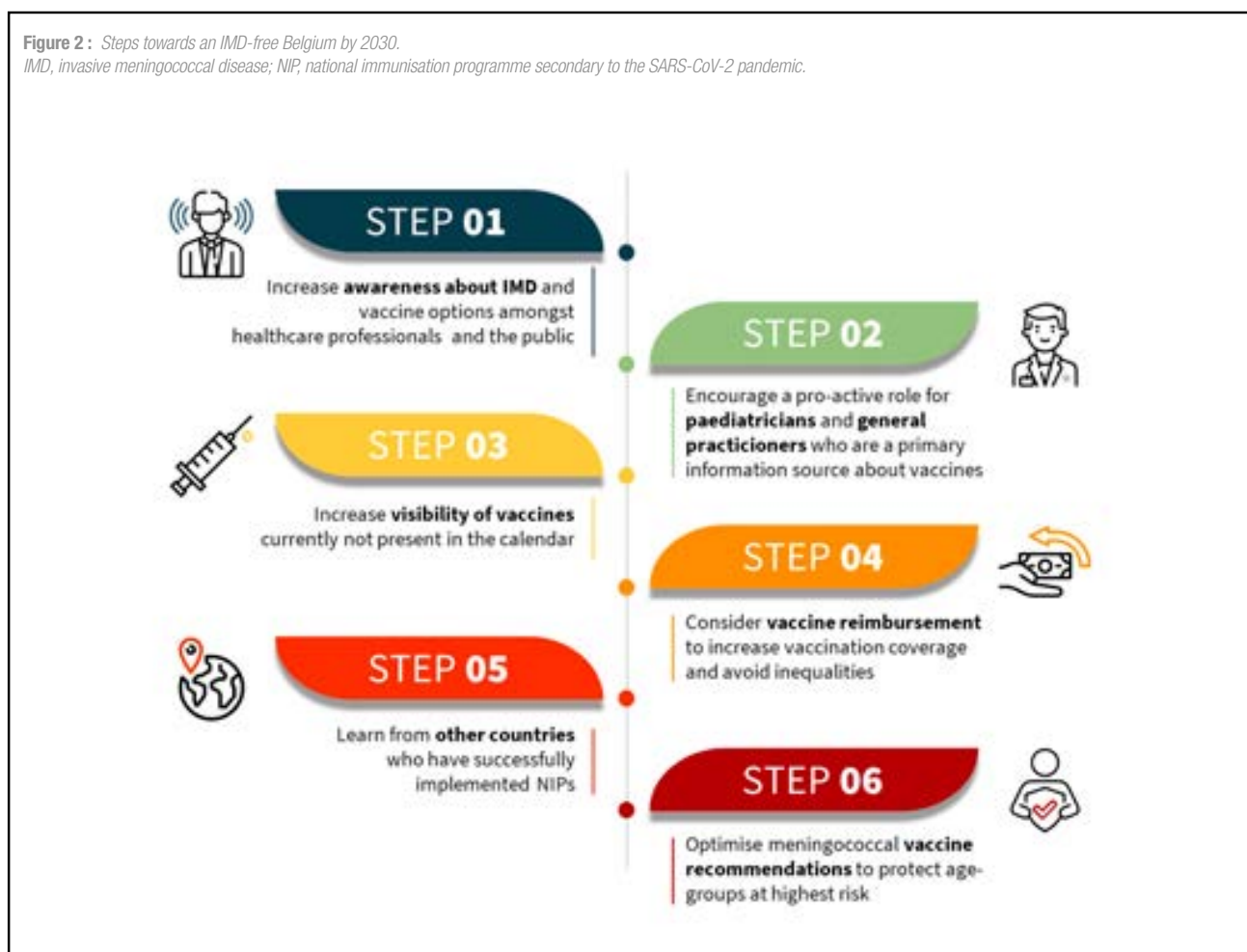
### Step 4: Consider vaccine reimbursement to increase vaccination coverage and avoid inequalities

Requiring full out-of-pocket payment for all meningococcal vaccines is a disincentive to uptake and leads to inequalities in health care among the economically and socially disadvantaged who are at higher risk of IMD, and least able to afford preventative measures (50). The issue of reimbursement is critical to success, with meningococcal vaccines currently out of reach for many families.

### Step 5: Learn from other countries that have successfully implemented NIPs

Countries such as the UK, the Netherlands, Portugal, Italy, and South Australia have successfully implemented mass vaccination programmes and

**Figure 2 :** Steps towards an IMD-free Belgium by 2030.  
 IMD, invasive meningococcal disease; NIP, national immunisation programme secondary to the SARS-CoV-2 pandemic.



have accumulated multiple years of experience with MenB or MenACWY vaccines in their NIPs. This knowledge can be harnessed to help optimise Belgium's meningococcal vaccine program.

Under a similar epidemiological setting to that currently existing in Belgium (10, 51), the UK included 4CMenB for infants in their NIP. The UK subsequently observed a 75% reduction in MenB disease incidence as well as an indirect impact of 69% on MenW disease in fully-eligible cohorts (53, 68). In the Saguenay-Lac-Saint-Jean region of Quebec, a mass vaccination campaign was initiated in <20 year olds and achieved a 100% reduction in the first 2 years of the programme (52). In both countries, success followed high vaccine uptake of 87.9% and 82%, respectively (52, 53). If higher coverage of MenB vaccines in combination with ACWY vaccinations can be achieved in the context of an improved NIP in Belgium, there is the potential for a direct impact on the burden of IMD, including the indirect and long-lasting consequences and costs of the disease.

**Step 6: Optimise meningococcal vaccine recommendations to protect age-groups with the highest incidence and persons at highest risk**

The peak incidence of IMD is in infants and most IMD is caused by MenB in this age-group. However, the vaccination recommendation for this age-group is only on an individual basis, with low public visibility (32). The MenACWY conjugate vaccines administered to adolescents in whom carriage and transmission is highest could reduce *N. meningitidis* transmission and protect other age-groups including infants and other age-groups via herd effects (69). By contrast, MenB vaccines do not induce herd protection and require a different strategy, that of direct protection to age-groups at risk. Consideration needs to be given to a recommendation for MenB vaccination in infants, and adolescents or young adults who are also at higher risk of MenB IMD. In infants, the additional benefit of cross-protection against MenW disease could be important in Belgium where the first MenACWY vaccine is not given until the second year of life.

On the other hand, revised advice for vaccine recommendations for people in special risk groups is warranted (Table 1) (45).

**Conclusion**

Achieving the WHO's goal to defeat meningitis by 2030 requires a review and re-purposing of Belgium's meningococcal vaccination strategy. The existing recommendations for MenACWY are unlikely to achieve their stated goal unless coverage in different age groups can be substantially improved through enhanced visibility, awareness, and reimbursement. MenB remains the most common cause of IMD in all age-groups, with the highest burden in infants. An effective vaccine for infants is available in Belgium, but achieving high uptake is challenging due to its cost and lack of visibility in the vaccination calendar. The concerns that steered many European authorities away from recommending and implementing MenB vaccination are no longer relevant and a re-evaluation of the role of MenB vaccines in the NIP as well as revised recommendation for persons at risk are warranted. In 2021, representatives of several scientific societies in France sent a strong call for the introduction of free MenB vaccination for infants, arguing that early reasons for not including MenB vaccines in the French calendar were no longer justified, and that it is unethical to offer protection against a potentially fatal disease only to families who can afford the vaccine (70).

The tools to prevent IMD in Belgium are available but under-utilised. A series of readily achievable steps could markedly reduce IMD, contributing to the WHO's goal of defeating meningitis by 2030.

**Trademark**

*Bexsero* and *Menveo* are trademarks owned by or licensed to the GSK group of companies.

*Trumenba* and *Nimenrix* are trademarks owned by or licensed to Pfizer.

## Conflicts of interest

DT, MR, MW, WM, LD, and JV declare no financial and non-financial relationships and activities and no conflicts of interest. JM and KB are employed by the GSK group of companies. The authors declare no other financial and non-financial relationships and activities.

## Funding

GlaxoSmithKline Biologicals SA took in charge all costs associated with the development and the publishing of the present manuscript.

## Acknowledgements

The authors thank Anne Meulemans, employed by the GSK group of companies, for her contribution to the manuscript review. The authors also thank Business & Decision Life Sciences platform for editorial assistance, writing support, manuscript coordination and design support for the digital illustrations, on behalf of GSK. Joanne Wolter provided writing support. Diego Collin and Elena Chaves Rodriguez coordinated manuscript development and editorial support.

## REFERENCES:

- Parikh SR, Campbell H, Bettinger JA, Harrison LH, Marshall HS, Martinon-Torres F, et al. The everchanging epidemiology of meningococcal disease worldwide and the potential for prevention through vaccination. *J Infect.* 2020;81(4):483-98.
- Soriano-Gabarró M, Wolter J, Hoge C, Vyse A. Carriage of *Neisseria meningitidis* in Europe: a review of studies undertaken in the region. *Expert Rev Anti Infect Ther.* 2011;9(9):761-74.
- Christensen H, May M, Bowen L, Hickman M, Trotter CL. Meningococcal carriage by age: a systematic review and meta-analysis. *Lancet Infect Dis.* 2010;10(12):853-61.
- Caugant DA, Maiden MCJ. Meningococcal carriage and disease--population biology and evolution. *Vaccine.* 2009;27 Suppl 2:B64-70.
- Rosenstein NE, Perkins BA, Stephens DS, Popovic T, Hughes JM. Meningococcal disease. *The New England Journal of Medicine.* 2001;344(18):1378-88.
- Loenenbach AD, van der Ende A, de Melker HE, Sanders EAM, Knol MJ. The Clinical Picture and Severity of Invasive Meningococcal Disease Serogroup W Compared With Other Serogroups in the Netherlands, 2015-2018. *Clin Infect Dis.* 2020;70(10):2036-44.
- Vyse A, Anonychuk A, Jäkel A, Wiewer H, Nadel S. The burden and impact of severe and long-term sequelae of meningococcal disease. *Expert Rev Anti Infect Ther.* 2013;11(6):597-604.
- Martinon-Torres F. Deciphering the Burden of Meningococcal Disease: Conventional and Under-recognized Elements. *J Adolesc Health.* 2016;59(2 Suppl):S12-20.
- ECDC. Surveillance Atlas of Infectious Diseases. Invasive meningococcal diseases. [Internet]. Stockholm: European Centre for Disease Prevention and Control; 2018 [cited 21 Nov 2021]. Available from <https://atlas.ecdc.europa.eu/public/index.aspx?Dataset=27&HealthTopic=36>.
- Raes M, Mattheus W, Strubbe F, Klein S. Epidemiology of invasive meningococcal disease in Belgium and implications for use of meningococcal vaccines in children and adolescents. *Belgian J Paediatr.* 2020;22(3):132-40.
- Jacquinet S, Mattheus W, Lajot A, Wyndham-Thomas C. Surveillance épidémiologique des infections invasives à méningocoques, *Neisseria Meningitidis* - 2020. In: Sciensano, VPD Annual Report. 2020. Bruxelles: Sciensano; [cited 2021 Nov 8]. Available from: <https://epidemiologie.viv-isp.be/ID/reports/Surveillance%20épidémiologique%20des%20infections%20invasives%20à%20méningocoques%20-%202020.pdf>.
- Bacteriële Ziekten. Nationaal Referentiecentrum voor meningokokken. In: Sciensano, VJaar 2021 nr 1, 4de trimester; [cited 2022 Mar 01]. Available from: <https://www.sciensano.be/en/biblio/infoblad-meningokokkeninfecties-2021-t4-0>
- Boon N, Grammens TM, W, Wyndham-Thomas C. Surveillance épidémiologique des infections invasives à méningocoques, *Neisseria Meningitidis* - 2017. In: Sciensano, VPD Annual Report. 2017. Bruxelles: Sciensano; [cited 2022 Jan 21]. Available from: <https://epidemiologie.viv-isp.be/ID/reports/Infections%20invasives%20C3%A0%20m%20C3%A9ningocoques%20-%20Epid%20C3%A9miologie%20-%20Rapport%20annuel%202017.pdf>.
- Santé publique France. Infections invasives à méningocoque [cited 2020 Jan 21]. Available from <https://www.santepubliquefrance.fr/maladies-et-traumatismes/maladies-a-prevention-vaccinale/infections-invasives-a-meningocoque/donnees/#tabs>.
- Deghmane AE, Haeghebaert S, Hong E, Jousset A, Barret AS, Taha MK. Emergence of new genetic lineage, ST-9316, of *Neisseria meningitidis* group W in Hauts-de-France region, France 2013-2018. *J Infect.* 2020;80(5):519-26.
- Campbell H, Saliba V, Borrow R, Ramsay M, Ladhani SN. Targeted vaccination of teenagers following continued rapid endemic expansion of a single meningococcal group W clone (sequence type 11 clonal complex), United Kingdom 2015. *Euro surveillance : bulletin Européen sur les maladies transmissibles = European communicable disease bulletin.* 2015;20(28):21188.
- Schetgen M, Richelle L. Actualisation du calendrier vaccinal belge de ces cinq dernières années : bases scientifiques et enjeux de santé publique. *Rev Med Brux.* 2021;43:190-8.
- Schurinck-van 't Klooster TM, de Melker HE, editors. National Institute for Public Health and the Environment. The national immunisation programme in the Netherlands. Surveillance and developments in 2018-2019. Bilthoven: National Institute for Public Health and the Environment (RIVM); 2019. [Cited 2021 Nov 8]. 2019. Available from: <http://www.rivm.nl/bibliotheek/rapporten/2019-0193.pdf>.
- Jacquinet S, Mattheus W, Lajot A, Wyndham-Thomas C. Surveillance épidémiologique des infections invasives à méningocoques, *Neisseria Meningitidis* - 2019. In: Sciensano, VPD Annual Report. 2019. Bruxelles: Sciensano; [cited 2021 Nov 8]. Available from: [https://www.sciensano.be/sites/default/files/surveillance\\_epidemiologique\\_des\\_infections\\_invasives\\_a\\_meningocoques\\_-\\_2019\\_2.pdf](https://www.sciensano.be/sites/default/files/surveillance_epidemiologique_des_infections_invasives_a_meningocoques_-_2019_2.pdf).
- Cohen R, Ashman M, Taha MK, Varon E, Angoultant F, Levy C, et al. Pediatric Infectious Disease Group (GPIP) position paper on the immune debt of the COVID-19 pandemic in childhood, how can we fill the immunity gap? *Infect Dis Now.* 2021;51(5):418-23.
- Clark S, Campbell H, Mensah A, Lekshmi A, Walker A, Ribeiro S, et al. An increase in group B invasive meningococcal disease among adolescents and young adults in England following easing of COVID-19 containment measures. (December 16, 2021). [cited 2022, Mar 1]. Available from SSRN: <https://ssrn.com/abstract=3998164> or <http://dx.doi.org/10.2139/ssrn.3998164>. 2022.
- Cohen R, Pettoello-Mantovani M, Somekh E, Levy C. European Pediatric Societies Call for an Implementation of Regular Vaccination Programs to Contrast the Immunity Debt Associated to Coronavirus Disease-2019 Pandemic in Children. *J Pediatr.* 2022;242:260-1 e3.
- Pizza M, Bekkat-Berkani R, Rappuoli R. Vaccines against meningococcal diseases. *Microorganisms.* 2020;8(10):1521.
- Miller E, Salisbury D, Ramsay M. Planning, registration, and implementation of an immunisation campaign against meningococcal serogroup C disease in the UK: a success story. *Vaccine.* 2001;20 Suppl 1:S58-67.
- Trotter CL, Andrews NJ, Kaczmarski EB, Miller E, Ramsay ME. Effectiveness of meningococcal serogroup C conjugate vaccine 4 years after introduction. *Lancet.* 2004;364(9431):365-7.
- Ruiz Garcia Y, Abitbol V, Pellegrini M, Bekkat-Berkani R, Soumahoro L. A Decade of Fighting Invasive Meningococcal Disease: A Narrative Review of Clinical and Real-World Experience with the MenACWY-CRM conjugate Vaccine. *Infectious diseases and therapy.* 2021;30:1-17. doi:0.1007/s40121-021-00519-2 . Online ahead of print.
- Korzeniewski K, Skoczka A, Guzek A, Konior M, Chciałowski A, Wałko I, et al. Effectiveness of immunoprophylaxis in suppressing carriage of *Neisseria meningitidis* in the military environment. *Adv Exp Med Biol.* 2015;836:19-28.
- Im JH, Woo H, Ha BM, Lee JS, Chung MH, Jung J. Effectiveness of a single dose of the quadrivalent meningococcal conjugate vaccine, MenACWY-CRM, in the Korean Armed Forces. *Vaccine.* 2020;38(4):730-2.
- Macneil JR, Cohn AC, Zell ER, Schmink S, Miller E, Clark T, et al. Early estimate of the effectiveness of quadrivalent meningococcal conjugate vaccine. *Pediatr Infect Dis J.* 2011;30(6):451-5.
- Vesikari T, Forstén A, Boutriau D, Bianco V, Van der Wielen M, Miller JM. Randomized trial to assess the immunogenicity, safety and antibody persistence up to three years after a single dose of a tetravalent meningococcal serogroups A, C, W-135 and Y tetanus toxoid conjugate vaccine in toddlers. *Hum Vaccin Immunother.* 2012;8(12):1892-903.
- Snape MD, Perrett KP, Ford KJ, John TM, Pace D, Yu L-M, et al. Immunogenicity of a tetravalent meningococcal glycoconjugate vaccine in infants: a randomized controlled trial. *JAMA: The Journal of the American Medical Association.* 2008;299(2):173-84.
- Conseil Supérieur de la Santé (CSS). Vaccination contre le méningocoque. Brussels: CSS; 2019 [Update 2019 Aug 29; cited 2021 Nov 8]. Available from: [https://www.health.belgium.be/sites/default/files/uploads/fields/fpshealth\\_theme\\_file/css\\_9485\\_vaccination\\_contre\\_le\\_meningocoque\\_update.pdf](https://www.health.belgium.be/sites/default/files/uploads/fields/fpshealth_theme_file/css_9485_vaccination_contre_le_meningocoque_update.pdf).

33. Khatami A, Peters A, Robinson H, Williams N, Thompson A, Findlow H, et al. Maintenance of immune response throughout childhood following serogroup C meningococcal conjugate vaccination in early childhood. *Clin Vaccine Immunol*. 2011;18(12):2038-42.
34. Résumé des Caractéristiques du Produit. Menveo. 04 December 2014. [cited January 13, 2022]. Available from <https://bjsluiters.fagg-afmps.be/?localeValue=en>.
35. Résumé des Caractéristiques du Produit. Nimenrix. 16 February 2017. [cited January 13, 2022]. Available from <https://bjsluiters.fagg-afmps.be/?localeValue=en>.
36. Finne J, Leinonen M, Mäkelä PH. Antigenic similarities between brain components and bacteria causing meningitis. Implications for vaccine development and pathogenesis. *Lancet*. 1983;2(8346):355-7.
37. Toneatto D, Pizza M, Masignani V, Rappuoli R. Emerging experience with meningococcal serogroup B protein vaccines. *Expert Rev Vaccines*. 2017;16(5):433-51.
38. Martinon-Torres F, Banzhoff A, Azzari C, De Wals P, Marlow R, Marshall H, et al. Recent advances in meningococcal B disease prevention: real-world evidence from 4CMenB vaccination. *J Infect*. 2021;83(1):17-26.
39. Résumé des Caractéristiques du Produit. Bexsero. 18 September 2017. [cited January 13, 2022]. Available from <https://bjsluiters.fagg-afmps.be/?localeValue=en>.
40. Fiorito TM, Baird GL, Alexander-Scott N, Bornschein S, Kelleher C, Du N, et al. Adverse events following vaccination with bivalent rLP2086 (Trumenba(R)): an observational, longitudinal study during a college outbreak and a systematic review. *Pediatr Infect Dis J*. 2018;37(1):e13-e9.
41. Fiorito TM, Bornschein S, Mihalakos A, Kelleher CM, Alexander-Scott N, Kanadianian KV, et al. Rapid response to a college outbreak of meningococcal serogroup B disease: Nation's first widespread use of bivalent rLP2086 vaccine. *J Am Coll Health*. 2017;65(4):294-6.
42. Taha MK, Hawkins JC, Liberator P, Deghmane AE, Andrew L, Hao L, et al. Bactericidal activity of sera from adolescents vaccinated with bivalent rLP2086 against meningococcal serogroup B outbreak strains from France. *Vaccine*. 2017;35(11):1530-7.
43. Résumé des Caractéristiques du Produit. Trumenba. 24 May 2017. [cited January 13, 2022]. Available from <https://bjsluiters.fagg-afmps.be/?localeValue=en>.
44. European Centre for Disease Prevention and Control. Scientific Advice. Expert opinion on the introduction of the meningococcal B (4CMenB) vaccine in the EU/EEA; Stockholm: ECDC; 2017. [cited 2021 Nov 8]. Available from: <https://www.ecdc.europa.eu/sites/default/files/documents/Introduction-of-4CMenB-vaccine.pdf>.
45. Mbaeyi SA, Bozio CH, Duffy J, Rubin LG, Hariri S, Stephens DS, et al. Meningococcal Vaccination: Recommendations of the Advisory Committee on Immunization Practices, United States, 2020. *MMWR Recomm Rep* 2020;69(9):1-41.
46. Belgian Superior Health Council. Advies van de hoge gezondheidsraad nr. 9125. 2017. Available from: [https://www.health.belgium.be/sites/default/files/uploads/fields/fpshealth\\_theme\\_file/hgr\\_advies\\_9125\\_meningokokken.pdf](https://www.health.belgium.be/sites/default/files/uploads/fields/fpshealth_theme_file/hgr_advies_9125_meningokokken.pdf). Accessed 06 January 2022.
47. Ohm M, Hahne SJM, van der Ende A, Sanders EAM, Berbers GAM, Ruijs WLM, et al. Vaccine impact and effectiveness of meningococcal serogroup ACWY conjugate vaccine implementation in the Netherlands: a nationwide surveillance study. *Clin Infect Dis*. 2021. Sep 15;ciab791. doi: .10.1093/cid/ciab791. Online ahead of print. .
48. CBIP. Commented Directory of Medicines. [Internet] [cited 2021 May 20]. Available from [https://www.cbip.be/fr/chapters/13?frag=11445&trade\\_family=23762](https://www.cbip.be/fr/chapters/13?frag=11445&trade_family=23762).
49. Malerba V, Costantino C, Napoli G, Marchese V, Casuccio A, Tabacchi G, et al. Antimeningococcal and antipneumococcal vaccination determinants: a European systematic literature review. *Epidemiol Prev*. 2015;39(4 Suppl 1):59-64.
50. Taha MK, Weil-Olivier C, Bouee S, Emery C, Nachbaur G, Pribil C, et al. Risk factors for invasive meningococcal disease: a retrospective analysis of the French national public health insurance database. *Hum Vaccin Immunother*. 2021;17(6):1858-66.
51. Public Health England. Invasive meningococcal disease (laboratory reports in England): 2014/2015 annual data by epidemiological year. *Health Protection Report* 2015;9(38):1-3.
52. De Wals P, Deceuninck G, Lefebvre B, Tsang R, Law D, De Serres G, et al. Impact of an immunization campaign to control an increased incidence of serogroup B meningococcal disease in one region of Quebec, Canada. *Clin Infect Dis*. 2017;64(9):1263-7.
53. Ladhani SN, Andrews N, Parikh SR, Campbell H, White J, Edelstein M, et al. Vaccination of infants with meningococcal group B vaccine (4CMenB) in England. *N Engl J Med*. 2020;382(4):309-17.
54. Bryan P, Seabroke S, Wong J, Donegan K, Webb E, Goldsmith C, et al. Safety of multicomponent meningococcal group B vaccine (4CMenB) in routine infant immunisation in the UK: a prospective surveillance study. *The Lancet Child & adolescent health*. 2018;2(6):395-403.
55. European Medicines Agency. Bexsero. Summary of Product Characteristics. 2020. [Internet] [cited 2020 Aug 24]. Available from [http://www.ema.europa.eu/ema/index.jsp?curl=pages/medicines/human/medicines/002333/human\\_med\\_001614.jsp&mid=WC0b01ac058001d124](http://www.ema.europa.eu/ema/index.jsp?curl=pages/medicines/human/medicines/002333/human_med_001614.jsp&mid=WC0b01ac058001d124).
56. Prymula R, Esposito S, Zuccotti GV, Xie F, Toneatto D, Kohl I, et al. A phase 2 randomized controlled trial of a multicomponent meningococcal serogroup B vaccine (I). *Hu Vacc Immunother* 2014;10(7):1993-2004.
57. Harcourt S, Morbey RA, Bates C, Carter H, Ladhani SN, de Lusignan S, et al. Estimating primary care attendance rates for fever in infants after meningococcal B vaccination in England using national syndromic surveillance data. *Vaccine*. 2018;36(4):565-71.
58. Hanquet G, Christensen H, Agnew E, Trotter C, Robays J, Dubois C, et al. un vaccin quadrivalent contre le méningocoque du groupe B : analyse coût-efficacité.–Synthèse. Health Technology Assessment (HTA). KCE Reports 231Bs [Internet]. Brussels: Centre Fédéral d'Expertise des Soins de Santé (KCE); 2014. [cited 2021 Nov 8]. Available from; [https://kce.fgov.be/sites/default/files/atoms/files/KCE\\_231Bs\\_Meningocoque%20B\\_Synthese.pdf](https://kce.fgov.be/sites/default/files/atoms/files/KCE_231Bs_Meningocoque%20B_Synthese.pdf). .
59. Murdoch H, Wallace L, Bishop J, Robertson C, Claire Cameron J. Risk of hospitalisation with fever following MenB vaccination: self-controlled case series analysis. *Arch Dis Child*. 2017;102(10):894-8.
60. Beck E, Klint J, Neine M, Garcia S, Meszaros K. Cost-Effectiveness of 4CMenB Infant Vaccination in England: A Comprehensive Valuation Considering the Broad Impact of Serogroup B Invasive Meningococcal Disease. *Value Health*. 2021;24(1):91-104.
61. Nwogu IB, Jones M, Langley T. Economic evaluation of meningococcal serogroup B (MenB) vaccines: A systematic review. *Vaccine*. 2021;39(16):2201-13.
62. Marshall HS, McMillan M, Koehler AP, Lawrence A, Sullivan TR, MacLennan JM, et al. Meningococcal B vaccine and meningococcal carriage in adolescents in Australia. *N Engl J Med*. 2020;382(4):318-27.
63. Hall GC, Douglas I, Heath PT, Prabhakar P, Rosillon D, Khan J, et al. Post-licensure observational safety study after meningococcal B vaccine 4CMenB (Bexsero) vaccination within the routine UK immunisation program. *Vaccine*. 2021;39(24):3296-303.
64. Marshall HS, Koehler AP, Wang B, A'Houré M, Gold M, Quinn H, et al. Safety of meningococcal B vaccine (4CMenB) in adolescents in Australia. *Vaccine*. 2020;38(37):5914-22.
65. De Serres G, Billard MN, Gariépy MC, Rouleau I, Toth E, Landry M, et al. Short-term safety of 4CMenB vaccine during a mass meningococcal B vaccination campaign in Quebec, Canada. *Vaccine*. 2018;36(52):8039-46.
66. World Health Organization. Defeating meningitis by 2030: a global road map. [Internet]. Geneva: WHO; 2021 [cited 2021 Nov 8]. Available from <https://apps.who.int/iris/bitstream/handle/10665/342010/9789240026407-eng.pdf?sequence=1&isAllowed=y>. 2021.
67. Simone B, Carrillo-Santistevé P, Lopalco PL. Healthcare workers role in keeping MMR vaccination uptake high in Europe: a review of evidence. *Euro Surveill*. 2012;17(26).
68. Ladhani SN, Campbell H, Andrews N, Parikh SR, White J, Edelstein M, et al. First real world evidence of meningococcal group B vaccine, 4CMenB, protection against meningococcal group W disease; prospective enhanced national surveillance, England. *Clin Infect Dis*. 2020.
69. Vetter V, Baxter R, Denizer G, Sáfadi MAP, Silfverdal S-A, Vyse A, et al. Routinely vaccinating adolescents against meningococcus: targeting transmission & disease. *Expert Rev Vaccines*. 2016;15(5):641-58.
70. Gras-Le Guen C, Vignier N, Kochert F, Javouhey E, Launay E, Dufour V, et al. Why should the meningococcal B vaccine be recommended, and therefore reimbursed, for infants in France? *Infect Dis Now*. 2021;51(5):407-9.

# Mustela®



Pour toute  
la famille



## La protection solaire **qui a tout bon**

Haute tolérance bébé-enfant, convient dès la naissance\*  
et pour les femmes enceintes en cas d'exposition inévitable

\*Bébés sortis de néonatalogie - Respect de l'océan : filtres conformes à la réglementation d'Hawaï, sans oxybenzone ni octinoxate.  
Avocats biologiques et upcyclés issus de l'agriculture durable et d'une chaîne d'approvisionnement responsable

## Case Report

# Case series of Multisystem Inflammatory Syndrome in Children (MIS-C) after a SARS-CoV-2 infection

Marlies Geurickx<sup>a,c</sup>, Sietske Vermaning<sup>b</sup>, Thomas Crijnen<sup>b</sup>, Ine Gerard<sup>b</sup>, Els Vanderschaeghe<sup>c</sup>, Anke Raaijmakers<sup>a,c</sup>

<sup>a</sup> University of Leuven, Department of Paediatrics, Leuven, Belgium

<sup>b</sup> Paediatric Intensive Care Unit, ZNA Queen Paola Children's Hospital, Antwerp, Belgium

<sup>c</sup> Department of Paediatrics, ZNA Jan Palfijn General Hospital, Antwerp, Belgium

anke.raaijmakers@zna.be

### Keywords

Multisystem Inflammatory Syndrome in Children and adolescents (MIS-C), Paediatric Multisystem Inflammatory Syndrome temporally associated with SARS-CoV-2 (PIMS-TS), COVID-19, severe acute respiratory syndrome coronavirus 2 (SARS-CoV-2)

### Abstract

#### Background

Multisystem inflammatory syndrome in children (MIS-C) is an entity in which children develop fever, raised inflammatory parameters, abdominal complaints and/or Kawasaki-like symptoms with signs of decreased cardiac function, weeks after a primary infection by severe acute respiratory syndrome coronavirus 2 (SARS-CoV-2). Complications include shock and coronary artery aneurysms. Off-label use of intravenous immunoglobulins and corticosteroids have shown good results in previous reports.

#### Case series

We present our experience of five patients who met criteria for MIS-C. Their presentation varied widely; three patients had abdominal complaints with a non-specific presentation and the others had Kawasaki-like symptoms. All had highly elevated inflammatory parameters and cardiac enzyme levels. Three showed intra-abdominal signs of inflammation. Two patients needed transfer to an intensive care unit. They were all treated with intravenous immunoglobulins after which all patients recovered quickly with no residual problems to date.

#### Conclusions

Our cases are in line with current evidence that clinical presentation of MIS-C is extremely variable, and evolution is favourable after treatment with intravenous immunoglobulins. Further research is necessary to substantiate current guidelines and to analyse possible links we have encountered between developing MIS-C and ethnic background, environment, and specific SARS-CoV-2 strains.

### Introduction

Reports from the beginning of the severe acute respiratory syndrome coronavirus 2 (SARS-CoV-2) pandemic suggested children to be less frequently and less severely affected by this viral infection in comparison to adults. They also stated that children were rarely in need of intensive care treatment. However, from April 2020 onwards, reports emerged of children seriously affected by hyperinflammatory shock with multi-organ involvement seemingly associated with an infection by the novel virus. Patients typically presented four to eight weeks after a presumed primary SARS-CoV-2 infection with acute symptoms of fever, abdominal complaints (pain, vomiting and diarrhoea), signs of shock, rash, conjunctival injection, neurologic symptoms and sometimes respiratory symptoms (1,2). Laboratory investigations revealed raised inflammatory parameters. The new entity showed features partially similar to those of Kawasaki disease (KD), toxic shock syndrome, haemophagocytic lymphohistiocytosis, and macrophage activation syndrome (3). Based on these reports, a preliminary definition was created by the World Health Organisation (WHO) in May 2020, labelling the condition as "Multisystem Inflammatory Syndrome in Children and adolescents" (MIS-C) (4). According to the WHO definition, cases of children and adolescents between 0 and 19 years of age with fever for a period of at least three days, in combination with specifically described clinical features and raised inflammatory parameters, and evidence of a (past) SARS-CoV-2 infection or likely contact with patients with such an infection, meet the criteria for MIS-C.

In analogy to KD, patients are favourably treated with intravenous immunoglobulins (IVIG) and corticosteroids as shown by some studies (5,6). Treatment nearly always provided a positive outcome, but patients could die in extremely severe cases (<1%). A frequently seen complication was the development of coronary artery aneurysms and ventricle dysfunction, though resolution of these cardiac abnormalities was seen in most patients within

months (7–11). In this article we presented our experience with MIS-C in a case series of five children over the course of two months and reviewed the literature on some topics of interest.

### Case Series

Over the course of 2 months, we saw a total of five cases of MIS-C in the paediatric department of our general hospital in the suburbs of Antwerp. In the subsequent paragraphs, we discussed them one-by-one and an overview of the cases can be found in Table 1. Diagnosis and treatment plan were made based on the guidelines created by the Belgian Institute of Health (Sciensano), by the PIMS-TS National Consensus Management Study Group in the United Kingdom and by specialists of New York-Presbyterian Morgan Stanley Children's Hospital of New York City in the United States (12).

The first patient was a 15-year-old girl who presented to the emergency department because of abdominal pain for a period of five days, vomiting and fever. Based on a thorough first assessment, the preferred initial diagnosis was sigmoiditis for which she was admitted and treated with intravenous antibiotics (amoxicillin-clavulanic acid). Due to aggravation of pain the following day, an explorative laparoscopy was performed the same day, which showed intraperitoneal free fluid and an oedematous terminal ileum. It was decided not to adjust the initial therapy. Two days later her clinical state worsened dramatically, with a drop in blood pressure (100/60 mmHg), signs of poor circulation and respiratory distress. Crepitations were heard on auscultation and a computed tomography scan revealed a bilateral pneumonia. The antibiotic therapy was switched to piperacillin/tazobactam (4 grams four times a day). By giving a fluid bolus and supplemental oxygen, it was tried to stabilise her clinical condition, but her situation remained precarious.

She was transferred to the paediatric intensive care unit (PICU Paola Children Hospital, Antwerp, Belgium and subsequently PICU UZ Ghent, Ghent, Belgium). An echocardiography showed a decreased left ventricle function (fractional shortening 15-17%, ejection fraction 30-50%) and a dilated left coronary artery (LCA 3.3 mm). Cardiac enzymes were elevated as well, with a high-sensitivity troponin T (HsTropT) level of 47.2 ng/L (normal value <12 ng/L) and a N-terminal pro-brain-type natriuretic peptide (NT-pro-BNP) level of 24518 pg/mL (normal value <217 pg/mL), supporting a diagnosis of myocarditis. She was tested positive for SARS-CoV-2 by PCR a few days before admission and antibodies were tested positive during admission. The patient was given a single dose of IVIG (2 g/kg) and a high dose of methylprednisolone (20 mg/kg) and was started on intravenous acetylsalicylic acid (250 mg once daily). To maintain an acceptable blood pressure, she briefly received inotropic/vasodilating treatment. With this treatment plan, her clinical state gradually improved over the following days, with full recovery of the cardiac function and relief of the respiratory distress. At follow-up three weeks after discharge she was generally well, except for mild persisting anaemia (haemoglobin 10.0 g/dL) and some fatigue. Cardiac follow-up one month after discharge showed normalisation of the left ventricle function and coronary arteries.

The second case was a teenage boy whose presenting symptoms were abdominal pain and diarrhoea for three days, fever, anorexia, headache and fatigue. He had a non-toxic appearance, dull heart sounds and a painful examination of the right fossa with some muscle defence. An abdominal ultrasound was suggestive for acute appendicitis. The initial laboratory results showed minimally elevated leukocytes ( $10.8 \times 10^9/L$ , reference  $4.4\text{--}10.6 \times 10^9/L$ ), C-reactive protein (CRP) of 114.5 mg/L (normal value <5 mg/L) and normal renal and liver function values. Awaiting the SARS-CoV-2 antibody and PCR test results it was decided to maintain expectant management and the boy was kept under observation. Over the following two days he remained febrile, his abdominal pain worsened and he vomited several times. The patient developed tachycardia but his blood pressure remained stable. Laboratory testing confirmed a further elevation of inflammatory parameters (leukocytes  $11.3 \times 10^9/L$ , CRP 207 mg/L, erythrocyte sedimentation rate 104 mm/h (normal <15), ferritin 598  $\mu\text{g/L}$  (normal value 30-400  $\mu\text{g/L}$ )), mildly prolonged coagulation time (international normalised ratio 1.32, reference 0.87-1.20), positive SARS-CoV-2 antibodies and mildly elevated cardiac enzymes (HsTropT 19.6 ng/L, NT-pro-BNP 2196 pg/mL). Since the patient met the criteria for MIS-C, treatment with IVIG (2 g/kg), IV cefotaxime (100 mg/kg/day) and subcutaneous heparin (2000 IU twice daily) was started. The next day his abdominal complaints improved significantly. The boy was discharged following full recovery after eleven days. At follow-up one week later, he did not have any complaints and showed normalised inflammatory parameters.

Case number three was a 10-year-old girl who presented at the outpatient clinic, after having been treated for the last five days with amoxicillin orally (500 mg three times daily) for a persisting swelling in the neck, together with stomach ache, vomiting and anorexia. On physical examination she appeared well but had a pharyngitis and several enlarged and tender cervical lymph nodes. Her laboratory results showed signs of severe inflammation (leukocytes  $16.5 \times 10^9/L$ , CRP 195 mg/L, ferritin 659  $\mu\text{g/L}$ ) and elevated cardiac enzymes (HsTropT 152 ng/L, NT-pro-BNP not performed). The girl was admitted to the hospital and her antibiotic regimen was switched to amoxicillin-clavulanic acid IV (100 mg/kg/day). She was tested positive for SARS-CoV-2 on PCR on admission and antibodies came back positive the next day.

During observation the abdominal complaints worsened and vomiting persisted. Her abdomen was tender. An abdominal ultrasound showed signs of cholecystitis as well as enteritis and free intraperitoneal fluid. An echocardiography showed signs of a mild myopericarditis without coronary involvement. The girl received a one-time dose of IVIG (2 g/kg). Additionally, she was started on acetylsalicylic acid (4 mg/kg/day) as preventive antithrombotic therapy, and lisinopril (2.5 mg/day) was started to reduce cardiac afterload. For the abdominal symptoms she was started on pan-

toprazole IV (40 mg once daily) and ondansetron IV when necessary (0.1 mg/kg/dose). Over the next few days, the clinical situation stabilised, oral intake resumed and symptoms improved gradually. She was discharged after eleven days. She remained complaint-free at follow-up up to a month after discharge; the echocardiographic findings were normalised seven days after discharge.

The fourth case concerned a boy, seven years of age, who presented to the emergency department with fever for the last five days, abdominal pain, vomiting and diarrhoea. On examination he seemed uncomfortable due to pain, had a generally tender abdomen, bilateral non-purulent conjunctivitis and enlarged tonsils with white exudate. He had elevated inflammatory laboratory parameters (leukocytes  $11.1 \times 10^9/L$ , CRP 191.8 mg/L), acute kidney injury presumably secondary to hypoperfusion (creatinine 2.26 mg/dL (reference 0.29-0.47), urea 105.4 mg/dL (reference 15-36 mg/dL)), showed a mildly elevated HsTropT level of 36 ng/L and had positive SARS-CoV-2 antibodies. The patient was treated with IVIG (2 g/kg), acetylsalicylic acid (24 mg/kg/day) and IV cefotaxime (100 mg/kg/day). The acute kidney injury resolved quickly after fluid substitution.

A throat swab tested positive for *Streptococcus pyogenes*, sensitive to penicillin. Haemocultures remained negative. Antibiotics were switched to oral amoxicillin-clavulanic acid (50 mg/kg/day) to treat this infection and cover possible other microbiological pathogens. After the initiation of treatment for MIS-C the clinical picture improved rapidly. He was discharged after six days of admission, fully recovered from his physical complaints. He was still complaint-free at follow-up at ten days and one month after discharge.

The last patient was a 6-year-old boy, who presented to the emergency room because of malaise, fever, throat pain, vomiting, diarrhoea, anorexia, myalgia, headache and itching of the feet for the last five days. He was alert, but groaned and shivered, and looked pale. His lips were crackled, he had a raspberry tongue and a red throat with enlarged tonsils. A warm, erythematous rash was apparent, predominantly on his neck, palms and soles. Laboratory testing showed elevated inflammatory markers (CRP 177.3 mg/L, ferritin 975  $\mu\text{g/L}$ , no leucocytosis), acute kidney injury (creatinine 2.26 mg/dL, urea 105.4 mg/dL), thrombocytopenia ( $36 \times 10^9/L$ ), and an elevated HsTropT level of 59.6 ng/L. Initially he was given an intravenous fluid bolus NaCl 0.9% (10 mg/kg) and IV cefotaxime (100 mg/kg/day) was administered. After a positive result for SARS-CoV-2 antibodies, treatment for MIS-C was started with IVIG (2 g/kg), during which the rash expanded and an additional swelling of the right side of the face appeared.

Despite the IVIG administration the clinical situation worsened, with development of tachycardia (130 beats/min), hypotension (79/39 mmHg) and poor peripheral circulation. Therefore, it was decided to transfer him to the PICU (Paola Children's Hospital Antwerp, Belgium). A cardiac ultrasound was performed and showed minimal mitral valve insufficiency, without further signs of myocarditis or the presence of coronary aneurysms. The patient was given an IV fluid bolus NaCl 0.9% (10 mL/kg) and he was started on IV dobutamine (5  $\mu\text{g/kg/min}$ ) to support the cardiac function. Additional treatment for MIS-C was initiated with IV methylprednisolone (2 mg/kg/day) and acetylsalicylic acid (2 mg/day). With this treatment there was a positive evolution of the clinical condition. Dopamine infusion could be stopped after three days, and the patient was transferred back to the paediatric ward after five days. Three days later he was discharged from the hospital. Unfortunately, he was subsequently lost to follow-up, but informal (phone) follow up revealed no further complaints.

## Discussion

Our case series described five cases of MIS-C patients with various presentations. Diagnosis was based on the definition set by the WHO with the presence of fever, multisystem organ involvement, positive SARS-CoV-2 PCR-test, antigen test or antibodies and laboratory evidence of inflammation. All our patients had a favourable evolution and outcome after treatment with IVIG, with or without the addition of corticosteroids. Only two of our patients showed signs of shock and required intensive care treatment.

Three patients showed cardiac complications on echocardiography, of which one had coronaritis, one myopericarditis and another one mitral valve insufficiency (Table 1). At follow-up all our patients reported full recovery, no recurrence of complaints or new complications.

The initial presentation and working diagnosis of our patients varied widely: sigmoiditis (case 1), appendicitis (case 2), cholecystitis with lymphadenitis colli (case 3), abdominal complaints and conjunctivitis (case 4) and strawberry tongue and rash (case 5). This varied presentation matched the numerous ways of presentation reported in other case reports and articles (1,8,9,13-17). The WHO and Belgian Institute of Health each drew up a classification system for presentation of MIS-C as guidance grouping them in presentation as a Kawasaki-like syndrome, as a non-specific presentation mostly including abdominal symptoms or as signs of cardiac dysfunction with or without shock (4,13,15,18). All the same, diagnosing MIS-C remains challenging, because of this high variety and severity of possible symptoms at presentation (13,15).

Our three patients presenting with predominantly abdominal complaints all showed signs of inflammation on ultrasound like intestinal wall thickening, reactive lymph nodes and free fluid. Many other reported MIS-C patients had signs of intra-abdominal inflammation on different types of imaging as well. Reports by Hameed *et al.* and Morparia *et al.* showed that almost all patients with abdominal complaints who underwent abdominal imaging had abnormalities (19,20). On ultrasound this included predominantly anechoic free fluid, localised inflammatory changes and wall thickening of the bowel (including the right fossa) or gallbladder and mildly enlarged lymph nodes, which was also the case in our cases 1-3. In most of the cases the appendix itself appeared normal. All seven patients described by Morparia *et al.* had hepatomegaly while this was not present in any of our patients and was only sporadically seen by Hameed *et al.*. The combination of the abdominal symptoms and abnormal radiological findings resemble surgical emergencies and thus poses a therapeutic dilemma (21,22). A SARS-CoV-2 antibody and/or PCR test screening for (recent) contact with the virus could help differentiate and prevent unnecessary surgical interventions. Alternatively, a diagnosis of MIS-C should not exclude the presence of other causes of abdominal pain. Lishman *et al.* described three patients with MIS-C who also had a surgically confirmed diagnosis of appendicitis. They suggested that a SARS-CoV-2 infection could facilitate the onset of an appendicitis (23).

Patients 4 and 5 of this series showed signs of KD with conjunctivitis, lymphadenopathy, cracked lips, pharyngitis and a macular rash on neck, hands and feet. Since these patients did not present four out of the five criteria they should be defined as incomplete KD rather than complete KD. MIS-C was first described as a Kawasaki-like disease linked to SARS-CoV-2 (16,24). Since then, many other cases of MIS-C patients with Kawasaki-like symptoms have been described (8,9,17,25,26). However, there are some differences between MIS-C and KD. Compared to complete Kawasaki disease patients affected by MIS-C were generally older and were rather of Black or Hispanic origin instead of Asian origin (8,9). Presentation more often involved abdominal complaints and patients more frequently developed myocardial dysfunction and shock (9). They had different laboratory findings, like a higher white blood cell and neutrophil count, higher levels of inflammatory parameters, more profound anaemia and thrombocytopenia, and a higher elevation of cardiac enzyme levels (8).

The fact that the throat swab from our fourth patient was found positive for *Streptococcus pyogenes* might lead to the assumption that this was no case of MIS-C. The definition set by the WHO clearly states that no other explanation for the symptoms of a patient should be found. However, the proven bacterial infection in his throat was not sufficient evidence for the symptoms this boy presented with. *Streptococcus pyogenes* is thought to sporadically cause an incomplete form of KD, but only in cases of severe

invasive bacterial illness. The fact that our patient did not show such illness, that he was found to be positive for SARS-CoV-2, and that he reacted to treatment with IVIG, led to the assumption that he suffered indeed from MIS-C.

Since the symptoms and imaging results seemed nonspecific, distinguishing laboratory parameters would be useful. In general, CRP, procalcitonin, ferritin, LDH and D-dimer levels were higher in MIS-C patients compared to non-MIS-C patients (1,15). Additionally, alanine aminotransferase (ALT) elevations and raised HsTropT and NT-proBNP levels, suggesting cardiac involvement, were more frequently seen and were generally higher in MIS-C than in a non-MIS-C population with similar presenting symptoms (1,15). In practice however, there is still no cut-off of one parameter that can result in a diagnosis and combination of these parameters remains necessary. Kelly *et al.* proposed the following as the best cut-off values: CRP 119.6 mg/L, procalcitonin 0.215 ng/mL, ferritin 122 ng/L, D-dimer 924 ng/mL, ALT 25 IU/L, HsTropT 16 ng/L, NT-proBNP 212 pg/mL (15). In our patient population, the blood levels of CRP, ferritin D-dimers and HsTropT met these criteria. ALT elevation above 25 IU/L was only present in two of our patients. Procalcitonin was not determined in our cases. No significant differences in laboratory results between patients with a Kawasaki-like presentation versus those with a non-specific presentation were found, but patients presenting with shock did have significantly higher neutrophil counts and levels of CRP, ferritin, D-dimer, HsTropT and NT-proBNP and lower platelet and albumin levels (8, 27).

We noted that only one of our patients was of European descent. The parents of our cases were born in respectively West Africa (2), Morocco, Suriname and Poland. Multiple retrospective studies have shown patients of African or Hispanic ethnicity to be overrepresented in the MIS-C population compared to what would be expected from population statistics (8, 26–29). The exact aetiology remains elusive, but several reasons have been proposed. There could be a genetic predisposition linked to the ApoE4 genotype as suggested by Goldstein *et al.* (30). Different social determinants including housing and economic instability in patients from foreign origin might also explain this difference. This was stated as a probable cause in adults, since these populations are also overrepresented in the incidence of severe SARS-CoV-2 infections and hospitalisations (28). However, this speculation is solely based on European, Asian and American studies, as incidence data from either African or South American studies on MIS-C are scarce. If origin would play a role in the chance to develop MIS-C, it would explain our high number of patients from foreign background.

To date we only saw a series of cases in our hospital presenting over a period of two months' time, weeks after the second wave of SARS-CoV-2 infections in Belgium. We wonder why we did not see patients after the peak of the first and the third waves, which have passed for months now. Enquire with colleagues from other hospitals in the area learned that they also found the same peak in incidence, although no truly reliable data have been produced up till now. The possibility of MIS-C cases being missed during the first and third wave seems not plausible given the severity of the disease. We wondered whether lockdown measures leading to prohibition to go to school and thus having a lower chance to get infected with the virus and developing MIS-C might pose an explanation. However, most patients were being infected with SARS-CoV-2 within their own household, which would contradict this. Maybe the seasonal variation in virulence of SARS-CoV-2 could help explain the difference. Specific SARS-CoV-2 strains might increase the risk of developing MIS-C compared to other strains. But up till now, no data about this topic are provided by literature. Hypothetically, because of the similarity with Kawasaki disease which presence and incidence has been associated with tropospheric wind patterns, we also wondered whether an analogous system or other environmental factors could explain our burst of patients (31). Unfortunately, no studies of this type have been performed. We could not find any explanation concerning the link between MIS-C and environmental factors.

## Conclusions

By presenting these cases, we aimed to highlight that MIS-C can present through a variety of symptoms that can generally be divided into three groups that have been stated in recent literature: Kawasaki-like; with non-specific (mostly abdominal) symptoms; and with shock and cardiac dysfunction. Because of this variety in symptomatology, it is paramount to search for clues of MIS-C through diagnostic tests, even in patients with less specific complaints. Research is needed to substantiate current guidelines.

The majority of our patients was of non-European descent, as seen in many other reports. Reasons for this are not yet known and should be sought for in future research. It remains remarkable that a peak in incidence in our hospital was only seen after the second wave of SARS-CoV-2 infections in Belgium. A conclusive explanation for this fact cannot be given with present knowledge and should be investigated in the future. Possible links between developing MIS-C and the variability in virulence caused by season or different SARS-CoV-2 strains might be interesting to analyse.

## Acknowledgments

The authors gratefully acknowledge the contribution of the nurses and the clerical staff working at ZNA Hospitals, Antwerp, Belgium.

## Competing interests

The authors declare that they have no competing interests.

## REFERENCES:

1. Radia T, Williams N, Agrawal P, Harman K, Weale J, Cook J, et al. Multi-system inflammatory syndrome in children & adolescents (MIS-C): A systematic review of clinical features and presentation. *Paediatr Respir Rev*. 2021;38:51–7.
2. Kaushik A, Gupta S, Sood M, Sharma S, Verma S. A systematic review of multisystem inflammatory syndrome in children associated with SARS-CoV-2 infection. *Pediatr Infect Dis J*. 2020;39(11):E340–6.
3. Royal College of Paediatrics and Child Health. Guidance paediatric multisystem inflammatory syndrome temporally associated with Covid-19. [Internet]. 2020 [cited 2021 June 23]. Available from: <https://www.rcpch.ac.uk/sites/default/files/2020-05/COVID-19-Paediatric-multisystem-%20inflammatory%20syndrome-20200501.pdf> .
4. World Health Organization. Multisystem inflammatory syndrome in children and adolescents with COVID-19. [Internet]. 2020 [cited 2021 Jun 23]. Available from: <https://www.who.int/publications/i/item/multisystem-inflammatory-syndrome-in-children-and-adolescents-with-covid-19>.
5. Son MBF, Murray N, Friedman K, Young CC, Newhams MM, Feldstein LR, et al. Multisystem Inflammatory Syndrome in Children - Initial Therapy and Outcomes. *N Engl J Med*. 2021;385(1):23–34.
6. McArdle AJ, Vito O, Patel H, Seaby EG, Shah P, Wilson C, et al. Treatment of Multisystem Inflammatory Syndrome in Children. *N Engl J Med*. 2021;385(1):11–22.
7. Davies P, Evans C, Kanthimathinathan HK, Lillie J, Brierley J, Waters G, et al. Intensive care admissions of children with paediatric inflammatory multisystem syndrome temporally associated with SARS-CoV-2 (PIMS-TS) in the UK: a multicentre observational study. *Lancet Child Adolesc Health*. 2020;4:669–77.
8. Whittaker E, Bamford A, Kenny J, Kaforou M, Jones CE, Shah P, et al. Clinical Characteristics of 58 Children with a Pediatric Inflammatory Multisystem Syndrome Temporally Associated with SARS-CoV-2. *JAMA - J Am Med Assoc*. 2020;324(3):259–69.
9. Feldstein LR, Rose EB, Horwitz SM, Collins JP, Newhams MM, Son MBF, et al. Multisystem Inflammatory Syndrome in U.S. Children and Adolescents. *N Engl J Med*. 2020;383(4):334–46.
10. Capone CA, Misra N, Ganigara M, Epstein S, Rajan S, Acharya SS, et al. Six Month Follow-up of Patients With Multi-System Inflammatory Syndrome in Children. *Pediatrics*. 2021;148(4):e2021050973.
11. Davies P, Du Pré P, Lillie J, Kanthimathinathan HK. One-Year Outcomes of Critical Care Patients Post-COVID-19 Multisystem Inflammatory Syndrome in Children. *JAMA Pediatr*. August 30, 2021. doi:10.1001/jamapediatrics.2021.2993.
12. Jonat B, Gorelik M, Boneparth A, Geneslaw AS, Zachariah P, Shah A, et al. Multisystem Inflammatory Syndrome in Children Associated with Coronavirus Disease 2019 in a Children's Hospital in New York City: Patient Characteristics and an Institutional Protocol for Evaluation, Management, and Follow-Up. *Pediatr Crit Care Med*. 2021;22(3):E178–91.
13. Zou H, Lu J, Liu J, Wong JH, yuen, Cheng S, Li Q, et al. Characteristics of pediatric multi-system inflammatory syndrome (PMIS) associated with COVID-19: a meta-analysis and insights into pathogenesis. *Int J Infect Dis*. 2021;102:319–26.
14. Antúnez-Montes OY, Escamilla MI, Figueroa-Urbe AF, Arteaga-Menchaca E, Lavariega-Saráchaga M, Salcedo-Lozada P, et al. COVID-19 and Multisystem Inflammatory Syndrome in Latin American Children: A Multinational Study. *Pediatr Infect Dis J*. 2020;40(1):1–6.
15. Kelly MS, Fernandes ND, Carr A V., Lahoud-Rahme M, Cummings BM, Chiu JS. Distinguishing Features of Patients Evaluated for Multisystem Inflammatory Syndrome in Children. *Pediatr Emerg Care*. 2021;37(3):179–84.
16. Riphagen S, Gomez X, Gonzalez-Martinez C, Wilkinson N, Theocharis P. Hyperinflammatory shock in children during COVID-19 pandemic. *Lancet*. 2020;395(10237):1607–8.
17. DeBiasi RL, Song X, Anusinha E, Smith KL, Bell M, Pershad J, et al. Severe COVID-19 in Children and Young Adults in the Washington DC Metropolitan Region. *J Pediatr*. 2020;223:199–203.e1..
18. Delvaux N, Cavatorta E, Gilliaux O, Marechal Y. Opvang en behandeling van kinderen met COVID-19 gerelateerde ziekte [Internet]. Brussels: Sciensano. 2021 [cited 2021 June 23] Available from: [https://covid-19.sciensano.be/sites/default/files/Covid19/Guideline%20behandeling%20COVID%20kinderen\\_0.pdf](https://covid-19.sciensano.be/sites/default/files/Covid19/Guideline%20behandeling%20COVID%20kinderen_0.pdf) .
19. Hameed S, Elbaaly H, Reid CEL, Santos RMF, Shivamurthy V, Wong J, et al. Spectrum of imaging findings at chest radiography, US, CT, and MRI in multisystem inflammatory syndrome in children associated with COVID-19. *Radiology*. 2020;298(1):E1–10.
20. Morparia K, Park MJ, Kalyanaraman M, McQueen D, Bergel M, Phatak T. Abdominal Imaging Findings in Critically Ill Children with Multisystem Inflammatory Syndrome Associated with COVID-19. *Pediatr Infect Dis J*. 2021;40(2):E82–3.
21. Gerall CD, Duron VP, Griggs CL, Kabagambe SK, Maddocks AB, DeFazio JR. Multisystem Inflammatory Syndrome in Children Mimicking Surgical Pathologies: What Surgeons Need to Know about MIS-C. *Ann Surg*. 2021;273(4):e146–8.
22. Valitutti F, Verde A, Pepe A, Sorrentino E, Veneruso D, Ranucci G, et al. Multisystem inflammatory syndrome in children. An emerging clinical challenge for pediatric surgeons in the COVID 19 era. *J Pediatr Surg Case Reports*. 2021;69(January):101838.
23. Lishman J, Kohler C, De Vos C, Van Der Zalm MM, Itana J, Redfern A, et al. Acute Appendicitis in Multisystem Inflammatory Syndrome in Children with COVID-19. *Pediatr Infect Dis J*. 2020;39(12):E472–3.
24. Jones VG, Mills M, Suarez D, Hogan CA, Yeh D, Bradley Segal J, et al. COVID-19 and Kawasaki Disease: Novel Virus and Novel Case. *Hosp Pediatr*. 2020;10(6):537–40.
25. Davies P, Evans C, Kanthimathinathan HK, Lillie J, Brierley J, Waters G, et al. Intensive care admissions of children with paediatric inflammatory multisystem syndrome temporally associated with SARS-CoV-2 (PIMS-TS) in the UK: a multicentre observational study. *Lancet Child Adolesc Health*. 2020;

26. Toubiana J, Poirault C, Corsia A, Bajolle F, Fourgeaud J, Angoulvant F, et al. Kawasaki-like multisystem inflammatory syndrome in children during the covid-19 pandemic in Paris, France: prospective observational study. *BMJ*. 2020;369:m2094.
27. Bautista-Rodriguez C, Sanchez-De-Toledo J, Clark BC, Herberg J, Bajolle F, Randanne PC, et al. Multisystem inflammatory syndrome in children: An international survey. *Pediatrics*. 2021;147(2):e202002245554.
28. Godfred-Cato S, Bryant B, Leung J, Oster ME, Conklin L, Abrams J. COVID-19–Related Multisystem Inflammatory Syndrome in Children. *MMWR*. 2020;69(32):1074–80.
29. Lee EH, Kepler KL, Geevarughese A, Paneth-Pollak R, Dorsinville MS, Ngai S, et al. Race/Ethnicity Among Children With COVID-19-Associated Multisystem Inflammatory Syndrome. *JAMA Netw open*. 2020;3(11):e2030280.
30. Goldstein MR, Poland GA, Graeber CW. Coronavirus disease 2019, multisystem inflammatory syndrome in children, apolipoprotein E4, and race. *J Pediatr*. 2021;229:313-14.
31. Rodó X, Ballester J, Cayán D, Melish ME, Nakamura Y, Uehara R, et al. Association of Kawasaki disease with tropospheric wind patterns. *Sci Rep*. 2011;1:152.

**Table 1 :** Modified Samat scoring system. Predominant clinical features in stage 2 and/or stage 3 are an indication to start with therapeutic hypothermia. From Samat et al. Samat grading scale for neonatal encephalopathy after 45 years: an update proposal (8). With permission from Elsevier.

Characteristics	Patient 1	Patient 2	Patient 3	Patient 4	Patient 5
<b>Sex</b>	Female	Male	Female	Male	Male
<b>Age (years)</b>	15	10	10	7	6
<b>Fever &gt; 3 days</b>	2 days monitored, report of 3	yes	2 days monitored, report of 5	yes	Yes
<b>Symptoms according to WHO</b>	muco-cutaneous inflammation; hypotension; coronaritis; elevated HsTropT and NT-proBNP; coagulopathy; abdominal pain	elevated HsTropT and NT-proBNP; coagulopathy; abdominal pain; diarrhoea	myo-pericarditis; elevated HsTropT; coagulopathy; abdominal pain; vomiting	bilateral conjunctivitis; elevated HsTropT; coagulopathy; abdominal pain; vomiting	rash; mucocutaneous inflammation hypotension (shock); mitral valve insufficiency; elevated NT-proBNP; coagulopathy; vomiting and diarrhoea
<b>Elevated inflammatory markers</b>	yes	yes	yes	yes	yes
<b>Other cause of inflammation</b>	no	no	no	<i>S. pyogenes</i> tonsillitis	no
<b>Evidence of SARS-COV-2 infection</b>	Ab positive, PCR positive	Ab positive, PCR positive	Ab positive, PCR positive	Ab positive, PCR negative	Ab positive, PCR negative
<b>Therapy*</b>	Amoxicillin-clavulanic acid; piperacilline-tazobactam; IVIG; acetylsalicylic acid; methyl-prednisolone; inotropics	Cefotaxime IV; IVIG; enoxaparine SC; furosemide IV; tube feeding	Amoxicillin-clavulanic acid; IVIG; pantoprazole; ondansetron; acetylsalicylic acid; lisinopril	Cefotaxime IV; IVIG; acetylsalicylic acid; pantoprazole; Vitamin D	Cefotaxime IV; IVIG; dobutamine; acetylsalicylic acid; methyl-prednisolone; esomeprazole;
<b>PICU admission</b>	yes	no	no	no	yes

\* Every patient received pain relief and antipyretics on demand and IV fluids depending on oral fluid intake

**HsTropT:** high-sensitivity troponin T; **IV:** intravenous; **IVIG:** intravenous immunoglobulins; **MIS-C:** Multisystem Inflammatory Syndrome in Children and adolescents; **NT-proBNP:** N-terminal pro-brain-type natriuretic peptide; **PICU:** paediatric intensive care unit; **SARS-CoV-2:** severe acute respiratory syndrome coronavirus 2; **SC:** subcutaneous; **WHO:** World Health Organisation

## Case Report

# Vacuum delivery: 2 cases of subgaleal haemorrhage

Manon Rosimont<sup>a</sup>, Sophie Tribolet<sup>b</sup>, Nadège Hennuy<sup>b</sup>, Renaut VIELLEVOYE<sup>b</sup>, Laetitia Rauw<sup>c</sup>, Philippe Petit<sup>c</sup>, Vincent Rigo<sup>b</sup>

<sup>a</sup> Department of Pediatrics, University Hospital Liège & University of Liège, Belgium.

<sup>b</sup> Department of Neonatology, University Hospital Liège & University of Liège, Belgium

<sup>c</sup> Department of Gynecology, Citadelle Hospital Liège, Belgium

mrosimont@student.ulg.ac.be

## Keywords

subgaleal hemorrhage, neonatal hypovolemic shock, vacuum delivery

## Abstract

Subgaleal haemorrhage (SGH) is a rare complication of vacuum delivery. Although SGH can rapidly be life-threatening, its symptoms are initially confused with both common and benign cephalohematoma or caput succedaneum. Cardiovascular compromise lead to systemic difference in presentation: alterations in colour, heart rate and general condition. Vital parameters are important clues to improve diagnosis after instrumental delivery.

The diagnosis of SGH remains clinical: important swelling of the scalp that accumulates in the declive areas, pallor, tachycardia, irritability, convulsions or hypotonia are the main signs. No further investigation is necessary before urgent therapy. Management consists of rapid correction of hypovolemia with saline and/or red blood cell transfusions.

Early initiation of treatment is associated with better outcomes but further follow-up studies are needed to better describe the uncertain prognosis.

We report two cases of subgaleal haemorrhages following vacuum-assisted deliveries. In both cases, the initial presentation was severe, with hypovolemic shock and coagulopathy. Early diagnosis and intensive treatment resulted in a favourable outcome.

## Introduction

Subgaleal haemorrhage (SGH) leads to the accumulation of blood in the unrestricted space between the subgaleal fascia and the skull. It can be a serious, life-threatening complication of childbirth. Its associations with instrumental delivery or coagulopathy is well known. However, some cases occur during delivery without instruments and without coagulopathy. The severity is variable and can range from a small swelling of the scalp to a massive haemorrhage leading to hypovolemic shock and disseminated intravascular coagulopathy.

We report two cases of SGH associated with vacuum-assisted deliveries. In both cases, the initial presentation was severe but early diagnosis and intensive treatment resulted in a favourable outcome.

The aim of this article is to highlight the clinical features leading to the diagnosis and suggest guidelines for management. The importance of early recognition and the need for careful monitoring in instrumented deliveries will be emphasized.

### Clinical cases

We report 2 similar clinical cases. Both neonates were male, born at term at 40 weeks with respective weights of 3515 g and 3600 g.

In the first baby, delivery was induced after prolonged rupture of the amniotic membranes. Vacuum instrumentation was indicated for foetal malrotation and was complicated by several instrument disengagements. For the second baby, labour was spontaneous. After several unsuccessful pushing efforts, vacuum instrumentation was performed without success (4 pop-offs). The baby was finally born by emergency caesarean section for an altered foetal heart rate.

In both cases, the babies were born pale, hypotonic, apnoeic and bradycardic. Mask ventilation allowed an increase in heart rate and recovery of spontaneous breathing.

However, patients remained pale, hypotonic and became tachycardic (>180/min) with increasing head circumference and increasingly prominent front. SGH was rapidly suspected in both patients. Their management was similar

but with a longer timing in the 2nd baby who was outborn. Both received NaCl 0.9% for volume expansion and vitamin K for prevention of haemorrhagic disease of the newborn.

In the 1st case, blood analysis at 30 minutes of life showed lactic acidosis (pH 7.24 – pCO<sub>2</sub> 24 mmHg – EB -15 mEq/l - lactates 103 mg/dL), haemoglobin 15 g/dl (N 16.5-20), platelets 162000/mm<sup>3</sup> (N 175000-500000) and a coagulation disorder (Quick 34% (N 70-100%) - aPTT ratio 1.3 (N <1.2) - fibrinogen 1.4 g/L (N 1.0-1.2)). There was no clinical evidence of hypoxic ischemic encephalopathy (HIE). The head circumference continued to increase due to persistent bleeding. The disseminated intravascular coagulation prompted the administration of a single dose (50 IU/kg) of human prothrombin complex (Cofact®), a combination of factors II, VII, IX, X and proteins C and S. This was associated with clinical improvement and a normalisation of coagulation factors. The cerebral ultrasound was normal, with no sign of intracranial haemorrhage. The infant was discharged from hospital at 7 days of age and his neurological evolution was satisfactory.

In the second case, pH at 30 minutes of life revealed a severe acidosis (pH 6.83 – pCO<sub>2</sub> 103 mmHg – EB -19,2 mmHg - lactates 144 mg/dl). The child also had a coagulopathy which was rapidly corrected after a transfusion of fresh frozen plasma. Neurological examination revealed a moderate encephalopathy (Thompson score of 8), confirmed by a discontinuous normal voltage pattern on amplitude-integrated electroencephalography. Therapeutic hypothermia was initiated at 5 hours of life, once the haemorrhage and coagulopathy were controlled. Cerebral MRI at 1 week of age demonstrated a collection of subgaleal blood without intracranial haemorrhage or anoxic-ischemic lesions. The early evolution was good with normalization of both clinical neurological examination and electroencephalogram.

## Discussion

*Pathophysiology:* The scalp is composed of five layers: the skin; the dense connective tissue; the epicranial fascia, a tough fibrous layer; the loose connective tissue and finally the dense periosteum. The subgaleal space lies be-

**Table 1 :** Comparison of the different swelling on the head in neonatal period

	Subgaleal hematoma	Cephalhematoma	Caput succedaneum
<b>Physiopathology and anatomy</b>	Blood accumulation from rupture of emissary veins in unlimited space between epicranial aponeurosis and periosteum	Blood accumulation from rupture of diploic veins in limited space between the skull and the periosteum	Collection of serosanguinous fluid between epicranial aponeurosis and skin.
<b>Location</b>	Diffuse and extended (nuchal ridge, orbital margins, beside the ears)	Usually over parietal bones	At point of contact Subcutaneous
<b>Extension</b>	Posteriorly to nuchal ridge (declive), laterally to temporal fascia, and anteriorly to the orbital margins, ACROSS sutures lines	Limited by the margins of bones and does NOT cross the suture lines	Can extend ACROSS sutures lines
<b>Clinical signs</b>	- Diffuse and boggy swelling - Hypovolemic and acidosis signs: pallor, respiratory distress, tachycardia, seizure	- Circle swelling with palpable and limited contour	- Diffuse and boggy swelling - Pitting edema, shift with gravity
<b>Volume</b>	Not limited – accumulation up to 260 ml	Rarely severe	20-40ml
<b>Timing</b>	Rapid onset, at birth, but growth mean 1-6h after birth but sometimes symptoms after 1 day.	Growth during 12-24h after birth	Maximal at birth
<b>Management</b>	1) Hemodynamic troubles: - NaCl 0,9% (10-20cc/kg) - Red blood cells transfusion 2) Correction of coagulopathy and DIC. 3) Global support according to related organ diseases.  Resolution over 2-3 weeks	Spontaneous resolution over 2 to 3 weeks	Spontaneous rapid resolution in 48-72h
<b>Complications and associations</b>	<u>Acute complications:</u> - Shock - Disseminated intravascular coagulation - Multiple organ failure - Death <u>Medium term complications:</u> - Jaundice - Anemia <u>Long term complications</u> - Cerebral Palsy - epilepsy	- Jaundice - Anemia	- Jaundice - Anemia

tween the periosteum and the epicranial fascia and is bounded from front to back only by the frontal muscle and the posterior nuchal lines and laterally by the temporal muscles (1,2). These features reduce the possibility of anatomical tamponade and allow for an accumulation of blood up to 260 ml in the case of SGH (1,3). SGH is life-threatening and so, early differential diagnosis with cephalohematoma or caput succedaneum is therefore crucial. Table 1 summarizes the characteristics of those three types of cephalic collections. With SGH, each increase of one centimetre in head circumference seems to indicate a 40 ml haemorrhage (1,2,8). This explains the high prevalence of hypovolemic shock, as the circulating blood volume is approximately 80-90 ml/kg in newborns.

**Epidemiology and risk factors:** SGH is a rare postnatal complication. The incidence is approximately 1/2500 live births, with a male predominance (2,4,5). The mortality rate is as high as 15% in some studies<sup>3</sup>.

External forces during delivery, particularly traction and rotation, can cause rupture of the outflow veins in the subgaleal space. This explain why instrumental deliveries are associated with an increased incidence of SGH up to 1/250, with vacuum extraction being a greater risk than forceps (1,2,4,6). The most important risk factors for vacuum failure are malrotation of the foetus, higher birth weight, small maternal size, nulliparity and induction of labour (7,8). Other risk factors for SGH are controversial: the number of vacuum disengagements, vacuum use for more than 20 minutes, vacuum application over the sagittal sutures or too close to the anterior fontanel, and prolongation of the second stage of labour (duration of active pushing from full dilation) above 120 minutes (4,8,9).

Clinical presentations of SGH range from limited scalp swelling to severe blood loss complicated by hypovolemic shock and coagulopathy (1). SGH in

uninstrumented vaginal delivery appears to be less severe and requires a lower rate of blood transfusion (10).

**Diagnosis and further investigations:** The diagnosis is based primarily on clinical presentation. An early diagnosis allows urgent and appropriate management.

In babies born without instrumentation and presenting with SGH, coagulation disorders such as vitamin K deficiency or haemophilia should be investigated (3,5).

In the case of instrumental delivery, careful observation of the newborn should focus on head circumference, heart rate, tone and colour (1,2,6,12,13). Shock can appear in the minutes after birth. The average onset of symptoms is 1 to 6 hours, but they can still appear up to 2 days after birth (1). In units with early screening, the mortality rate has decreased from 15% to 2.8% (8).

**Treatment:** The management is based on circulatory stabilisation through restoration of blood volume and correction of coagulopathy. Ventilatory, inotropic or vasopressor support should be used if necessary. Correction of hypovolemia is the mainstay of treatment, starting with boluses of normal saline and/or red blood cells. Early blood transfusion may stop the progression of bleeding (8,14). Head banding increases intracerebral pressure, leading to head trauma or cerebral oedema, and is not recommended. Surgery has been performed previously but does not appear to be helpful (1,4,10,15,16).

Aggressive and rapid correction of the coagulopathy (INR threshold 1.5) with fresh frozen plasma (10-20 ml/kg) in the first instance is considered important to avoid disseminated intravascular coagulation (8,17). Without a clear correlation between the severity of thrombocytopenia and the risk of bleeding, the thresholds for platelet transfusion remain unclear (17). Despite its

high efficacy the administration of recombinant activated factor (especially VII), as in our first patient, is controversial given a potential increase in thromboembolic risk (4,16,17).

Finally, after stabilisation, attention should be paid to hyperbilirubinemia resulting from hematoma resorption. Prolonged and intense phototherapy can be necessary (1).

Therapeutic hypothermia in active haemorrhage remains controversial as it can be associated with thrombocytopenia and hypotension and therefore could potentially increase the risk of intracranial haemorrhage (ICH) (18,19). These potential side effects must be weighed against the demonstrated benefits of hypothermia in HIE in reducing deaths and improving neurological outcomes in survivors.

Early diagnosis and prompt initiation of treatment have been associated with better outcomes, as in our patients.

SGH is a severe disease, with a high incidence of mortality (between 5 and 14%) and adverse outcomes (1-3,5,10,14). Neurological sequelae resulting from cerebral ischemia include seizures, neurodevelopmental delay and cerebral palsy (1,5,20). Factors associated with poor outcome include anaemia, coagulopathy, metabolic acidosis, renal failure, hypotension and seizures (15).

## Conclusion

SGH is a rare but severe cause of neonatal morbidity and mortality. Haemorrhage into an unrestricted space can rapidly lead to hypovolemic shock. The management of SGH includes volume expansion and hemodynamic support, correction of coagulation disorders and management of neurological and other organ involvements. Identification of risk factors, early diagnosis, close observation and prompt treatment are all important to avoid rapid deterioration. Instrumental delivery should not be considered routine and warrants careful monitoring of the newborn.

## Conflict of interest

No potential conflicts of interest in relation to this article have been reported.

## REFERENCES:

1. Colditz MJ, Lai MM, Cartwright DW, Colditz PB. Subgaleal haemorrhage in the newborn: A call for early diagnosis and aggressive management. *J Paediatr Child Health*. 2015;51(2):140-146.
2. Schierholz E, Walker SR. Responding to traumatic birth: subgaleal hemorrhage, assessment, and management during transport. *Adv Neonatal Care*. 2014;14(6):S11-S15.
3. Lee SJ, Kim JK, Kim SJ. The clinical characteristics and prognosis of subgaleal hemorrhage in newborn. *Korean J Pediatr*. 2018;61(12):387-391.
4. Swanson AE, Veldman A, Wallace EM, Malhotra A. Subgaleal hemorrhage: Risk factors and outcomes. *Acta Obstet Gynecol Scand*. 2012;91(2):260-263.
5. El-Dib M, Parziale MP, Johnson L, Benson CB, Grant E, Robinson J, et al. Encephalopathy in neonates with subgaleal hemorrhage is a key predictor of outcome. *Pediatr Res*. 2019;86(2):234-241.
6. Boumahni B, Ghazouani J, Bey KJ, Carbonnier M, Staquet P. [Subgaleal hematoma in 2 neonates]. *Arch Pediatr*. 2010;17(10):1451-1454.
7. Ahlberg M, Norman M, Hjelmstedt A, Ekéus C. Risk factors for failed vacuum extraction and associated complications in term newborn infants: a population-based cohort study. *J Matern Fetal Neonatal Med*. 2016;29(10):1646-1651.
8. Boo NY, Foong KW, Mahdy ZA, Yong SC, Jaafar R. Risk factors associated with subaponeurotic haemorrhage in full-term infants exposed to vacuum extraction. *BJOG An Int J Obstet Gynaecol*. 2005;112(11):1516-1521.
9. Ghidini A, Stewart D, Pezzullo JC, Locatelli A. Neonatal complications in vacuum-assisted vaginal delivery: are they associated with number of pulls, cup detachments, and duration of vacuum application? *Arch Gynecol Obstet*. 2017;295(1):67-73.
10. Christensen RD, Baer VL HE. Neonatal subgaleal hemorrhage in a multihospital healthcare system : prevalence, associations and outcomes. *EJ Neonatol Res*. 2011;1(1):4-11.

11. Radovanović T, Spasojević S, Stojanović V, Doronjski A. Severe neonatal subgaleal hemorrhage as the first presentation of hemophilia A. *Srp Arh Celok Lek*. 2016; 144(3-4):204-206.
12. Assad M, Spaight M, Sink D, Martin J. Early recognition and management of fetal head trauma with massive subgaleal hemorrhage. *J Neonatal Perinatal Med*. 2018;11(4):433-438.
13. Davis DJ. Neonatal subgaleal hemorrhage: diagnosis and management. *CMAJ*. 2001;164(10):1452-1453.
14. Modanlou H, Hutson S, Merritt AT. Early Blood Transfusion and Resolution of Disseminated Intravascular Coagulation Associated with Massive Subgaleal Hemorrhage. *Neonatal Netw*. 2016;35(1):37-41.
15. Chang H-Y, Peng C-C, Kao H-A, Hsu C-H, Hung H-Y, Chang J-H. Neonatal subgaleal hemorrhage: clinical presentation, treatment, and predictors of poor prognosis. *Pediatr Int*. 2007;49(6):903-907.
16. Strauss T, Kenet G, Schushan-Eisen I, Mazkereth R, Kuint J. Rescue recombinant activated factor VII for neonatal subgaleal hemorrhage. *Isr Med Assoc J*. 2009;11(10):639-640.
17. Rajagopal R, Thachil J, Monagle P. Disseminated intravascular coagulation in paediatrics. *Arch Dis Child*. 2017;102(2):187-193.
18. Lakatos A, Kolossváry M, Szabó M, Jemendy A, Barta H, Gyebnar G, et al. Neurodevelopmental effect of intracranial hemorrhage observed in hypoxic ischemic brain injury in hypothermia-treated asphyxiated neonates - an MRI study. *BMC Pediatr*. 2019;19(1):430.
19. Forman KR, Diab Y, Wong ECC, Baumgart S, Luban NLC, Massaro AN. Coagulopathy in newborns with hypoxic ischemic encephalopathy (HIE) treated with therapeutic hypothermia: A retrospective case-control study. *BMC Pediatr*. 2014;14(1):277.
20. Kim KM, Cho SM, Yoon SH, Lim YC, Park MS, Kim MR. Neurodevelopmental Prognostic Factors in 73 Neonates with the Birth Head Injury. *Korean J Neurotrauma*. 2018;14(2):80.



Our  
best   
comfort  
& protection  
for sensitive skin

Our exclusive inner layer pulls  
urine & mess away from skin &  
locks it inside the nappy

*See the difference*



next leading brand



## Case Report

# Pneumococcal endocarditis in a 10-year-old child with Marfan syndrome: case report

Lorna Thienpont<sup>a</sup>, Pauline Van Gyseghem<sup>a</sup>, Christophe Frick<sup>a</sup>, Antoine Bondue<sup>b</sup>, Nicolas Arribard<sup>b</sup>, H el ene Demanet<sup>c</sup>, Chloe Joris<sup>a</sup>, Fran oise Vermeulen<sup>a</sup>, Marine Rodesch<sup>a</sup>

<sup>a</sup> Department of Pediatrics, Erasmus Hospital, ULB, Brussels, Belgium

<sup>b</sup> Department of Cardiology, Erasmus Hospital, ULB, Brussels, Belgium

<sup>c</sup> Department of Cardiovascular surgery, Queen Fabiola Children's University Hospital, Brussels, Belgium

lorna.thienpont@ulb.be

### Keywords

Endocarditis, Streptococcus pneumonia, Children, Marfan syndrome, Case report

### Abstract

Endocarditis is a rare disease in children and is associated with high morbidity and mortality. It must be considered for every child with long-term fever without source, especially if there is a risk factor. Among the germs that can be involved, *Streptococcus pneumoniae* is extremely rare. Streptococcal invasive infections are decreasing since the introduction of vaccination, but all serotypes are not covered.

In this case, we describe a 10-year-old girl affected by Marfan syndrome with pre-existing mitral regurgitation. She was diagnosed with a streptococcal endocarditis. The laboratory identified the strain as *Streptococcus pneumoniae* serotype 13, a non-vaccinal serotype.

### Introduction

Pneumococcal invasive infections have decreased in industrialized countries thanks to the conjugate vaccine. Management of these infections has improved due to prompt diagnosis (improvement in imaging techniques, better and rapid molecular testing) and the correct use of antibiotics (new cutoff minimum inhibitory concentration (MIC)) (1-3).

*Streptococcus pneumoniae* is a very rare cause of endocarditis and accounts for 3-7% of all cases. It is associated with a high mortality rate (3).

### Case report

A 10-year-old girl presented by her parents to the cardiology consultation for fever (maximum 38°C), chills, headache and asthenia for the past 3 days. She was seen the day before by her general practitioner, who prescribed amoxicillin 50mg/kg/day for a suspected sinusitis and received 2 doses.

Among her medical history, she is afflicted by Marfan syndrome (MFS) associated with mitral prolapsus, mild mitral regurgitation and aortic dilatation.

She was seen at the cardiology consultation, where she was followed for the cardiovascular complications of MFS, by her parents initiative. The physical examination was totally normal, especially there was no cardiac murmur. Her vital signs were normal for age. A transthoracic echocardiography was performed and showed an increase of mitral regurgitation, neither a vegetation was seen nor other abnormalities.

Laboratory investigations revealed high inflammatory syndrome: white blood cells 14730/mm<sup>3</sup> (normal range: 5000-10000 WBCs per microliter), polynuclear neutrophils 10850/mm<sup>3</sup> (normal range: 2500-7500 neutrophils per microliter), C-reactive protein 150 mg/L (normal range; < 3.0 mg/L) and high NT-ProBNP 798 pg/mL (normal range: <125 pg/mL) which can be a sign of acute cardiac failure. She was admitted to the pediatric unit and we decided to stop the antibiotics since no source of infection was found. Chest X-ray and urinalysis were normal.

During the hospitalization fever persisted. Blood cultures were taken at each febrile peak. CRP fluctuated but remained high (between 89 and 130 mg/L).

Her vital signs remained normal and she kept an excellent condition. The first 2 days, blood cultures remained negative, on the third day of the therapeutic window rapid growth of *Streptococcus pneumoniae* was observed in 2 blood cultures. She was immediately treated with intravenous amoxicillin clavulanate 100 mg/kg/day for a pneumococcal bacteremia. The blood cultures obtained after that were all negative and the fever quickly dropped.

At first, we concluded that she had an occult pneumococcal bacteremia since the chest X-ray was normal, there were no sign of meningitis, neither sinusitis nor otitis seen by the ENT specialist and the transthoracic echocardiography at admission was normal.

On day 8, the antibiotic therapy was adapted according to the antibiogram, we started amoxicillin 100 mg/kg/day. The same day, a second transthoracic echocardiography performed by her cardiologist to control mitral regurgitation, revealed a soft mass measuring 14x5 mm on the anterior leaflet of the mitral valve (fig 1).

A transesophageal echocardiography then confirmed the endocarditis suspicion and showed a voluminous A3 pericommisural vegetation, valve perforation and a peri-annular abscedation (fig 2).

We increased the doses of amoxicillin to 300mg/kg/day in the context of endocarditis and the patient was referred to a reference center with a pediatric cardiosurgery department for surgical management. She underwent a valvuloplasty on day 10. Unfortunately, peroperative samples were not sent for microbiological analysis. The postoperative recovery was uncomplicated.

She was treated with penicillin 500.000 U/kg/day based on the MIC for 4 weeks after the first negative blood culture.

Other additional investigations did not show any complications: no sign of septic embolization seen on the abdominal ultrasonography or cerebral magnetic resonance imaging.

The bacteriological strain was referred to the national reference laboratory and was identified as serotype 13, a non-vaccinal serotype. The patient was immunized according to the Belgian vaccination schedule applied at that

time, including pneumococcal conjugate vaccine PCV7 at 2 and 4 months and PCV13 (since the vaccine had changed that year) at 12 months.

The echocardiography performed before discharge showed stable mitral regurgitation with preserved function and no vegetation.

## Discussion

Infectious endocarditis (IE) is a rare disease in children. The estimated incidence ranges from 3,3 per 100000 per year among infants < 1 year to 0,3-0,8 per 100000 per year in older children in the United States and 0,5 per 100000 children per year in Norway (4-7). We did not find any numbers in Belgium.

The major risk factors in the pediatric population are congenital heart diseases, especially cyanotic heart diseases and the use of central venous catheters.

Due to the improved management of children affected by congenital heart diseases, the increasing use of central catheters, the incidence of IE is also increasing these last years. Rheumatic heart disease is an uncommon predisposing factor in developed countries, the incidence of the disease has drastically declined over the decades.

Our patient in this case report had MFS. This is an autosomal dominant genetic disorder caused by mutations in *FBN1* gene, located on the 15q21 chromosome. This gene is coding for the Fibrilline-1, a protein of the conjunctival tissue. The clinical manifestations of this syndrome may involve ophthalmologic, pulmonary, musculoskeletal and cardiovascular systems. The main manifestations in the cardiovascular systems are aortic root dissection, mitral valve prolapse, pulmonary artery enlargement and left ventricular dilatation (8).

*Streptococcus viridans* and *Staphylococcus aureus* are the major responsible pathogens, accounting for > 90% of IE (6). *Streptococcus pneumoniae* is extremely rare and accounts for 3-7% (3). Serotype 13 is non-vaccinal and is the only case found by the national reference laboratory during these 5 past years. Our patient was immunocompetent and did not have any history of invasive infection in the past. She had an abdominal ultrasonography that confirmed the presence of a spleen.

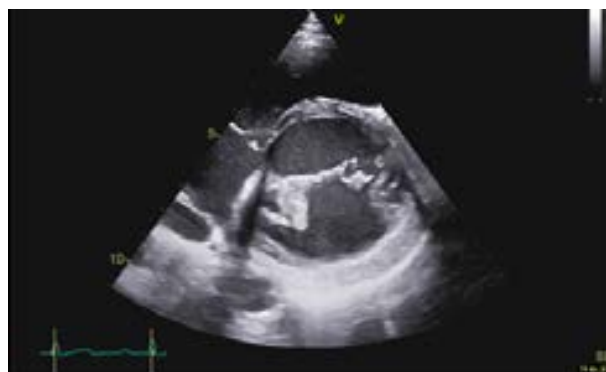
The clinical manifestations of IE are variable and non-specific. The typical signs like Roth spot and Osler nodes are rarely seen in children. The apparition or modification of a known heart murmur can be a sign of IE, but normal examination, as it was for our patient, cannot rule out the diagnosis. The diagnosis is based on the modified Duke criteria, our patient had 3 minor criteria (table 1), IE was thus suspected (6). When IE is suspected, blood cultures and echocardiography are essential to the diagnosis. Transthoracic echocardiography (TTE) has high sensitivity and is the gold standard for IE diagnosis in children. Transesophageal echocardiography (TOE) should be performed to confirm the diagnosis and demonstrate complications and must be considered for children with prosthetic valve or when there is a high suspicion for IE with a normal TTE. The absence of vegetation does not exclude the diagnosis, it is thus important to repeat the examination if the suspicion remains high. For our patient, the first TTE didn't show any vegetation, maybe because it was the early stage of the disease, TOE should have been performed, especially in front of increased mitral regurgitation.

In our patient, the first blood culture was negative, but she had received two doses of antibiotics before admission which probably turned the first cultures negative. The diagnosis is much more difficult in patients already receiving antibiotics, sometimes for unclear or unjustified reasons.

Once IE is confirmed treatment is complex and long (4-6 weeks to treat effectively). It is empirically based on the microbiologic epidemiology of the country and later on the antibiogram and MIC.

20 to 30% of the patients will need surgery. Indications for cardiovascular intervention are: uncontrolled infection, peri-annular abscedation, valvular perforation, worsening heart failure or vegetation measuring more than 10 millimeters (5, 6, 9). The lesions caused by pneumococcal IE progresses rapidly, thus early surgery can improve the prognosis (3).

Figure 1a : Transthoracic echocardiography



Vegetation

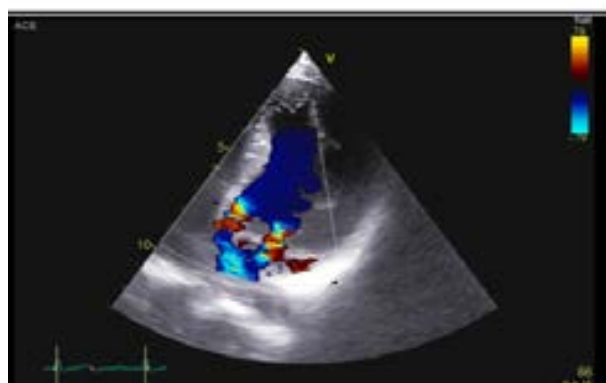
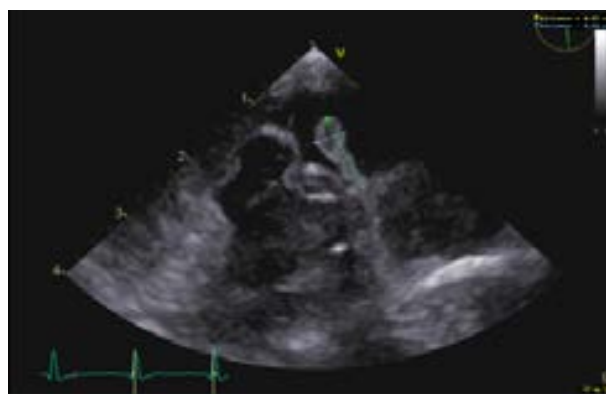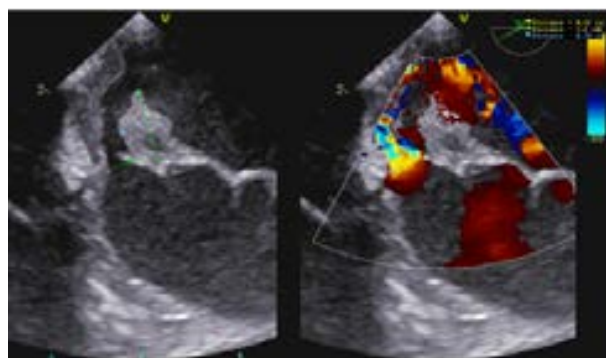


Figure 1b : Transesophageal echocardiography



Vegetation 9 x 4 mm



## Conclusion

IE is a rare disease in children but associated with a high mortality and morbidity. The incidence is increasing due to improved management of congenital heart diseases.

This diagnosis must be suspected in any children with prolonged fever without source, especially when there is a risk factor. The diagnosis is based on the Modified Duke criteria and is confirmed by blood cultures and echocardiography.

*Streptococcus viridans* and *Staphylococcus aureus* are the main pathogens found. *Streptococcus pneumoniae* is uncommon due to the vaccine coverage. Because of the global immunization against certain pneumococcal serotypes, we are facing pneumococcal serotypes not met before.

Antibiotics should never be prescribed without having obtained all cultures, otherwise the diagnosis of an invasive bacterial infection may be delayed while prompt management is crucial to reduce mortality and morbidity.

## Conflict of interest

The authors have no funding or conflicts of interest to disclose.

## REFERENCES:




1. Andrade AL, Toscano CM, Minamisava R, Costa PS, Andrade JG. Pneumococcal disease manifestation in children before and after vaccination: what's new? *Vaccine*. 2011;29 Suppl 3:C2-14.
2. de Egea V, Munoz P, Valerio M, de Alarcon A, Lepe JA, Miro JM, et al. Characteristics and Outcome of *Streptococcus pneumoniae* Endocarditis in the XXI Century: A Systematic Review of 111 Cases (2000-2013). *Medicine (Baltimore)*. 2015;94(39):e1562.
3. Ishiwada N, Niwa K, Tateno S, Yoshinaga M, Terai M, Nakazawa M. Pneumococcal endocarditis in children: a nationwide survey in Japan. *Int J Cardiol*. 2008;123(3):298-301.
4. Gupta S, Sakhuja A, McGrath E, Asmar B. Trends, microbiology, and outcomes of infective endocarditis in children during 2000-2010 in the United States. *Congenit Heart Dis*. 2017;12(2):196-201.
5. Johnson JA, Boyce TG, Cetta F, Steckelberg JM, Johnson JN. Infective endocarditis in the pediatric patient: a 60-year single-institution review. *Mayo Clin Proc*. 2012;87(7):629-35.
6. Singh Y, Ganjoo N. Infective endocarditis in children. *Paediatrics and Child Health*. 2017;27(2):68-74.
7. Jortveit J, Eskedal L, Klčovansky J, Døhlen G, Holmstrøm H. Prevalence of infective endocarditis in children. *Tidsskr Nor Laegeforen*. 2019;139(2).
8. Yuan SM, Jing H. Marfan's syndrome: an overview. *Sao Paulo Med J*. 2010;128(6):360-6.
9. Carceller A, Lebel MH, Larose G, Boutin C. [New trends in pediatric endocarditis]. *Ann Pediatr (Barc)*. 2005;63(5):396-402.

Table 1 : Duke's criteria

Major criteria	
I.	Blood cultures positive
-	Typical microorganisms from 2 separate blood cultures : <i>Viridans streptococci</i> , <i>Streptococcus gallolyticus</i> , HACEK group, <i>Staphylococcus aureus</i> or community acquired enterococci in the absence of a primary focus
-	Microorganisms from persistently positive blood cultures
-	Single positive blood culture for <i>Coxiella burnetii</i> or phase I IgG antibody titre > 1 :800
II.	Imaging positive for IE
-	Echocardiogram positive for IE : vegetation, abscess, pseudoaneurysm, intracardiac fistula, valvular perforation or aneurysm , new partial dehiscence of prosthetic valve
-	Abnormal activity around the site of prosthetic valve implantation detected by F-FDG PET/CT (only if the valve was implanted > 3 months) or radiolabelled leukocytes SPECT/CT
-	Definite paravalvular lesions by cardiac CT
Minor criteria	
I.	Predisposition such as predisposing heart condition or drug injection
II.	Fever > 38°C
III.	Vascular phenomena : major arterial emboli, septic pulmonary infarcts, infectious aneurysm, intracranial haemorrhage, conjunctival haemorrhages, Janeway's lesions
IV.	Immunological phenomena : glomerulonephritis, Osler's nodes, Roth's spots, rheumatoid factor
V.	Microbiological evidence : positive blood cultures but does not meet a major criterion as noted above or serological evidence of active infection with microorganism consistent with IE

Alles voor baby's, en zelfs nog  
een beetje meer.

Tout pour eux.  
Et même un peu plus.

- ✓ Zonder sacharose  
Sans saccharose 
- ✓ Zonder aroma  
Sans arômes 
- ✓ Zonder additieven  
Sans additifs 

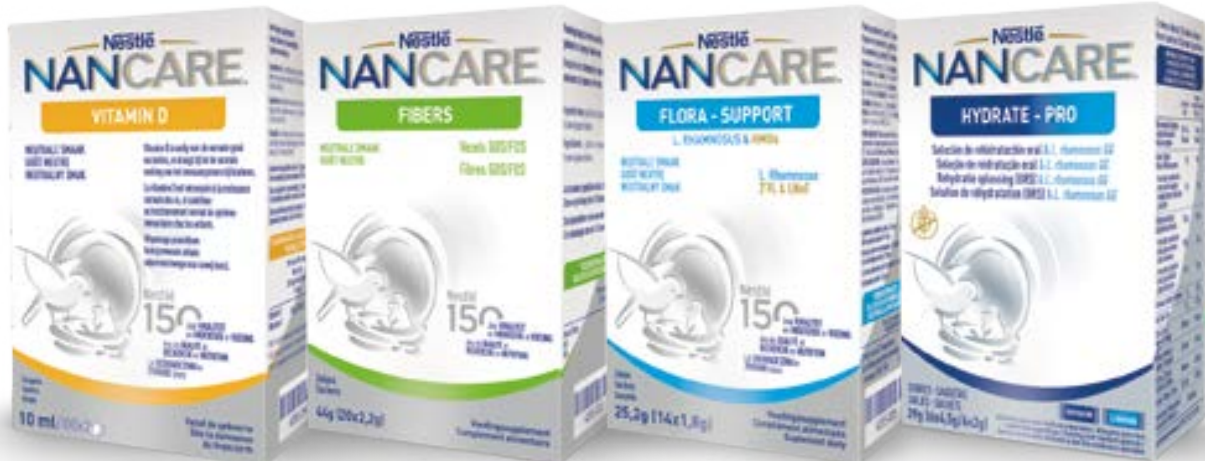

VITAMINE D

VEZELS  
FIBRES

PROBIOTICUM LGG+ HMO'S  
PROBIOTIQUE LGG+ HMO'S

ORS + PROBIOTICUM LGG  
ORS + PROBIOTIQUE LGG



CNK : 4265-294

CNK : 4265-302

CNK : 4265-328

CNK : 4265-310

Ontdek **NANCARE®**, een gamma **voedingssupplementen**  
en een **rehydratieoplossing** speciaal ontwikkeld  
voor baby's.

Découvrez **NANCARE®**, une gamme de **compléments  
alimentaires** et une **solution de réhydratation**  
spécialement conçues pour les bébés.

Nestlé  
**NANCARE®**

Partner van hun welzijn  
Partenaire de leur bien-être

BELANGRIJKE INFORMATIE. Borstvoeding is de ideale voeding voor baby's. Voedingssupplementen mogen niet worden gebruikt ter vervanging voor moedermelk, een gevarieerde, evenwichtige voeding of een gezonde levensstijl. De aanbevolen dagelijkse dosis niet overschrijden. Buiten bereik van kinderen bewaren.  
AVIS IMPORTANT : Les compléments alimentaires ne doivent pas être utilisés comme substitut du lait maternel, d'une alimentation variée et équilibrée ou d'un mode de vie sain. Ne pas dépasser la dose journalière recommandée. Tenir hors de portée des enfants.  
V.U./E.R. : Sophie Alexander BEO, Nestlé België SA, Rue de Birminghamstraat 221 - 1070 Bruxelles/Brussel, BCE/KBO 0402.231.383 - PID2868.

## Case Report

# Rubella vaccine associated cutaneous granulomatous disease as initial manifestation of an inborn error of immunity: a case report

Shari Schroven<sup>a</sup>, Michal Ulicki<sup>a</sup>, Marieke De Bruyne<sup>b</sup>, Jeroen Van Kampen<sup>c</sup>, Carolien Bonroy<sup>d</sup>, Vasiliki Siozopoulou<sup>a</sup>, Victoria Bordon<sup>d</sup>, Julie Leysen<sup>a</sup>, Filomeen Haerynck<sup>b,d</sup>, Koen Vanden Driessche<sup>a</sup>

<sup>a</sup> University Hospital Antwerp, Edegem, Belgium

<sup>b</sup> Center for Medical Genetics, Ghent University and Ghent University Hospital, Ghent, Belgium

<sup>c</sup> Erasmus MC, Department of Viroscience, Rotterdam, The Netherlands

<sup>d</sup> University Hospital Ghent, Ghent, Belgium

shari\_schroven@hotmail.com ; koen.vandendriessche@uza.be

## Keywords

iVDRV; rubella; PID; inborn error of immunity

## Abstract

Immunodeficiency-related vaccine-derived rubella virus cutaneous granulomatous disease as the initial manifestation of an inborn error of immunity is rare. We present a case of a 17-month-old girl with a skin eruption, which started three weeks after a routine measles, mumps, and rubella vaccination. Immunofluorescence staining and PCR and sequencing confirmed the presence of rubella virus (vaccine strain). Whole exome-based primary immunodeficiency panel revealed a homozygous *UNC13D* 12-bp deletion, associated with familial hemophagocytic lymphohistiocytosis.

## Introduction

Immunodeficiency-related vaccine-derived rubella virus (iVDRV) cutaneous granulomatous disease is a rare condition. The largest case series to date describes 66 patients with iVDRV (1). These patients are associated with multiple different inborn errors of immunity (see table 1), but mostly with ataxia telangiectasia (1-6).

We present a previously healthy toddler with iVDRV cutaneous granulomatous disease as initial manifestation of familial hemophagocytic lymphohistiocytosis (HLH).

**Table 1.:** Inborn errors of immunity described in iVDRV patients in current literature (1-6)

Ataxia telangiectasia
Nijmegen breakage syndrome
Cartilage-hair hypoplasia
XLA
MHC class II deficiency
Coronin-1A deficiency
Marden-Walker syndrome
CVID
NEMO
DNA ligase 4 deficiency
Artemis deficiency
WHIM syndrome
X-SCID
Griscelli syndrome type 2
Familial hemophagocytic lymphohistiocytosis types 2, 3 and 5

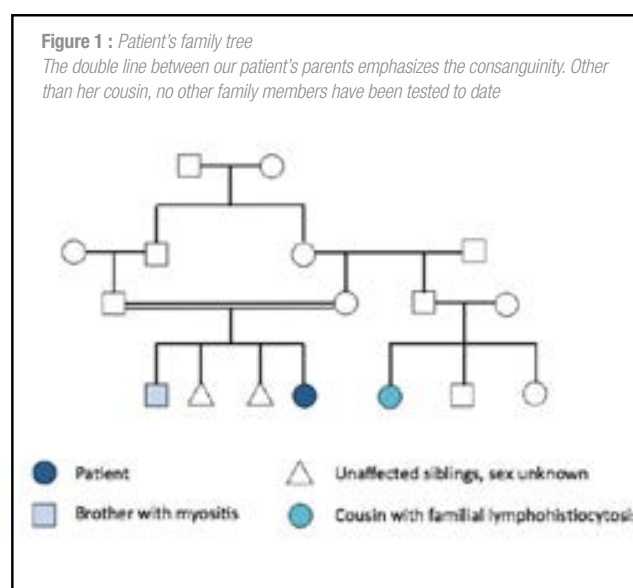
## Case report

A 17-month-old girl was referred to our hospital by her dermatologist, with a non-itchy eruption of skin lesions on arms, legs and face since a few months. She had no accompanying symptoms and had not been sick when the rash started.

Her personal history was uneventful, except for a few ear and throat infections for which she had been treated with antibiotics. Aphthous mouth ulcers during an infectious episode with fever were also reported.

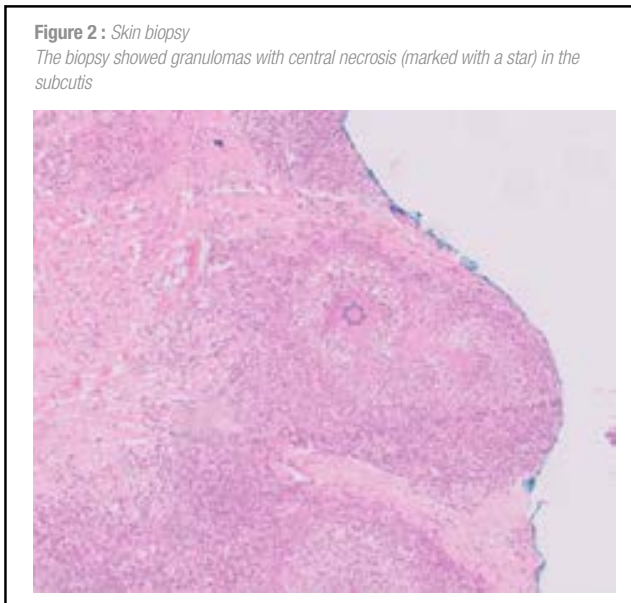
The appearance of the lesions coincided with the introduction of toddler milk and happened three weeks after our patient's 12-month vaccinations (measles, mumps, and rubella (MMR) vaccine and pneumococcal conjugate vaccine).

She was the fourth child of healthy consanguineous parents of Moroccan descent; none of whom showed a similar rash, but her adolescent brother suffered from unexplained persistent mild myositis with elevated creatine kinase. Her cousin presented with familial lymphohistiocytosis when she was three months, for which she received an allogeneic hematopoietic stem cell transplantation (HSCT). A family tree of her family is shown in figure 1.



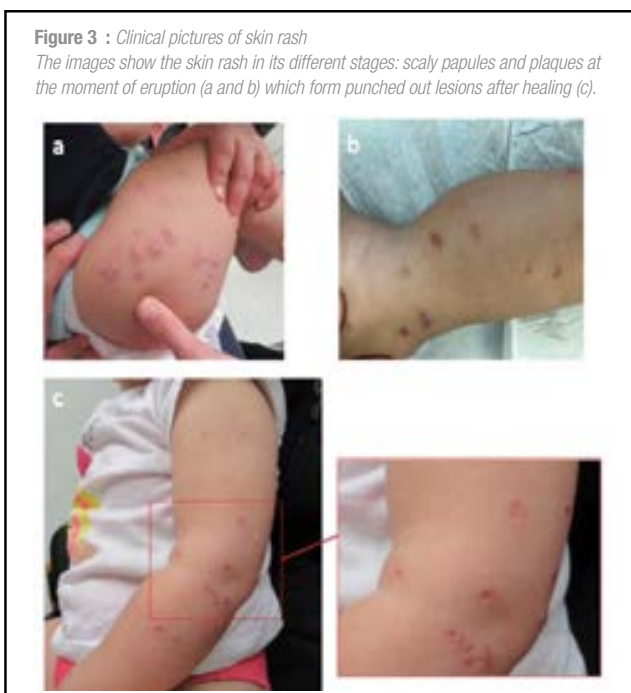Before being referred to our hospital, she had already been seen by a dermatologist, who performed a blood test and a skin biopsy. Blood test showed no abnormalities except for a positive antinuclear factor (ANF) screening (1/160 titer). Skin biopsy demonstrated discrete lichenoid dermatitis with superficial and deep inflammatory infiltrates with numerous plasma cells and the formation of some granulomas with central necrosis (fig 2). These histological findings were consistent with a chronic infectious process, but additional immunohistochemical examination could not reveal an etiological cause.

She had already been treated with a betamethasone cream for two weeks, without any improvement of the rash.



On clinical examination we saw scattered pink-purple scaly papules and plaques (5-10 millimeters in diameter) with an occasional pustule, on both arms and legs and a few on the face (fig 3 (a-b)). Trunk and abdomen were spared. When the lesions healed, they left punched out scars (fig 3 c). Clinical examination was otherwise normal except for a geographic tongue.

Microscopy and/or culture on new skin biopsies were negative for general bacteria, fungi, spirochetes, *Leishmania*, and mycobacteria, including *M. tuberculosis* and *M. leprae* PCR. Serology was negative for *B. henselae*, syphilis, EBV, CMV, HIV, hepatitis viruses and parvovirus, as was a quantiferon test



for tuberculosis. Because Behçet's disease, sarcoidosis, Wegener's granulomatosis, and Churg-Strauss syndrome were also considered, HLA B51, ACE and ANCA were determined but all results returned negative except for a weakly positive c-ANCA (1/20). There were however no signs of vasculitis, also not in repeat biopsies. The histopathology was not consistent with pityriasis lichenoides et varioliformis acuta (PLEVA), nor with pityriasis lichenoides chronica (PLC), and also not with Langerhans cell histiocytosis.

Chronic granulomatous disease was excluded by respiratory burst testing and further immunological screening showed a normal thymus gland, normal immunoglobulin levels and normal numbers of lymphocyte subsets, including maturation series.

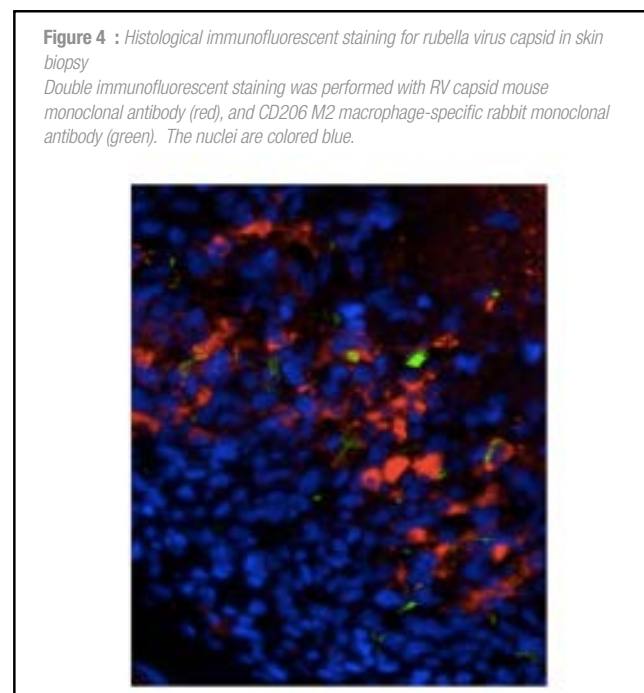
Prolidase deficiency, that can present with scattered skin ulcerations, was excluded by the absence of imidodipeptides in the urine.

Finally, a causal relation with the MMR vaccine was considered because mother emphasized that the skin eruption appeared three weeks after vaccination. Both immunofluorescence staining (Centers for Disease Control and Prevention, Atlanta, US) and PCR (Erasmus MC, Rotterdam, NL) confirmed the presence of Rubella virus in the granulomas (fig 4). Nested PCR identified a 285nt fragment that belonged to the World Health Organization rubella vaccine genome. Basic Local Alignment Search Tool (BLAST) analysis matched this fragment with the RA 27/3 vaccine strain. PCR was negative for mumps and measles virus.

A micro-array analysis revealed no large deletions or duplications. A whole exome-based primary immunodeficiency panel revealed a known homozygous UNC13D 12-bp deletion (c.1828\_1839del, p.(Arg610\_Gln613del)), associated with familial HLH, previously found in her cousin. Functional testing (CD107a upregulation) confirmed a significant decreased degranulation in natural killer (NK) cells and CD8+ T-lymphocytes.

Awaiting HSCT, our patient was started on monthly intravenous immunoglobulins to prevent infections. Based on a study of Pereylygina et al., in which one out of seven similar patients showed good response and two out of seven showed no improvement but a clinical stabilization on nitazoxanide, a broad-spectrum antiparasitic drug for which also antiviral activity is reported, including in vitro activity against Rubella virus, our patient also received this treatment (7). After starting with oral nitazoxanide (250 mg twice daily), skin lesions seemed to dry out and fewer new ones seemed to appear. Ribavirin, remdesivir, favapirivir and galedesivir were also considered but not started because either too expensive, too toxic or too experimental.

She recently received an allogenic HSCT with good engraftment. Soon after the HSCT, we observed a gradual involution of the skin lesions.



## Discussion

Inborn errors of immunity (IEI) are genetic defects causing problems with the immune system, usually manifesting as an increased susceptibility to infectious diseases, autoinflammatory diseases, allergy, or autoimmunity. They were considered to be rare conditions, but nowadays the prevalence of IEI is estimated around 1/1000 – 1/5000 (8). With improving genetic techniques, which also become more accessible and affordable, new IEIs are being discovered at a rapid rate, with more than 400 IEIs known until today (9).

This growing genetic knowledge is also very important with regard to treatment, because a correct genetic diagnosis can alter the treatment course. For example, some IEIs are known to respond very well to a stem cell transplant, while others do not.

IEIs typically present with recurrent and/or chronic infections. Depending on the type of IEI, these infections can be due to common or opportunistic pathogens. Some IEIs don't present with the typical infection, but rather with failure to thrive, severe atopy, autoinflammatory disease, or autoimmune disease.

In our case, we searched for the presence of rubella because the patient's mother pointed out that the rash started three weeks after vaccination and because a literature search suggested iVDRV as a possibility. After confirmation of the presence of rubella virus in the granulomas, an inborn error of immunity was a likely diagnosis.

Most patients with immunodeficiency-related vaccine-derived rubella virus cutaneous granulomatous disease (iVDRV) reported in literature were associated with ataxia telangiectasia (AT), but our patient did not meet the diagnostic criteria for AT since she did not have a decreased IgA, nor an increased radiosensitivity or an elevated  $\alpha$ -fetoprotein. Other inborn errors of immunity associated with iVDRV (table 1) were also unlikely, for example cartilage-hair hypoplasia (because she had a normal stature), Marden Walker syndrome (due to the absence of contractures) and X-linked agammaglobulinemia (she had normal gammaglobulin levels).

Adenosine deaminase deficiency and urine nucleoside phosphorylase deficiency, two immunodeficiencies caused by a genetic defect of the purine salvage pathway that result in severe combined immunodeficiency (SCID), were also ruled out (2,3).

Hemophagocytic lymphohistiocytosis (HLH) is a potentially life threatening condition caused by an uncontrolled immune activation. It can occur both in a familial (genetic) or sporadic form and it is important to distinguish between the two, since many of the genetic forms can be treated by allogeneic hematopoietic cell transplantation (10). Our patient had a confirmed genetic mutation associated with familial HLH, but did not yet develop a clinically active HLH.

Allogeneic hematopoietic stem cell transplantation (HSCT) is still the only curative treatment for HLH. HSCT has a higher rate of success when performed pre-emptively rather than with active disease. Therefore, pre-emptive treatment is often recommended in patients with proven genetic abnormalities, but taking into account that HSCT isn't without risk, not every patient with a genetic form of HLH should undergo this treatment preventively (11). In our case the patient had a *UNC13D* mutation, associated with familial HLH-3, in which central nervous system involvement is more common (12,13).

According to a review by Amirifar et al, in which they describe the characteristics of 322 patients with a *UNC13D* mutation, dermatological disorders appear in 25% of these patients but the type of cutaneous abnormalities was not further specified (14).

Gro et al and Murphy et al report in total five patients with a similar clinical presentation and a *UNC13D* mutation (6,15). In three of these patients rubella virus was also detected.

As mentioned before, the patient's brother suffered from myositis, which developed after he received the second MMR vaccine. He was invited for further testing. We emphasized that other family members, with similar consanguinity, should be screened before administering live-attenuated vaccines.

## Conclusion

Immunodeficiency-related vaccine-derived rubella virus (iVDRV) cutaneous granulomatous disease is a rare complication following live-attenuated rubella vaccination. It is associated with different types of inborn errors of immunity, so further investigation is warranted when coming across this clinical presentation. Thinking about an IEI when complications arise after live-attenuated vaccination is the most important take home message from this case, as well as to always trust a mother's instinct, because most pediatricians know that they often tend to be right.

## Acknowledgements

We would like to thank Dr Ludmila Perelegina from the CDC in Atlanta for performing the immunofluorescence staining and providing us the image for usage in our article. We would also like to thank Prof Dr Benson Ogunjimi (University Hospital Antwerp) for his contribution in diagnosing this patient.

## Conflict of interest

The authors declare that they have no conflict of interest in the subject matter or materials discussed in this manuscript.

## REFERENCES:

1. Perelegina L, Icenogle J, Sullivan K. Rubella virus-associated chronic inflammation in primary immunodeficiency diseases. *Current Opinion in Allergy & Clinical Immunology*. 2020;20(6):574-581.
2. Buchbinder D, Hauck F, Albert MH, Rack A, Bakhtiar S, Shcherbina A, et al. Rubella Virus-Associated Cutaneous Granulomatous Disease: a Unique Complication in Immune-Deficient Patients, Not Limited to DNA Repair Disorders. *J Clin Immunol*. 2019;39(1):81–9.
3. Perelegina L, Plotkin S, Russo P, Hautala T, Bonilla F, Ochs HD, et al. Rubella persistence in epidermal keratinocytes and granuloma M2 macrophages in patients with primary immunodeficiencies. *J Allergy Clinical Immunol*. 2016;138(5):1436-39.
4. Neven B, Pérot P, Bruneau J, Pasquet M, Ramirez M, Diana J et al. Cutaneous and Visceral Chronic Granulomatous Disease Triggered by a Rubella Virus Vaccine Strain in Children With Primary Immunodeficiencies. *Clin Infect Dis*. 2017;64(1):83-86.
5. Leclerc-Mercier S, Moshous D, Neven B, Mahlaoui N, Martin L, Pellier I et al. Cutaneous granulomas with primary immunodeficiency in children: a report of 17 new patients and a review of the literature. *J Europ Acad Dermatol Venereol*. 2019;33(7):1412-1420.
6. Groß M, Speckmann C, May A, Gajardo-Carrasco T, Wustrau K, Maier S et al. Rubella vaccine-induced granulomas are a novel phenotype with incomplete penetrance of genetic defects in cytotoxicity. *J Allergy Clinical Immunol*. 2021;S0091-6749(21)00809-5.
7. Perelegina L, Buchbinder D, Dorsey MJ, Eloit M, Hauck F, Hautala T, et al. Outcomes for Nitazoxanide Treatment in a Case Series of Patients with Primary Immunodeficiencies and Rubella Virus-Associated Granuloma. *J Clin Immunol*. 2019;39(1):112–17.
8. Tangye SG, Al-Herz W, Bousfiha A, Chatila T, Cunningham-Rundles C, Etzioni A, et al. Human Inborn Errors of Immunity: 2019 Update on the Classification from the International Union of Immunological Societies Expert Committee. *J Clin Immunol*. 2020;40(1):24-64.
9. Tangye SG, Al-Herz W, Bousfiha A, Cunningham-Rundles C, Franco JL, Holland SM, et al. The Ever-Increasing Array of Novel Inborn Errors of Immunity: an Interim Update by the IUIS Committee. *J Clin Immunol*. 2021;41(3):666-79.
10. Canna SW, Marsh RA. Pediatric hemophagocytic lymphohistiocytosis. *Blood*. 2020;135(16):1332-43.
11. Lehmborg K, Moshous D, Booth C. Haematopoietic Stem Cell Transplantation for Primary Haemophagocytic Lymphohistiocytosis. *Frontiers in Pediatrics*. 2019;7:435.
12. Gurgey A, Aytac S, Balta G, Oguz KK, Gumruk F. Central nervous system involvement in Turkish children with primary hemophagocytic lymphohistiocytosis. *J Child Neurol*. 2008;23(11):1293–9.
13. Giri PP, Biswas N, Chakravarty S. Familial Hemophagocytic Lymphohistiocytosis due to Mutation of *UNC13D* Gene. *Indian J Hematol Blood Transfus*. 2016;32(1):344–6.
14. Amirifar P, Ranjouri M, Abolhassani H, Moeni Shad T, Almasi-Hashiani A, Azizi G et al. Clinical, immunological and genetic findings in patients with *UNC13D* deficiency (FHL3): A systematic review. *Pediatr Allergy Immunol*. 2021;32(1):186-197.
15. Murphy MJ. Necrotizing palisaded granulomatous dermatitis as a manifestation of familial hemophagocytic lymphohistiocytosis. *J Cutan Pathol*. 2010;37(8):907–10.

**Nutrilon**  
PRO**fu**tura®



tot  
3 jaar

**Nieuwe verpakking 100% recycleerbaar**  
**Steeds onze zelfde formule**  
die het meest aanleunt bij moedermelk

**DUO BIOTIK**

HMO's 2'FL & 3'GL  
Prebiotica  
scGOS:lcFOS (9:1)

Postbiotica  
β-Palmitaat  
ARA & DHA

**Ondersteunt een gezond immuunsysteem**  
(1-6)

**Zachte ontlasting, die lijkt op die van borstgevoede baby's**  
(7-8)

**Gemakkelijke Vertering**  
(8-9)

**Belangrijk:** Borstvoeding is de ideale voeding voor baby's.  
Informatie uitsluitend bestemd voor het medisch en (para)medisch corps - V.U.: N.V. Nutricia België - Werkhuizenkaai 160 - 1000 Brussel

(1) Roberfroid M, et al. British Journal of Nutrition. 2010;104(S2):S1-S63; (2) Boehm G, et al. Arch. Dis Child. 2002;86:F178-81; (3) Bruzzese E, et al. Clin Nutr. 2009;28(2):156-161; (4) Knol J, et al. J Pediatr Gastroenterol Nutr. 2003;36:566; (5) Knol J, et al. J Pediatr Gastroenterol Nutr. 2005;40:36-42; (6) Tims S, et al. J Pediatr Gastroenterol Nutr. 2018;66(S2):1-1177; (7) Rodriguez-Herrera A, et al. J Pediatr Gastroenterol Nutr. 2016a;62:Abstract G-P-230:422; (8) Havlicekova, et al. Nutrition Journal. 2016;15:28; (9) Garçette K, et al. Med. Enfance. 2007;27:3-7.

Nutrilon® is  
een merk van **NUTRICIA**



## Case Report

# Early infantile epileptic encephalopathy: unique characteristics on brain MRI leading towards diagnosis of *SLC13A5* gene mutation. Case report and literature review

Delphine Dinneweth<sup>a</sup>, Pauline Snijder<sup>b</sup>, Cynthia van der Starre<sup>b</sup>, Daniëlla Roofthoof<sup>b</sup>, Liesbeth Smit<sup>b,c</sup>

<sup>a</sup> Department of Paediatrics, University Hospital Ghent, Ghent, Belgium

<sup>b</sup> Department of Paediatrics, subdivision of Neonatology Erasmus MC Sophia Children's hospital, Rotterdam, the Netherlands

<sup>c</sup> Department of Neurology, subdivision of Paediatric Neurology, Erasmus MC Sophia Children's hospital, Rotterdam, the Netherlands

delphinedinneweth@hotmail.com

### Keywords

epileptic encephalopathy - neonate - *SLC13A5* gene mutation - punctate white matter lesions - case report

### Abstract

Developmental and epileptic encephalopathy (DEE) is a severe epileptic condition characterized by frequent, drug-resistant seizures and developmental delay with onset in infancy. The aetiology is diverse but genetic causes are mostly discovered. Clinically it is a variable condition with different degrees of psychomotor and/or cognitive delay. One type of infantile epilepsy is believed to be caused by a biallelic mutation in the *SLC13A5* gene, which codes for a cytoplasmic sodium-dependent citrate carrier that is primarily expressed in neurons. The gene mutation has been recognised in infants with punctate white matter lesions on brain magnetic resonance imaging (MRI) who do not have a history of hypoxic-ischemic encephalopathy.

We present a case of a full-term baby girl who had repeated seizures and encephalopathy starting on the first day of life. Diagnostic work-up revealed no infectious cause and metabolic testing was normal. Several small punctate white matter lesions were discovered on brain MRI, leading to a genetic mutation that causes DEE. A homozygous mutation in *SLC13A5* was confirmed by genetic testing.

The characteristic MRI pattern in our case offered a clue to the diagnosis of the refractory neonatal seizures. The pathophysiology of the *SLC13A5* gene mutation is not well understood, and therapeutic options have not been thoroughly investigated.

### Introduction

Neonatal seizures are a common issue on the neonatal ward (1-5 per 1000 new-borns) with a variety of clinical and etiological causes: hypoxic-ischemic encephalopathy, stroke or haemorrhage, infections, cortical malformations, errors of metabolism and genetic etiologies (table 1) (1-3). Because of the immature brain, several seizures are subclinical or non-specific and so are mostly electrographic-only seizures (3, 4). Amplitude-integrated electroencephalogram (aEEG) plays a crucial role in classification of seizures as the new International League Against Epilepsy (ILAE) seizure classification proposes (electro-clinical or electrographic only), and is crucial for therapy and prognosis (3).

Next generation sequencing (NGS) has been a significant advance in the study of genetic causes of neonatal epilepsy and early-onset epileptic encephalopathies in recent years. While more epileptic encephalopathies are being linked to a genetic cause, therapeutic options remain restricted. This case report shows how a combination of clinical features and unique characteristics on neuro-imaging can lead to targeted genetic testing. An analysis of the literature was conducted on the few existing studies on developmental and epileptic encephalopathy (DEE) caused by a *SLC13A5* gene mutation.

### Case report

We report a full-term baby girl born by vacuum extraction and having a good start with Apgar scores of 9 and 10 at 1 and 5 minutes and normal cord blood gases. She developed seizures one hour postpartum, beginning with cyanotic, 30-second tonic focal seizures and progressing to generalized repeated clonic seizures. The seizures were of similar nature. Parents were not consanguineous. Biochemical tests showed normal glucose and electrolytes. She was transferred to the University hospital's neonatal intensive care unit for neurological evaluation. On clinical neurological examination, there was some

agitation, axial hypotonia, normal tendon reflexes, no other abnormalities and no facial dysmorphism. Several antiepileptic drugs were given. The seizures stopped only with continuous midazolam. Due to insufficient respiratory drive as a side effect of midazolam, intubation was required. She was diagnosed with epileptic encephalopathy as a result of refractory epilepsy with clinical seizures confirmed with continuous aEEG. A ketogenic diet was started with initial success, but when the antiepileptic drug doses were reduced, the seizures returned. They were unresponsive to high doses of antiepileptic drugs. Figure 1 depicts a summary of the therapy. Blood, urine and liquor samples, as well as imaging, revealed no infectious cause. We conducted a thorough neurometabolic work-up. Normal ammonia, normal lactate (serum and cerebrospinal fluid), normal urinary organic acids and plasma aminoacids, and normal acylcarnitines were found, ruling out nonketotic hyperglycinemia, serine biosynthesis disorder, GLUT1 deficiency, and pyridoxine-dependent epilepsy. Several small punctate white matter lesions were seen on MRI imaging at day 2 (figure 2), which led to the differential diagnosis of *SLC13A5* gene mutation, a genetic cause of the epilepsy. A whole genome sequencing (WES) ID panel confirmed this two weeks later: homozygous *SLC13A5*:c.680C>T, p.(Thr227Met). Both parents are carriers of this autosomal recessive gene mutation. A homozygosity mapping of the parents was not performed. Due to the poor prognosis with therapy resistant seizures, it was decided by the team in consultation with the parents to discontinue intensive care treatment and start a palliative process. She died 21 days after birth.

### Discussion and literature review

Gene mutations may cause early onset epileptic disorders in the neonatal period, which are clinically and aetiologically heterogeneous. Ohtahara syndrome (OMIM #308350), early myoclonic epilepsy, malignant migration par-

**Table 1:** Causes of neonatal seizures / Differential diagnosis (1, 2)

Cause	Example	Incidence	Term	Preterm	
<b>Primary intracranial origin</b>					
Hypoxic-ischemic encephalopathy		37-60%	+++		
Vascular	- Intracranial haemorrhage	5-18%	+	+++	
	- Infarction, stroke	6-15%	+++	++	
Infectious	Meningitis, encephalitis, congenital infection	5-15%	+++	++	
Brain malformations	Cerebral dysgenesis, migration disorders, malformation	5-17%	++	+	
Trauma		Unknown			
<b>Systemic / other origin</b>					
Metabolic	- Inborn errors of metabolism	- Disorder in metabolism of amino acids, urea cycles, purines - Vitamin sensitive disorders - Peroxisomal disorders and mitochondrial disorders Hypoglycaemia, hypocalcaemia, hypo- or hypernatremia, hypomagnesaemia, hyperammonaemia by urea cycle disorder	1-4%	++	+
	- Acute: electrolyte imbalance		1-5%	?	?
Genetic	- Benign epilepsy syndrome		Unknown (1%)	?	?
	- Malignant epilepsy syndrome		Unknown (1%)	?	?
Toxicity / Withdrawal		Sporadic (4%)	++	+	

**Table 2:** Mutations and MRI features in different families (7, 8)

	Family 1	Family 2	Family 3	Family 4	Family 5	Family 6
Number of patients	2	2	2	1	2	1
Mutations	c.1280C>T p.(Ser427Leu) homozygous	c.655G>A p.(Gly219Arg) and c.1280C>T p.(Ser427Leu)	c.1280C>T p.(Ser427Leu) homo- zygous	c.680C>T p.(Thr227Met) and c.1280C>T p.(Ser427Leu)	c.655G>A p.(Gly219Arg) homo- zygous	c.680C>T p.(Thr227Met) and c.1570G>C p.(Asp524His)
MRI results	Both patients: PWML	Both patients: Extensive bilateral PWML	-Patient 1. Extensive bilateral PWML, lactate peak -Patient 2. No abnormalities	Multiple bilateral PWML, small lactate peak	-Patient 1. Extensive bilateral PWML -Patient 2. Five small PWML bilateral	Three small PWML bilateral
Follow-up imaging	-	White matter loss, delayed myelination and gliosis	Delayed myelination and gliosis, white matter loss	-	-	No abnormalities
Reference	Hardies et al	Weeke et al	Weeke et al	Weeke et al	Weeke et al	Weeke et al

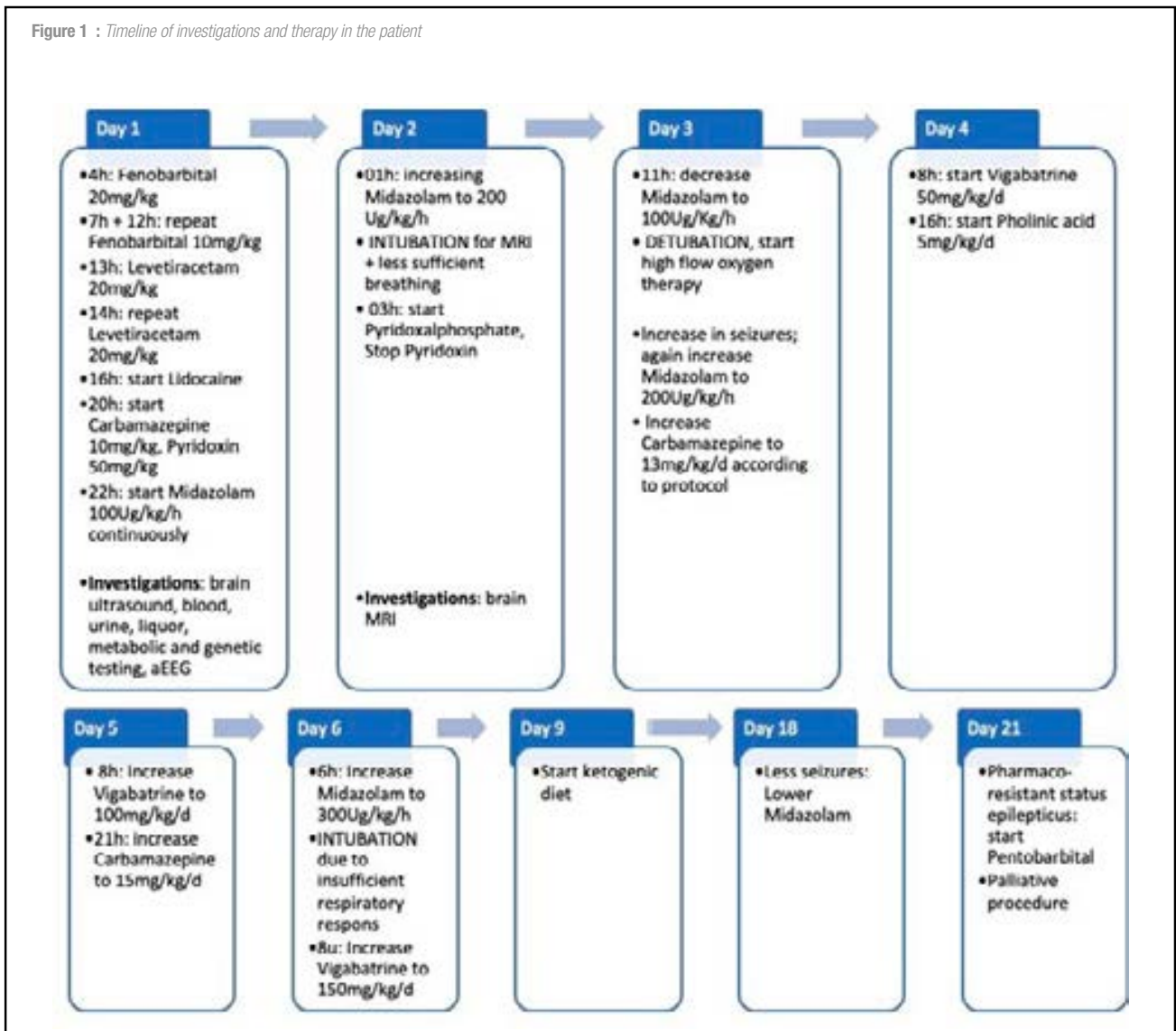
tial seizures (*KCNQ2*, *KCNT1* gene mutations), West syndrome and Dravet syndrome (*SCN1A* gene mutation, OMIM #607208) are the most well-known developmental and epileptic encephalopathies (5). With the development of new diagnostic tools such as massive parallel sequencing, a new technique in next generation sequencing, the number of pathogenic gene mutations causing monogenic epileptic syndromes is increasing. The most common mutations can now be tested using targeted gene panels.

Early-onset epileptic encephalopathy is linked to *SLC13A5* mutations, which include homozygous or compound heterozygous mutations on chromosome 17 (6). Developmental and epileptic encephalopathy type 25 (OMIM #615905) is another name for this autosomal recessive disorder. The mutation is described in 32 patients from 16 unrelated families (6-8). *SLC13A5* encodes a high affinity homodimeric cytoplasmic sodium-coupled tricarboxylate trans-

porter expressed on hepatocytes, neurons, spermatozoa and teeth (9). Citrate transporter function is either absent or decreased when the gene is mutated (6, 8, 10). Citrate is required for cellular metabolism (energy production) and neurotransmitter synthesis (e.g. glutamate) (6). Since the molecular mechanism of the transporter in neurons is largely unknown, the pathogenesis of neuronal dysfunction and epilepsy in this mutation is still poorly understood (9). In animal models, loss of function in this transporter does not result in the same neurological phenotype as in humans, making research difficult (9, 11). The disease phenotype is complex, but is characterised by drug-resistant neonatal or infantile onset seizures in the first days to months, global developmental delay (communication and motor skills) and teeth hypoplasia or hypodontia (amelogenesis imperfecta) (6, 7, 10, 11).

Multifocal and focal discharges, rhythmic theta/delta focal discharges from

Figure 1 : Timeline of investigations and therapy in the patient



both hemispheres or multifocal status epilepticus, and a continuous or discontinuous low voltage background activity are all seen on electroencephalograms (6-8). Medical characteristics and genetic confirmation are used to make the diagnosis (WES or targeted panel sequencing).

Biochemical tests are usually normal, with a slight increase of citrate in the serum and/or cerebrospinal fluid on occasion (11). The results of neuroimaging may be normal or show a distinct MRI pattern on T2-weighted imaging with punctate white matter lesions (PWML) (7, 8). The lesions are not seen on diffusion-weighted images (DWI) or susceptibility-weighted imaging (SWI). Hardies et al. found periventricular leukomalacia-like abnormalities (7). Weeke et al. discovered these lesions at neonatal age in six out of seven full-term infants without a history of hypoxic-ischemic encephalopathy receiving MRI, who progressed in some patients to gliotic scarring by the age of 18 months (table 2) (8). This supports the theory that these patients are more vulnerable to ischemia (7, 8). Since the PWML seen in this study is less severe than cystic periventricular leukomalacia or hypoxic-ischemic encephalopathy, no connection can be drawn between PWML and severe cognitive impairment in patients with *SLC13A5* mutations (8). A few patients had an increase in lactate demonstrated with magnetic resonance (MR) spectroscopy (7). Our patient did not receive MR spectroscopy. A summary of the different MRI results in literature are listed in table 2.

We saw the clinical hallmark of early-onset seizures leading to epileptic encephalopathy and drug therapy resistance in our patient. MR imaging during the diagnostic process revealed white matter lesions similar to those described in this genetic syndrome. In addition to studying 1200 other genes

linked to epileptic encephalopathy, *SLC13A5* was given top priority in genetic testing.

*SLC13A5* mutations actually do not have a precision treatment (9). The most popular antiepileptic medications are phenobarbital and valproic acid, the last one is not suitable for neonates, which have varying degrees of effectiveness. GABA altering medications (e.g. lorazepam, diazepam), sodium channel inhibitors (e.g. phenytoin, lamotrigine), acetazolamide and stiripentol, according to some anecdotal evidence, may be effective in treating seizures caused by loss-of-function mutation (12). The ketogenic diet has been suggested to be beneficial because it raises citrate levels (7, 10, 13). However a study of Klotz et al. also found an exacerbations of seizures during ketogenic treatment, so it's effect is controversial (12). There is currently no therapeutic option that can put the epileptic symptoms caused by this genetic disorder into remission.

There is still a lot to learn about this disorder, and more research is needed, such as comparing imaging (MRI) to identify potential subtle brain defects characteristic in a type of DEE and tailored therapies for therapeutic purposes.

## Conclusion

The initiation of refractory seizures in early infancy as consequence of DEE is associated with impaired cognitive developmental delay and motor growth. Most early onset developmental and epileptic encephalopathy are genetic, combined genetic-metabolic or combined genetic-structural.

The *SLC13A5* mutation associated with DEE is only described in a few stud-

ies. It has a phenotypic heterogeneity, with a delayed neurological outcome ranging from moderate to severe and no targeted treatment choice. The presence of PWML on brain MRI scans may serve as a diagnostic clue. More genetic testing will lead to the discovery of further genetic mutations that cause DEE.

#### Conflict of interest statement

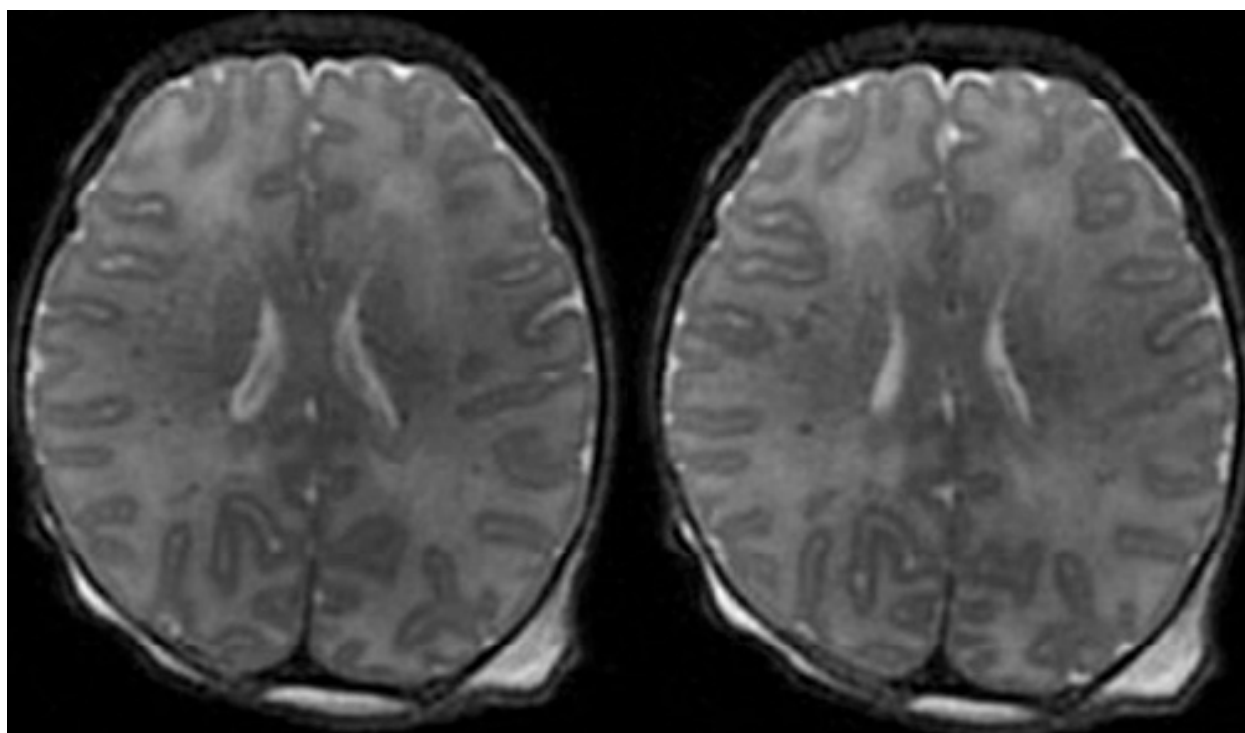
The authors of this case report declare that they have no conflict of interest. They do not have any affiliations with or involvement in any organization or entity with any financial or non-financial interest in the subject matter or materials discussed in this case report.

#### REFERENCES:

1. Vasudevan C, Levene M. Epidemiology and aetiology of neonatal seizures. *Semin Fetal Neonatal Med.* 2013;18(4):185-91.
2. Queensland Clinical Guidelines. Neonatal seizures, document MN17.23-V3-R22 [Internet]. Herston, Queensland: State of Queensland; 2017 [updated 2019 Oct; Cited 2021 Sep 7]. Available from: [https://www.health.qld.gov.au/\\_\\_data/assets/pdf\\_file/0030/143697/g-seizures.pdf](https://www.health.qld.gov.au/__data/assets/pdf_file/0030/143697/g-seizures.pdf) .
3. Pressler RM, Cilio MR, Mizrahi EM, Moshé SL, Nunes ML, Plouin P, et al. The ILAE classification of seizures and the epilepsies: Modification for seizures in the neonate. Position paper by the ILAE Task Force on Neonatal Seizures. *Epilepsia.* 2021;62(3):615-28.
4. Glass HC, Shellhaas RA. Acute Symptomatic Seizures in Neonates. *Semin Pediatr Neurol.* 2019;32:100768.
5. Gürsoy S, Erçal D. Diagnostic Approach to Genetic Causes of Early-Onset Epileptic Encephalopathy. *J Child Neurol.* 2016;31(4):523-32.
6. Thevenon J, Milh M, Feillet F, St-Onge J, Duffourd Y, Jugé C, et al. Mutations in SLC13A5 cause autosomal-recessive epileptic encephalopathy with seizure onset in the first days of life. *Am J Hum Genet.* 2014;95(1):113-20.
7. Hardies K, de Kovel CG, Weckhuysen S, Asselbergh B, Geuens T, Deconinck T, et al. Recessive mutations in SLC13A5 result in a loss of citrate transport and cause neonatal epilepsy, developmental delay and teeth hypoplasia. *Brain.* 2015;138(Pt 11):3238-50.
8. Weeke LC, Brilstra E, Braun KP, Zonneveld-Huijssoon E, Salomons GS, Koeleman BP, et al. Punctate white matter lesions in full-term infants with neonatal seizures associated with SLC13A5 mutations. *Eur J Paediatr Neurol.* 2017;21(2):396-403.
9. Bhutia YD, Kopel JJ, Lawrence JJ, Neugebauer V, Ganapathy V. Plasma Membrane Na<sup>+</sup>-Coupled Citrate Transporter (SLC13A5) and Neonatal Epileptic Encephalopathy. *Molecules.* 2017;22(3).
10. Bainbridge MN, Cooney E, Miller M, Kennedy AD, Wulff JE, Donti T, et al. Analyses of SLC13A5-epilepsy patients reveal perturbations of TCA cycle. *Mol Genet Metab.* 2017;121(4):314-9.
11. Yang QZ, Spelbrink EM, Nye KL, Hsu ER, Porter BE. Epilepsy and EEG Phenotype of SLC13A5 Citrate Transporter Disorder. *Child Neurol Open.* 2020;7:2329048x20931361.
12. Klotz J, Porter BE, Colas C, Schlessinger A, Pajor AM. Mutations in the Na(+)/citrate cotransporter NaCT (SLC13A5) in pediatric patients with epilepsy and developmental delay. *Mol Med.* 2016;22:310-21.
13. Alhakeem A, Alshibani F, Tabarki B. Extending the use of stiripentol to SLC13A5-related epileptic encephalopathy. *Brain Dev.* 2018;40(9):827-9.

**Figure 2 :** MRI images with abnormalities on T2-weighted imaging

Several millimetric punctiform white matter lesions seen as low signal intensity in the supratentorial white matter, especially in the deep and subcortical white matter, bilateral frontal and parietal seen on T2-weighted sequencing.



PRIX PUBLIQUE 86.52€

# VACCINEZ EN CONFIANCE CONTRE LE MenB

  
**BEXSERO**  
Vaccin méningococcique groupe B  
(ADNr, composant, adsorbé)

**BEXSERO est indiqué pour l'immunisation active des sujets à partir de l'âge de 2 mois contre l'infection invasive méningococcique causée par *Neisseria meningitidis* de groupe B**

**RÉSUMÉ ABRÉGÉ DES CARACTÉRISTIQUES DU PRODUIT:** Veuillez vous référer au Résumé des Caractéristiques du Produit pour une information complète concernant l'usage de ce médicament. **DÉNOMINATION DU MÉDICAMENT:** Bexsero suspension injectable en seringue préremplie. Vaccin méningococcique groupe B (ADNr, composant, adsorbé) - EU/1/12/812/001; EU/1/12/812/002; EU/1/12/812/003; EU/1/12/812/004. Classe pharmacothérapeutique: vaccins méningococciques. Code ATC: J07AH09. **COMPOSITION QUALITATIVE ET QUANTITATIVE:** Une dose (0,5 ml) contient: **Protéine de fusion recombinante NHBA de *Neisseria meningitidis* groupe B<sup>23:23</sup>:** 50 microgrammes. - **Protéine recombinante NadA de *Neisseria meningitidis* groupe B<sup>23:23</sup>:** 50 microgrammes. - **Protéine de fusion recombinante fHbp de *Neisseria meningitidis* groupe B<sup>23:23</sup>:** 50 microgrammes. - **Vésicules de membrane externe (OMV) de *Neisseria meningitidis* groupe B, souche NZ98/254 mesurée en tant que proportion de l'ensemble des protéines contenant l'antigène PorA P1.4<sup>2</sup>:** 25 microgrammes. - **Produite dans des cellules d'E. coli par la technique de l'ADNr recombinant.** - adsorbé sur hydroxyde d'aluminium (0,5 mg AP<sup>3</sup>). <sup>3</sup>NHBA (antigène de liaison à l'héparine de *Neisseria*). NadA (adhésine A de *Neisseria*). fHbp (protéine de liaison du facteur H). Pour la liste complète des excipients, voir rubrique 6.1 du RCP complet. - **Indications thérapeutiques:** Bexsero est indiqué pour l'immunisation active des sujets à partir de l'âge de 2 mois contre l'infection invasive méningococcique causée par *Neisseria meningitidis* de groupe B. L'impact de l'infection invasive à différentes tranches d'âge ainsi que la variabilité épidémiologique des antigènes des souches du groupe B dans différentes zones géographiques doivent être pris en compte lors de la vaccination. Voir rubrique 5.1 du RCP complet pour plus d'informations sur la protection contre les souches spécifiques au groupe B. Ce vaccin doit être utilisé conformément aux recommandations officielles. **Posologie et mode d'administration:** Posologie: **Tableau 1. Résumé de la posologie: Age lors de la première dose: Nourrissons de 2 à 5 mois<sup>1</sup>:** Primovaccination: Trois doses de 0,5 ml chacune. Intervalles entre les doses de primovaccination: 1 mois minimum. Rappel: Oui, une dose entre l'âge de 12 et 15 mois avec un intervalle d'au moins 6 mois entre la primovaccination et la dose de rappel<sup>1,5</sup>. - **Primovaccination:** Deux doses de 0,5 ml chacune. Intervalles entre les doses de primovaccination: 2 mois minimum. Rappel: Oui, une dose entre l'âge de 12 et 15 mois avec un intervalle d'au moins 6 mois entre la primovaccination et la dose de rappel<sup>1,5</sup>. - **Age lors de la première dose: Age lors de la première dose: Nourrissons de 6 à 11 mois:** Primovaccination: Deux doses de 0,5 ml chacune. Intervalles entre les doses de primovaccination: 2 mois minimum. Rappel: Oui, une dose au cours de la deuxième année avec un intervalle d'au moins 2 mois entre la primovaccination et la dose de rappel<sup>1,5</sup>. - **Age lors de la première dose: Enfants de 12 à 23 mois:** Primovaccination: Deux doses de 0,5 ml chacune. Intervalles entre les doses de primovaccination: 2 mois minimum. Rappel: Oui, une dose avec un intervalle de 12 à 23 mois entre la primovaccination et la dose de rappel<sup>1,5</sup>. - **Age lors de la première dose: Enfants de 2 à 10 ans: Adolescents (à partir de 11 ans) et adultes<sup>2</sup>:** Primovaccination: Deux doses de 0,5 ml chacune. Intervalles entre les doses de primovaccination: 1 mois minimum. Rappel: Selon les recommandations officielles, une dose de rappel peut être envisagée chez les sujets présentant un risque continu d'exposition à l'infection méningococcique<sup>2</sup>. <sup>2</sup>La première dose ne doit pas être administrée avant l'âge de 2 mois. La sécurité et l'efficacité de Bexsero chez les nourrissons de moins de 8 semaines n'ont pas encore été établies. Aucune donnée n'est disponible. <sup>3</sup> En cas de retard, la dose de rappel ne doit pas être administrée au-delà de l'âge de 24 mois. <sup>4</sup> Voir rubrique 5.1 du RCP complet. <sup>5</sup> Il n'existe aucune donnée chez les adultes de plus de 50 ans. **Mode d'administration:** Le vaccin est administré par une injection intramusculaire profonde, de préférence dans la face antéro-latérale de la cuisse chez le nourrisson ou dans la région du muscle deltoïde du haut du bras chez les sujets plus âgés. Des sites d'injection distincts doivent être utilisés si plusieurs vaccins sont administrés simultanément. Le vaccin ne doit pas être injecté par voie intraveineuse, sous-cutanée ni intradermique et ne doit pas être mélangé avec d'autres vaccins dans la même seringue. Pour les instructions concernant la manipulation du vaccin avant administration, voir la rubrique 6.6. **Contre-indications:** Hypersensibilité aux substances actives ou à l'un des excipients mentionnés à la rubrique 6.1. **Mises en garde spéciales et précautions d'emploi:** Comme pour les autres vaccins l'administration de Bexsero doit être reportée chez des sujets souffrant de maladie fébrile sévère aiguë. Toutefois, la présence d'une infection mineure, telle qu'un rhume, ne doit pas entrainer le report de la vaccination. Ne pas injecter par voie intravasculaire. Comme pour tout vaccin injectable, un traitement médical approprié et une surveillance adéquate doivent toujours être disponibles en cas de réaction anaphylactique consécutive à l'administration du vaccin. Des réactions en rapport avec l'anxiété, y compris des réactions vasovagales (syncope), de l'hyperventilation ou des réactions en rapport avec le stress peuvent survenir lors de la vaccination comme réaction psychogène à l'injection avec une aiguille (voir rubrique «Effets indésirables»). Il est important que des mesures soient prises en place afin d'éviter toute blessure en cas d'évanouissement. Ce vaccin ne doit pas être administré aux patients ayant une thrombocytopénie ou tout autre trouble de la coagulation qui serait une contre-indication à une injection par voie intramusculaire, à moins que le bénéfice potentiel ne soit clairement supérieur aux risques inhérents à l'administration. Comme tout vaccin, la vaccination par Bexsero peut ne pas protéger tous les sujets vaccinés. Il n'est pas attendu que Bexsero assure une protection contre la totalité des souches de méningocoque B en circulation (voir rubrique 5.1 du RCP complet). Comme pour de nombreux vaccins, les professionnels de santé doivent savoir qu'une élévation de la température corporelle peut survenir suite à la vaccination des nourrissons et des enfants (de moins de 2 ans). L'administration d'antipyrétiques à titre prophylactique pendant et juste après la vaccination peut réduire l'incidence et la sévérité des réactions fébriles postvaccinales. Un traitement antipyrétique doit être mis en place conformément aux recommandations locales chez les nourrissons et les enfants (de moins de 2 ans). Les personnes dont la réponse immunitaire est altérée soit par la prise d'un traitement immunosuppresseur, une anomalie génétique ou par d'autres causes, peuvent avoir une réponse en anticorps réduite après vaccination. Des données d'immunogénéicité sont disponibles chez les patients présentant un déficit en complément, une asplénie ou une dysfonction splénique (voir rubrique 5.1 du RCP complet). Les personnes ayant des déficits héréditaires du complément (par exemple les déficits en C3 ou C5) et les personnes recevant un traitement inhibiteur de l'activation de la fraction terminale du complément (par exemple l'Éculizumab) ont un risque accru de maladie invasive due à *Neisseria meningitidis* du groupe B, même après avoir développé des anticorps après vaccination par Bexsero. Il n'existe aucune donnée sur l'utilisation de Bexsero chez les sujets de plus de 50 ans et il existe des données limitées chez les patients atteints de maladies chroniques. Le risque potentiel d'apnée et la nécessité d'une surveillance respiratoire pendant 48 à 72 heures doivent soigneusement être pris en compte lors de l'administration des doses de primovaccination chez des grands prématurés (nés à 28 semaines de grossesse ou moins), en particulier chez ceux ayant des antécédents d'immaturité respiratoire. En raison du bénéfice élevé de la vaccination chez ces nourrissons, l'administration ne doit pas être suspendue ou reportée. Le capuchon de la seringue peut contenir du latex de caoutchouc naturel. Bien que le risque de développer des réactions allergiques soit très faible, les professionnels de santé doivent évaluer le rapport bénéfices/risques avant d'administrer ce vaccin à des sujets présentant des antécédents connus d'hypersensibilité au latex. La kanamycine est utilisée au début du procédé de fabrication et est éliminée au cours des étapes ultérieures de la fabrication. Les taux de kanamycine éventuellement détectables

dans le vaccin final sont inférieurs à 0,01 microgramme par dose. L'innocuité de Bexsero chez les sujets sensibles à la kanamycine n'a pas été établie. Ce médicament contient moins de 1 mmol (23 mg) de sodium par dose, c'est-à-dire qu'il est essentiellement « sans sodium ». **Traçabilité:** Afin d'améliorer la traçabilité des médicaments biologiques, le nom et le numéro de lot du produit administré doivent être clairement enregistrés. **Effets indésirables: Résumé du profil de sécurité:** La sécurité de Bexsero a été évaluée lors de 17 études, dont 10 essais cliniques randomisés contrôlés portant sur 10 565 sujets (âgés de 2 mois minimum) ayant reçu au moins une dose de Bexsero. Parmi les sujets vaccinés par Bexsero, 6 837 étaient des nourrissons et des enfants (de moins de 2 ans), 1 051 étaient des enfants (entre 2 et 10 ans) et 2 677 étaient des adolescents et des adultes. Parmi les nourrissons ayant reçu les doses de primovaccination de Bexsero, 3 285 ont reçu une dose de rappel au cours de leur deuxième année de vie. Chez les nourrissons et les enfants (de moins de 2 ans), les réactions indésirables locales et systémiques les plus fréquemment observées lors des essais cliniques étaient: sensibilité et érythème au site d'injection, fièvre et irritabilité. Dans les études cliniques menées chez les nourrissons vaccinés à 2, 4 et 6 mois, la fièvre ( $\geq 38^\circ\text{C}$ ) était rapportée chez 69 % à 79 % des sujets lorsque Bexsero était coadministré avec des vaccins de routine (contenant les antigènes suivants: pneumocoque heptavalent conjugué, diphtérie, tétanos, coqueluche acellulaire, hépatite B, poliomyélite inactivée et *Haemophilus influenzae* de type b), contre 44 % à 59 % des sujets recevant les vaccins de routine seuls. Une utilisation plus fréquente d'antipyrétiques était également rapportée chez les nourrissons vaccinés par Bexsero et des vaccins de routine. Lorsque Bexsero était administré seul, la fréquence de la fièvre était similaire à celle associée aux vaccins de routine administrés aux nourrissons pendant les essais cliniques. Les cas de fièvre suivaient généralement un schéma prévisible, se résolvant généralement le lendemain de la vaccination. Chez les adolescents et les adultes, les réactions indésirables locales et systémiques les plus fréquemment observées étaient: douleur au point d'injection, malaise et céphalée. Aucune augmentation de l'incidence ou de la sévérité des réactions indésirables n'a été constatée avec les doses successives du schéma de vaccination. Liste tabulée des effets indésirables: Les effets indésirables consécutifs à la primovaccination ou à la dose de rappel) considérés comme étant au moins probablement liés à la vaccination ont été classés par fréquence. Les fréquences sont définies comme suit: Très fréquent: ( $\geq 1/10$ ) - Fréquent: ( $\geq 1/100$  à  $< 1/10$ ) - Peu fréquent: ( $1/1000$  à  $< 1/100$ ) - Rare: ( $1/10000$  à  $< 1/1000$ ) - Très rare: ( $< 1/10000$ ). Fréquence indéterminée: (ne peut être estimée sur la base des données disponibles). Dans chaque groupe de fréquence, les effets indésirables sont présentés par ordre de sévérité décroissante. Outre les événements rapportés lors des essais cliniques, les réactions spontanées rapportées dans le monde par Bexsero depuis sa commercialisation sont décrites dans la liste ci-dessous. Comme ces réactions ont été rapportées volontairement à partir d'une population de taille inconnue, il n'est pas toujours possible d'estimer de façon fiable leur fréquence. Ces réactions sont, en conséquence, listées avec une fréquence indéterminée. **Nourrissons et enfants (jusqu'à l'âge de 10 ans): Affections hématoLOGIQUES et du système lymphatique:** Fréquence indéterminée: lymphadénopathie. **Affections du système immunitaire:** Fréquence indéterminée: réactions allergiques (y compris réactions anaphylactiques). **Troubles du métabolisme et de la nutrition:** Très fréquent: troubles alimentaires. **Affections du système nerveux:** Très fréquent: somnolence, pleurs inhabituels, céphalée. Peu fréquent: convulsions (y compris convulsions fébriles). Fréquence indéterminée: épisode d'hypotonie-hyporéactivité, irritation des méninges (des signes d'irritation des méninges, tels qu'une raideur de la nuque ou une photophobie, ont été rapportés sporadiquement peu de temps après la vaccination. Ces symptômes ont été de nature légère et transitoire). **Affections vasculaires:** Peu fréquent: pâleur (rare après le rappel). Rare: syndrome de Kawasaki. **Affections gastrointestinales:** Très fréquent: diarrhée, vomissements (peu fréquents après le rappel). **Affections de la peau et du tissu sous-cutané:** Très fréquent: rash (enfants âgés de 12 à 23 mois) (peu fréquent après le rappel). Fréquent: rash (nourrissons et enfants âgés de 2 à 10 ans) - Peu fréquent: eczéma - Rare: urticaire. **Affections musculosquelettiques et systémiques:** Très fréquent: arthralgies. **Troubles généraux et anomalies au site d'administration:** Très fréquent: fièvre ( $\geq 38^\circ\text{C}$ ), sensibilité au niveau du site d'injection (y compris sensibilité sévère au site d'injection définie par des pleurs lors d'un mouvement du membre ayant reçu l'injection), érythème au site d'injection, gonflement du site d'injection, induration au site d'injection, irritabilité - Peu fréquent: fièvre ( $\geq 40^\circ\text{C}$ ) - Fréquence indéterminée: réactions au site d'injection (incluant un gonflement étendu du membre vacciné, vésicules au point d'injection ou autour du site d'injection et nodule au site d'injection pouvant persister pendant plus d'un mois). **Adolescents (à partir de 11 ans) et adultes:** Affections hématoLOGIQUES et du système lymphatique: Fréquence indéterminée: lymphadénopathie. **Affections du système immunitaire:** Fréquence indéterminée: réactions allergiques (y compris réactions anaphylactiques). **Affections du système nerveux:** Très fréquent: céphalée - Fréquence indéterminée: syncope ou réaction vasovagale à l'injection, irritation des méninges (des signes d'irritation des méninges, tels qu'une raideur de la nuque ou une photophobie, ont été rapportés sporadiquement peu de temps après la vaccination. Ces symptômes ont été de nature légère et transitoire). **Affections gastrointestinales:** Très fréquent: nausées. **Affections de la peau et du tissu sous-cutané:** Fréquence indéterminée: rash. **Affections musculosquelettiques et systémiques:** Très fréquent: myalgies, arthralgies. **Troubles généraux et anomalies au site d'administration:** Très fréquent: douleur au point d'injection (y compris douleur sévère au point d'injection définie par une incapacité à mener à bien des activités quotidiennes normales), gonflement du site d'injection, induration au point d'injection, érythème au site d'injection, malaise - Fréquence indéterminée: fièvre, réactions au site d'injection (incluant gonflement étendu du membre vacciné, vésicules au point d'injection ou autour du site d'injection et nodule au site d'injection pouvant persister plus d'un mois). **Déclaration des effets indésirables suspects:** La déclaration des effets indésirables suspects après autorisation du médicament est importante. Elle permet une surveillance continue du rapport bénéfice/risque du médicament. Les professionnels de santé déclarent tout effet indésirable suspecté via le système national de déclaration: **Belgique:** Agence Fédérale des Médicaments et des Produits de Santé - Division Vigilance - Boite Postale 97 - B-1000 Bruxelles - Madou - Site internet: [www.notifieruneffetindesirable.be](http://www.notifieruneffetindesirable.be) - e-mail: [adr@afmps.be](mailto:adr@afmps.be). **Luxembourg:** Centre Régional de Pharmacovigilance de Nancy - Bâtiment de Biologie Moléculaire et de Biopathologie (BBB) - CHRU de Nancy - Hôpitaux de Brabois - Rue du Morvan - 54 511 Vandœuvre Les Nancy Cedex - Tél.: (+33) 3 83 65 60 85 / 87 - e-mail: [crpv@chru-nancy.fr](mailto:crpv@chru-nancy.fr) ou Direction de la Santé - Division de la Pharmacie et des Médicaments - 20, rue de Bâlebourg - L-1273 Luxembourg-Hamm - Tél.: (+352) 2478 5592 - e-mail: [pharmacovigilance@ams.etat.lu](mailto:pharmacovigilance@ams.etat.lu) - Link pour le formulaire: <https://guichet.public.lu/fr/entreprises/factoriel/sante/medicaments/modification-effets-indesirables-medicaments.html>. **TITULAIRE DE L'AUTORISATION DE MISE SUR LE MARCHÉ:** GSK Vaccines S.r.l., Via Fiorentina 1, 53100 Siena, Italie. **DATE D'APPROBATION DU TEXTE:** 25/02/2022 (v13). **MODE DE DELIVRANCE:** Sur prescription médicale. **Référence:** SmPC Bexsero

PM-BE-BEX-ADVT-210007 - Juillet 2021 | E.R.: GlaxoSmithKline Pharmaceuticals s.a./n.v.  
Site Apollo Avenue Pascal, 2-4-6 1300 Wavre Belgium



## Case Report

# Self-Limiting Sternal Tumour of Childhood: a case report

Saskia Schipper<sup>a,b</sup>, Kirsten de Schaetzen<sup>a</sup>

<sup>a</sup>Department of Paediatrics, Ziekenhuis Oost-Limburg, Genk, Belgium.

<sup>b</sup>Department of Paediatrics, UZ Brussel, Vrije Universiteit Brussel, Belgium.

Saskiaschipper90@gmail.com

### Keywords

Sternal mass; SELSTOC; ultrasound; paediatrics

### Abstract

A child presenting with a sternal mass is rare. Here, we present a case report of a toddler with an acute sternal mass. At first, antibiotics were started as the differential diagnosis included osteomyelitis. However, the combination of young age, typical clinical characteristics and dumbbell-shaped appearance on ultrasound led to the diagnosis of self-limiting sternal tumour of childhood. To prevent invasive diagnostic interventions and unnecessary treatment, it is important to be able to identify the clinical features and ultrasound characteristics of this benign entity.

### Case presentation

A 3-year old girl presented to the emergency department with signs of bronchitis. The evening before presentation, the parents had noticed a sternal swelling located at the xiphoid process. There was no history of trauma, she did not have a fever, nor was there a history of weight loss. On clinical examination, there was a solid swelling and the overlying skin had a red appearance (figure 1). Palpation seemed painful. No other abnormalities such as hepatosplenomegaly or lymphadenopathy were found.

Diagnostic evaluation demonstrated a marginally elevated C-reactive protein (13,6 mg/L, normal range <5,0 mg/L). X-ray imaging performed in the context of her respiratory symptoms revealed presternal tissue swelling without any periosteal reaction (figure 2 - A). On ultrasound, a hypo-echoic, sharply demarcated swelling of the soft tissue caudal to the sternum was observed. The lesion was dumbbell-shaped with a presternal, subcutaneous component and a spur to a retrosternal component (figure 2 - B). There was no sign of inflammation nor was there internal vascularization. With an abscess

and osteomyelitis in the differential diagnosis, it was decided to commence with intravenous Amoxicillin/Clavulanic acid. To further investigate the lesion, an MRI (magnetic resonance imaging) was performed that demonstrated a structure on the caudal side of the sternum with a subcutaneous component which was connected to a smaller intrathoracic component without intrapleural or intrapericardial extension (figure 2 - C). Considering these imaging results, the relative asymptomatic presentation of the lesion and the typical dumbbell-sign on ultrasound, the diagnosis of Self-Limiting Sternal Tumour of Childhood (SELSTOC) was made. Antibiotics were stopped and she was discharged. The swelling disappeared spontaneously within a month after diagnosis. Repeat ultrasound examinations every two months demonstrated spontaneous involution of the lesion within 6 months after diagnosis.

### Discussion

Sternal masses are infrequently encountered in childhood. Differential diagnosis is varied and includes both benign and malignant causes, as demon-

Figure 1 : Sternal mass with red discoloration of the skin

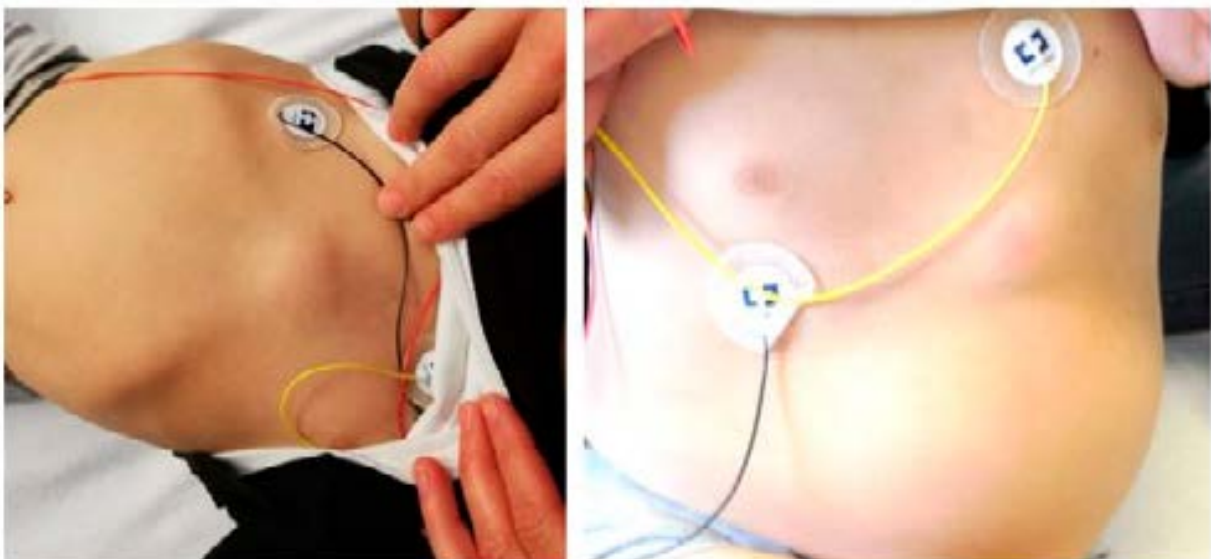
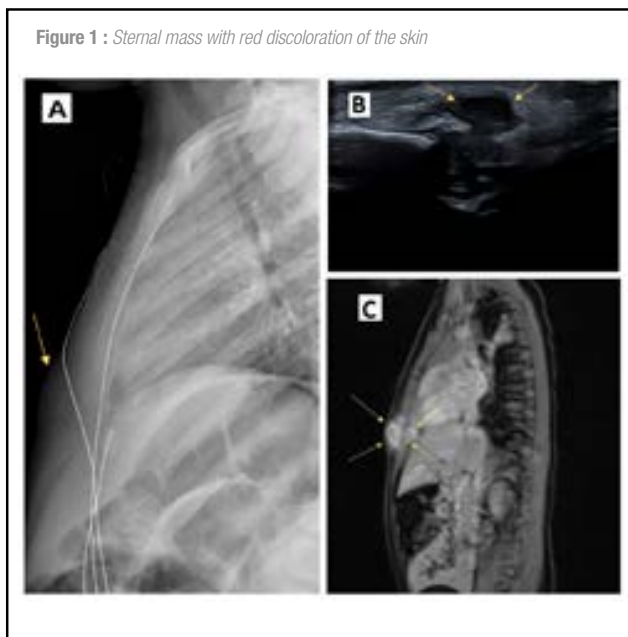


Figure 1 : Sternal mass with red discoloration of the skin



strated in table 1. Sternal tumours may arise from various tissues such as the subcutaneous soft-tissue, cartilage, bone or extra-pleural region. They may also arise from systemic diseases affecting connective tissue (1-3).

Rapidly growing sternal masses may raise the suspicion of malignancy, possibly leading to the performance of invasive diagnostic procedures. In a case series regarding self-limiting sternal tumours of childhood (SELSTOC) from 2010, it was reported that among approximately 1200 newly diagnosed paediatric malignancies in the Netherlands, there were no sternal malignant tumours (3). Therefore, to prevent unnecessary biopsies and invasive surgery, it is important to be able to distinguish malignant from benign processes. Self-limiting sternal tumours of childhood are benign processes that are asymptomatic and do not show any signs of local or systemic inflammation, in contrast with osteomyelitis. The aetiology is still unclear. As patients most often have no history of infection, trauma or neoplasms, it is postulated that the most likely aetiology is an aseptic inflammatory reaction to a stimulus of unknown origin such as a mild trauma (4). Another hypothesis applicable to our case is that the coughing associated with bronchitis led to raised intrathoracic pressure, thereby causing herniation of mediastinal fat (5). Median age is reported to be 16 months with a range between 7 and 50 months (3).

Ultrasonography is considered the most appropriate imaging examination for the diagnosis, even though most previously published case reports reported using other additional forms of radiological techniques such as CT, most likely due to a lack of knowledge regarding the existence of SELSTOC. Ultrasound is a non-invasive method which does not require sedation, as often needed for CT or MRI imaging in toddlers. However, to diagnose SELSTOC, paediatric radiologists should be aware of it and should look for the typical ultrasound findings, which include a dumbbell shape with a retrosternal component, a neck between the sternum and the cartilage of the adjacent rib, and a presternal component. Colour doppler ultrasound does not show any significant internal vascularisation, in contrast with abscesses that are known to show thicker, more echogenic contents with profuse vascularity (5, 6). Having had no knowledge of the specific ultrasound characteristics of SELSTOC, we decided upon performing an MRI to further investigate the lesion to rule out osteomyelitis. However, osteomyelitis would have shown either irregular margins or cortical irregularity on ultrasound (7). Therefore, retrospectively, performing an MRI would have not been necessary, had we known what to look for.

Literature regarding management of SELSTOC is rare and mainly consists of case reports. It is suggested that the combination of young age, sternum-related localization, rapid growth, typical radiological findings, lack of general illness and lack of other abnormalities on physical examination and biochemical evaluation justifies a wait-and-see approach. Close monitoring by repeat ultrasound is advised, especially in the first weeks after presen-

tation. One case series from 2013 suggested a first follow-up ultrasound after 2-3 weeks, the next 1 month later and widening intervals thereafter (8). Spontaneous resolution is expected after an average of 6 months.

## Conclusion

In conclusion, our case of a young child with a benign sternal aseptic inflammation represents an entity named SELSTOC. By recognizing the combination of young age, typical clinical characteristics, and typical dumbbell-shaped appearance on ultrasound, unnecessary diagnostic procedures and treatment may be prevented.

## Informed consent

The family provided verbal consent to publish, and identifying information was excluded from the manuscript.

## Conflict of interest

The authors have no conflicts of interest to declare.

## REFERENCES:

1. Ketharanathan, N., te Winkel, M.L., Lequin, M.H., van den Heuvel-Eibrink, M.M. Een zuigeling met een sternale zwelling. *Ned Tijdschr Geneeskd.* 2011; 155: A3981.
2. Baez, J.C., Lee, E.Y., Restrepo, R., Eisenberg, R.L. Chest Wall Lesions in Children. *American Journal of Roentgenology.* 2013; 200: W402-W419.
3. Te Winkel, M.L., Lequin, M.H., de Bruyn, J.R., van de Ven, C.P., de Krijger, R.R., Pieters, R., et al. Self-Limiting Sternal Tumors of Childhood (SELSTOC). *Pediatr Blood Cancer* 2010; 55: 81-84.
4. Alonso Sanchez, J., Gallego Herrero, C., Garcia Prieto, J., Cruz-Conde, M.C., Casado Perez, C., Rasero Ponferrada, J., et al. Self-limiting sternal tumors of childhood (SELSTOC): a diagnostic challenge. *Radiologia* 2020; S0033-8338(20)30064-3.
5. Verhaeghe, L., & Herman, M. Subacute Sternal Mass in Childhood. *Journal of the Belgian Society of Radiology.* 2019; 103(1).
6. Grover, D.S.B., Rai, D.V., Grover, D.H., Kumar, D.D., Kundra, D.R., Gautam, D.V., Devra, D.A.G. Imaging diagnosis of sternal tuberculosis – A report of two cases of the ancient disease with a new demeanour. *Radiology Case Reports* 2021; 16: 3125 – 3133.
7. Eyer, M.M., Constatinescu, M., Sendi, P. Primary sternal tuberculosis: a case report and review of the literature. *JMM Case Reports* 2014; 1 (2).
8. Ilivitzki, A., Sweed, Y., Beck, N., Militaianu, D. Sternal pseudotumor of childhood. *Journal Ultrasound Med* 2013; 32: 2199-2203.

## Case Report

# The medical and ethical challenges of extremely low birth weight infants with severe comorbidity: a case report of a 26 weeks old neonate with Maple Syrup Urine Disease

Phebe Debouver<sup>a</sup>, Lara Garabedian<sup>b</sup>, Patrick Verloo<sup>c</sup>, Annelies Keymeulen<sup>b</sup>

<sup>a</sup> Department of Pediatrics, Ghent University Hospital, Ghent, Belgium

<sup>b</sup> Department of Neonatology, Ghent University Hospital, Ghent, Belgium

<sup>c</sup> Department of Pediatric Neurology and Metabolic Disorders, Ghent University Hospital, Ghent, Belgium

phebe.debouver@uzgent.be

### Keywords

Case Report; Ethics; Extremely Low Birth Weight; Maple Syrup Urine Disease; Prematurity

### Abstract

Infants born extremely preterm or with extremely low birth weight (ELBW) are at high risk of death and severe morbidity. We present a patient born at 26 weeks' gestation with severe intrauterine growth restriction (IUGR) and Maple Syrup Urine Disease (MSUD). The need for enteral feeding in MSUD patients and the practical and medical infeasibility of performing hemodialysis in our ELBW neonate substantially decreased therapeutic options. If severe comorbidity further complicates the care for ELBW infants, therapeutic options might be limited. Ethical considerations need to be taken into account when deciding on the best outcome for the individual neonate.

### Introduction

Despite technological advances and efforts of child health experts over the last decades, extremely preterm infants (i.e., those with gestational age less than 28 weeks) and extremely low birth weight infants (ELBW; birth weight less than 1000 grams) remain at high risk for death and disability with 30–50% mortality and, in survivors, at least 20–50% risk of morbidity (1). Currently, some extremely preterm infants survive from 22 weeks' gestation. However, the risk for longer-term neuro-disability including cerebral palsy and severe cognitive impairment is significant (2). When infants born extremely preterm or with ELBW are diagnosed with a co-existing congenital anomaly, this has an enormous impact on their already compromised prognosis. In these situations, caregivers are confronted with supplementary therapeutic challenges, ethical problems and a difficult counseling of the parents. To our knowledge, we present the first case of an ELBW infant with Maple Syrup Urine Disease (MSUD). Below, we will discuss the medical and ethical difficulties encountered in this case.

### Case presentation

At 26 weeks' gestation, an urgent caesarean section was performed in a 23-year old woman with sudden vaginal blood loss due to retroplacental hematoma. Ultrasound monitoring revealed severe intrauterine growth restriction (IUGR) with end-diastolic block and suboptimal cardiotocogram. No previous ultrasounds were available since the pregnancy was unmonitored. Because of the prognostic impact of IUGR accompanying severe prematurity, urgent prenatal counseling was performed. During counseling, both parents expressed their wish for maximal beneficial intervention.

Prenatal lung maturation was initiated but incomplete. Birth weight of the female infant was 475 grams (third percentile). Heart activity at birth was sufficient but intubation and invasive ventilation were needed due to severe respiratory distress syndrome. Clinical Risk Index for Babies II score (CRIB II) was 12, which corresponds to a predicted death rate of 25.4%. Hemodynamic support with dobutamine, dopamine and norepinephrine was initiated. A single dose of dexamethasone was given with short, refractory result. Antibiotic treatment was commenced on day seven after a rise of infection parameters. Brain ultrasound performed on a daily basis from the first until the fifth day of life revealed severe immaturity with bilateral intraventricular

hemorrhage. Hypoglycemia up to 33 mg/dL on the first day of life urged an increase in carbohydrate intake via total parenteral nutrition (TPN). Hyperbilirubinemia required phototherapy and the initial hypernatremia as seen in extreme prematurity was followed by the need for sodium, potassium and phosphorus supplementation. Minimal enteral feeding was initiated on day two, supplemented with TPN as the main caloric source. On day 14, while still receiving invasive ventilation and hemodynamic support, our patient's blood spot screening test revealed elevated leucine and valine levels. Plasma analysis in our laboratory confirmed a leucine level of 3482 mcmol/L (45–263 mcmol/L) and a valine level of 384 mcmol/L (92–326 mcmol/L), suggestive of MSUD. Therefore, dietary measures were commenced and oral feeding was provided through amino acid supplementations free of branched-chain amino acids (BCAAs) with strict carbohydrate index calculation (10–12 mg/kg/min). To promote an anabolic state, glucose and insulin infusions were administered guided by frequent screening for ketonuria. Thiamine supplementation was started. Since our patient was not diagnosed on clinical grounds, no urinary organic acid analysis was performed. Lactate levels were mildly elevated (maximal value of 3.45 mmol/L). From day seven onwards, brain ultrasound showed increasing hyperintensity of the deep nuclei, presumably due to brain edema caused by MSUD. On day 17, increasing brain edema and refractory hypotension with anuria emerged. In absence of any curative perspective, the option of palliative care was discussed with the parents. Because they firmly expressed their wish for continued maximal support, the team of neonatologists decided to continue but not to further expand life-sustaining treatment and not to perform reanimation (DNR 2). On day 18, our patient deceased as a result of bradycardia and increasing hypotension resulting in asystole. Gene panel analysis of our patient and both consanguineous parents later revealed a homozygous nonsense variant in the *DBT* (dihydrolypoamide branched chain transacylase E2) gene, which is seen in MSUD (type II).

### Discussion

The well-known inverse relationship between gestational age at birth and morbidity among survivors has been well established (1,2). In 2009, a national framework was published by the British Association of Perinatal Medicine (BAPM) to support extremely preterm birth perinatal care decision-making.

The framework indicated active treatment should not normally be attempted below 23 weeks' gestation and should be attempted from 24 weeks onwards unless severe infant compromise was anticipated. A revised 2019 BAPM Framework for Practice recommends that Active Treatment from 22 weeks' gestation may be appropriate after risk assessment and consideration of parental views. It emphasises that decision-making must be led by senior obstetric and neonatal staff and in full consultation with parents (2). To guide the decision whether to initiate intensive care or not, different prognostic models were designed, of which the National Institute of Child Health and Human Development Neonatal Research Network (NICHD-NRN) estimator is one of the more well-known tools (via <https://www.nichd.nih.gov/research/supported/EPBO/use>) (3). Predictor variables are gestational age, birth weight, gender, singleton birth and antenatal steroid treatment. Prognostic models are helpful tools in prenatal counseling (4). A NICHD-NRN score was not calculated for our ELBW patient with IUGR since gestational age exceeded 25 weeks. In our center, initiation of intensive care is considered starting from 24 weeks' gestation and prenatal counseling is provided at multiple occasions when early or extreme prematurity is expected or in the case of congenital conditions. In this case, the serious medical and ethical concerns regarding the combination of extreme prematurity and IUGR were communicated to the parents.

As a part of postnatal risk assessment, CRIB II score (via <https://sfar.org/espace-professionnel-anesthese-reanimateur/outils-professionnels/scores-sfar/>) (5) in our patient was 12, which corresponds to a predicted death rate of 25.4%. Our patient's prognosis was further compromised by an inborn error of metabolism. Since the rarity of extreme prematurity and complex diseases limits extensive study, literature on extremely preterm or ELBW neonates with inborn errors of metabolism is scarce. MSUD is an autosomal recessive organic aciduria that affects the body's ability to metabolize BCAAs: leucine, isoleucine and valine. Acute elevations of leucine and alpha-ketoisocaproic acid can cause life-threatening metabolic encephalopathy and critical brain edema (6). Treatment consists of high caloric supplementation to suppress catabolism, stopping protein intake, strict monitoring of BCAA levels, correction of metabolic abnormalities (hypoglycemia, metabolic acidosis, hyperammonemia) and monitoring sodium level to prevent cerebral edema (6,7). Keeping in mind the increased risk for false-positive results on blood spot screening test in preterm infants due to immaturity of enzymes involved in metabolic pathways or clinical interventions such as TPN (7), urgent plasma amino acid testing was performed. By the time of confirmation of diagnosis, there was already hyperintensity of the deep nuclei on brain ultrasound. A leucine-free diet was initiated on day 14 but enteral feeding was not well tolerated. In the absence of suitable alternatives for enteral feeding, this imposed serious treatment difficulties. Hemodialysis could be a suitable treatment option to remove the BCAAs rapidly, but was not considered possible in our ELBW patient. In literature, despite advancing techniques, reports about successful hemodialysis in the ELBW and VLBW population are scarce as a result of difficult blood access and large extracorporeal circuits relative to an infant's blood volume (8). Peritoneal dialysis (PD) is technically feasible and effective in extremely immature infants (9). To our knowledge, however, no cases of successful PD in neonates with birth weights less than 500 grams have been described.

As a result of the combination of feeding difficulties in the absence of a leucine-free parenteral feeding mix with the infeasibility to perform dialysis in our ELBW neonate, further treatment was no longer feasible or meaningful. Despite advances in life-saving technology for critically ill neonates, challenges continue to rise for infants delivered with extreme prematurity or congenital conditions that exceed the limits of currently available interventions. In these situations, parents face extremely difficult decisions. Parents are reported wishing to save their infant at all costs, regardless of the projected outcome, more frequently than physicians do. Hope, spirituality and compassion tend to outweigh clinical data in some cases and parents and former patients are less likely to rate disability as worse than death compared to their physicians. Furthermore, input from family members and religious beliefs are among the most highly influential factors when making these decisions (10). A helpful practical tool for ethical decision-making in neonatology is the I-P-O (impermissible-permissible-obligatory) framework (11). When applied to our patient, ethically permissible options ranging from maximal beneficial

intervention through palliative care were proposed and discussed at multiple occasions. As a result of lack of therapeutic perspective despite (near) maximal intensive care, the obligatory decision was made not to further expand therapy and not to reanimate.

Our case is an extreme example of therapeutic limitations in ELBW infants with severe metabolic disorders. Even though there were no curative options, the question could be raised how far we are willing to go in other extremely preterm or ELBW infants with severe comorbidity. Even in the absence of treatment impossibility, (future) quality of life needs to be taken into account when deciding on whether to continue active treatment or not. Especially with rapidly advancing techniques, we must be careful to guard the meaningfulness of foregoing life-sustaining treatment. It is clear that more research is needed regarding outcomes of extreme prematurity with severe comorbidity in order to correctly address these ethical concerns.

## Take-home message

If severe comorbidity further complicates the care for extremely preterm or ELBW infants, therapeutic options can be limited. The rarity of extreme prematurity and severe congenital conditions limits extensive study, which causes prognostic uncertainty and results in difficult prenatal counseling. Ethical considerations need to be taken into account when deciding on the best outcome for the neonate.

**Competing interests:** Authors state no conflict of interest.

**Informed consent:** Informed consent was obtained from all individuals included in this study.

## REFERENCES:

1. Glass HC, Costarino AT, Stayer SA, Brett C, Cladis F, Davis PJ. Outcomes for extremely premature infants. *Anesth Analg*. 2015; 120(6):1337–1351.
2. Di Stefano LM, Wood K, Mactier H, Bates SE, Wilkinson D. Viability and thresholds for treatment of extremely preterm infants: survey of UK neonatal professionals. *Arch Dis Child Fetal Neonatal Ed*. 2021;106:F596–F602.
3. NICHD Neonatal Research Network. Extremely Preterm Birth Outcomes Tool [Internet]. Bethesda (MD): National Institute of Child Health and Human Development (US); [reviewed 2020 Feb 3; cited 2021 Dec 17]. Available from: <https://www.nichd.nih.gov/research/supported/EPBO/use>
4. Myers P, Andrews B, Meadow W. Opportunities and difficulties for counseling at the margins of viability. *Seminars in fetal & neonatal medicine*. 2018;23(1):30–4.
5. SFAR Clinical Risk Index for Babies II (CRIB II) [Internet]. Paris (FR): Société Française d'Anesthésie et de Réanimation; [reviewed 2008 Mar 14; cited 2021 Dec 17]. Available from: <https://sfar.org/espace-professionnel-anesthese-reanimateur/outils-professionnels/scores-sfar/>
6. Strauss KA, Carson VJ, Soltys K, Young ME, Bowser LE, Puffenberger EG, et al. Branched-chain alpha-ketoacid dehydrogenase deficiency (maple syrup urine disease): Treatment, biomarkers, and outcomes. *Molecular genetics and metabolism*. 2020;129(3):193–206.
7. Fabie NAV, Pappas KB, Feldman GL. The Current State of Newborn Screening in the United States. *Pediatr Clin N Am*. 2019;66(2):369–386.
8. Spector BL, Misurac JM. Renal Replacement Therapy in Neonates. *NeoReviews*. 2019;20(12):e697–e710.
9. Burgmaier K, Hackl A, Ehren R, Kribs A, Burgmaier M, Weber LT, et al. Peritoneal dialysis in extremely and very low-birth-weight infants. *Peritoneal dialysis international: journal of the International Society for Peritoneal Dialysis*. 2020;40(2):233–6.
10. Kukora SK, Boss RD. Values-based shared decision-making in the antenatal period. *Seminars in fetal & neonatal medicine*. 2018;23(1):17–24.
11. Mercurio MR, Cummings CL. Critical decision-making in neonatology and pediatrics: the I-P-O framework. *J Perinatol*. 2021;41:173–178.

# ANTHELIOS DERMO-PEDIATRICS 50+

EEN VOLLEDIG GAMMA OM DE KWETSBARE HUID  
VAN KINDEREN EN BABY'S TE BESCHERMEN

**BESCHERM HUN HUID VAN JONGS AF AAN.**



## ZEER EFFICIËNT

- Breedspectrum zonnebescherming : UVB & UVA
- Fotostabiliteit
- Zeer waterresistent



## UITSTEKENDE TOLERANTIE

- Getest onder toezicht van pediaters
- Kinderen met een gevoelige huid met neiging tot atopie



## AANGEPASTE TEXTUREN

- Gemakkelijk aan te brengen voor een uniforme applicatie
- Dringen snel in. Geen witte schijn
- Prikken niet in de ogen

**NIEUW**  
**Eco-pack**



**MELK**  
**PPD 38**

30ml CNK: 3622-248  
100ml CNK: 2737-872  
250ml CNK: 3478-674



**WET SKIN**  
**PPD 25**

250ml CNK: 3478-690



**SPRAY**  
**PPD 36**

200ml CNK: 3969-185




**AEROSOL**  
**PPD 36**

125ml CNK: 3969-193



**BABY**  
**PPD 39**

50ml CNK: 3173-143



## Case Report

# Borrelial Lymphocytoma in children: don't miss this skin marker of Lyme Disease

Violette Kaisin<sup>a,b,d</sup>, Marie Hoyoux<sup>b</sup>, Sandrine Vaessen<sup>c</sup>, Vincent Bernier<sup>a</sup>

<sup>a</sup> Paediatric Dermatology, Department of Paediatrics, CHC-Montlégia, Liège, Belgium.

<sup>b</sup> Paediatric Infectious Diseases, Department of Paediatrics, CHU-CHR, Liège, Belgium.

<sup>c</sup> Paediatric Neurology, Department of Paediatrics, CHU-CHR, Liège, Belgium.

<sup>d</sup> Fifth year of specialized Master in Paediatrics, Medicine Faculty, Liège University, Belgium.

violette.kaisin@chuliege.be

### Keywords

Lyme Disease, lymphocytoma, *Borrelia burgdorferi*

### Abstract

Borrelial lymphocytoma is a rare but pathognomonic cutaneous manifestation of Lyme disease. It mainly occurs in the early disseminated stage (secondary stage). Here we report two cases of borrelial lymphocytoma in children. Furthermore, the steps to the diagnosis as well as the treatment are discussed.

### Introduction

Lyme disease or Lyme borreliosis is a systemic disease caused by the spirochete *Borrelia burgdorferi* sensu lato (*B. afzelii*, *B. garinii* et *B. burgdorferi* sensu stricto in Europe (1)). This spirochete is transmitted to humans by ticks, most frequently by *Ixodes ricinus* in Europe (1). The clinical manifestations can vary and are divided into three stages: the first stage with early localized manifestations that appear a few days to a few weeks after the tick bite, the second stage with early disseminated manifestations that appear several weeks to several months after the bite, and the third stage with late disseminated manifestations appearing months or even years after the contamination (2).

The incidence of Lyme disease in Belgium is difficult to assess due to the multiple clinical presentations. In 2018, 90.3 per 100,000 people consulted their general practitioner with erythema migrans, a clinical manifestation of the early localized stage of Lyme borreliosis for which serological testing is not necessary to confirm the diagnosis (3). Furthermore, a study by Lernout et al. on blood samples from July 2013 to January 2015, shows a seroprevalence for *B. Burgdorferi* sensu lato of 1.06% (4). The number of hospitalizations for Lyme disease in Belgium was around 300 patients per year from 2010 to 2014 (2).

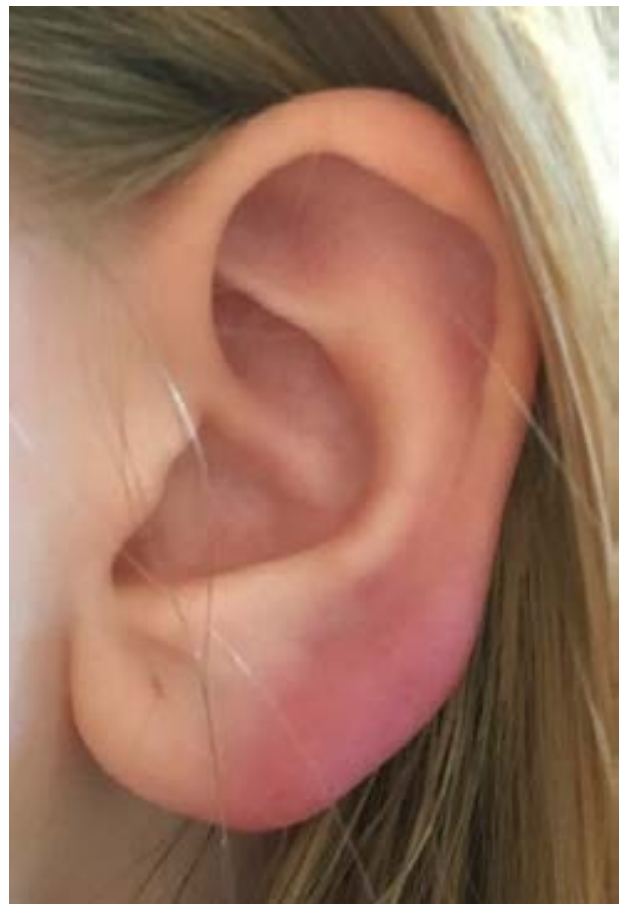
Borrelial lymphocytoma is a cutaneous manifestation that essentially appears in the second stage of Lyme disease, from the 10th day to 6 months after the tick bite according to sources (1,5-6). It is a 1-5 cm bluish, erythematous or purplish nodule usually localized on the earlobe in children and in the nipple area in adults (7). It can also be found in other areas of the body. This symptom can be found in 0.9-5% of patients with Lyme disease (6,8). It is more frequent in children than in adults occurring in 7% of the cases (5,9). Borrelial lymphocytoma is a clinical manifestation of Lyme disease caused by *B. afzelii* or *B. garinii* (1,5). These species are almost exclusively present in Europe, making this symptom endemic in Europe (1,5).

We here report two cases of borrelial lymphocytoma in children.

### Case reports

A 7-year-old girl, with no particular medical history, presented with a 5-month recurrent erythema and swelling of the left earlobe, sometimes associated with itching (Figure 1). A transient erythema on the left cheek gradually

Figure 1 : borrelial lymphocytoma of the left earlobe.



spread over the entire left side of the face at the same time. About 4 months later, the patient developed fatigue and daily left-parietal headaches. The ENT examination, ophthalmologic check-up and the cerebral MRI were unremarkable. Two blood serologies for *Borrelia burgdorferi* sensu lato performed 15 days apart, proved positive for IgG and negative for IgM. No personal history of tick bite was reported. With these typical clinical manifestations and the serological results, the diagnosis of borrelial lymphocytoma was made. A lumbar puncture was performed, revealing an elevated white blood cell count as well as an intrathecal secretion of anti-Borrelia IgG. This revealed an associated neuroborreliosis. Treatment by intravenous cefotaxime (200mg/kg/day) was given followed by oral doxycycline (4mg/kg/day) for a total period of 28 days. Fifteen days after starting the antibiotherapy, the earlobe nodule and the headaches disappeared, and the erythema of the face appeared less frequently.

A previously healthy 8-year-old boy sought medical advice as he presented with a one-month non-pruritic, painless purple nodule, located on the left breast areola (Figure 2). An erythema surrounding the nodule and an annular erythema on the left side of the patient's back appeared about 15 days later. There was no history of a tick bite but the patient had attended a summer scout camp a few months earlier. On biological testing, anti-Borrelia titers were positive for IgG and negative for IgM. The diagnosis of borrelial lymphocytoma was made and a treatment by amoxicillin (500 mg 4 times a day) was started for a total of 3 weeks. After 15 days of antibiotherapy, the erythema had disappeared and the size of the nodule diminished. The good response to the treatment confirmed the diagnosis.

## Discussion

The diagnosis of borrelial lymphocytoma is mainly based on clinical examination, combined with a history of tick bite(s) or of visiting places where there is a risk of being exposed. Serological testing helps to confirm the diagnosis. A two-tier approach is recommended with an enzyme immunoassay confirmed by immunoblotting (6,8-10). However, it can initially be negative, turning positive afterwards. It is sometimes necessary to perform a skin biopsy for differential diagnosis if the history is not typical, for example if there is no response on antibiotics, and serologies are not helpful. Indeed, this type of lesion can also be seen in lymphomas, cutaneous lupus, sarcoidosis and other dermatological disorders (8). Histological analysis shows lymphocytic inflammatory infiltration of the dermis with plasmocytes and lymphoid germinative centres (1,5,8). Search for the spirochete via PCR or culture can also be done on the biopsy but the sensitivity is variable (1,6,8).

The duration of the therapy should be 2 weeks if the borrelial lymphocytoma is the only sign of presentation (10). The choice of the antibiotic depends on the age of the patient and other criteria listed in the table below (Table 1).

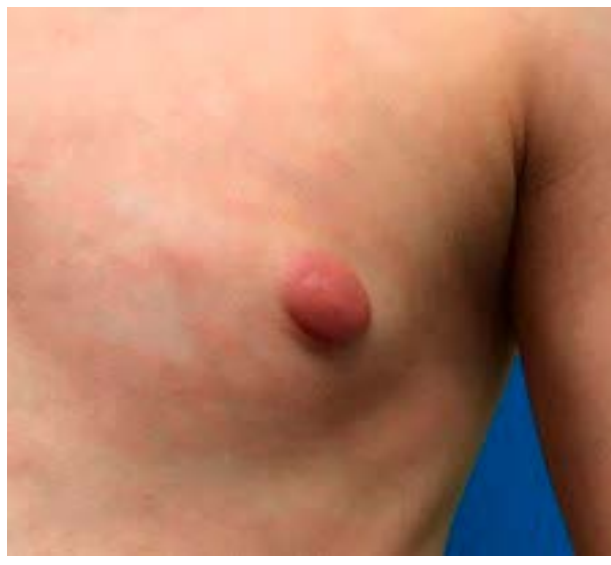**Table 1:** antibiotic type and dosage in the treatment of borrelial lymphocytoma (1). Duration of treatment is of 14 days (10).

Population	Antibiotic	Dosage	Maximum dosage
7-8 years or older	Doxycycline	4 mg/kg/day	200 mg/day
- Younger than 7-8 years	Cefuroxime	30 mg/kg/day	1000 mg/day
- Allergy to doxycycline	Amoxicillin	50 mg/kg/day	1500 mg /day
- Pregnancy or breast-feeding			

With appropriate antibiotics, the lymphocytoma disappears within 2 weeks to 2 months with a mean of one month, as in our two cases (6,10).

If other signs or symptoms are associated, the duration of the treatment as well as the route of administration may vary, which was the case for our first patient who had concomitant neuroborreliosis.

**Figure 2 :** borrelial lymphocytoma of the nipple.



It is important to ensure follow-up after the initiation of antibiotherapy to make sure of efficacy. If treatment doesn't work, it is necessary to revise the differential diagnosis.

## Conclusion

Borrelial lymphocytoma is a rare, easily misdiagnosed but pathognomonic cutaneous manifestation of Lyme disease in Europe. It is important to make appropriate diagnosis to start treatment as soon as possible and to avoid progression towards a later stage of the disease, for example neuroborreliosis. A thorough anamnesis, the features and localisation of the nodule, serological testing and follow-up ensuring a good response to the treatment are so many keys for diagnosis and can avoid unnecessary biopsy.

## REFERENCES:

- Cardenas-de la Garza J, De la Cruz-Valadez E, Ocampo-Candiani J, Welsh O. Clinical spectrum of Lyme disease. *Eur J Clin Microbiol Infect Dis.* 2019;38(2):201-208.
- Lernout T, Patteet S, Lagrou K, Saegeman V, Quoilin S. Borréliose de Lyme (*Borrelia burgdorferi* s.l.). In : Rebolledo J, Litzroth A, Tersago K, Van Beckhoven D, Lernout T, editors. Zoonoses et maladies à transmission vectorielle, surveillance épidémiologique en Belgique 2015-2016 [Internet]. Brussels : WIV-ISP ; 2017 ; p74-84 [cited 2021 Mar 24]. Available from : <https://epidemiology.wiv-isp.be/ID/reports/Zoonoses%20et%20maladies%20à%20transmission%20vectorielle%20-%20Epidémiologie%20-%20Rapport%20annuel%202015-2016.pdf>.
- Lernout T, Depypere K, Lagrou K, Van Cauteren D, Kabamba-Mukadi B. Surveillance épidémiologique de la borréliose de Lyme *Borrelia burgdorferi* s.l. [Internet]. Brussels : Sciensano ; - 2018 [cited 2021 Mar 24]. Available from : [https://epidemiology.wiv-isp.be/ID/diseases/Documents/Reports%202018/Lyme\\_2018\\_fr.pdf](https://epidemiology.wiv-isp.be/ID/diseases/Documents/Reports%202018/Lyme_2018_fr.pdf).
- Lernout T et al. The value of seroprevalence data as surveillance tool for Lyme borreliosis in the general population: the experience of Belgium. *BMC Public Health.* 2019 May 17;19(1):597.
- Maraspin V, Klevisar M, Ruzic-Sabljic E, Lusa L, Strle F. Borrelial Lymphocytoma in Adult Patients. *Clin Infect Dis.* 2016;63(7):914-921.
- Belkhir L, Delaere B, De Loof G, De Munter P, Frippiat F, Jacobs F, et al. Borréliose de Lyme (infection à *Borrelia*) [Internet]. Brussels : BAPCOC ; 2016 [cited 2021 Mar 24]. Available from : [https://overlegorganen.gezondheid.belgie.be/sites/default/files/documents/guide-lyme\\_borreliose\\_fr\\_2016\\_8dec.pdf](https://overlegorganen.gezondheid.belgie.be/sites/default/files/documents/guide-lyme_borreliose_fr_2016_8dec.pdf).
- Stanek G, Fingerle V, Hunfeld K-P, Jaulhac B, Kaiser R, Krause A, et al. Lyme borreliosis: Clinical case definitions for diagnosis and management in Europe. *Clin Microbiol Infect.* 2011;17(1):69-79.
- Borchers A, Keen C, Huntly A, Gershwin ME. Lyme disease: A rigorous review of diagnostic criteria and treatment. *J Autoimmunity.* 2015;57:82-115.
- Godar D, Laniosz V, Wetter D. Lyme Disease Update for the General Dermatologist. *Am J Clin Dermatol.* 2015;16(1):5-18.
- Lantos PM, et al. Clinical Practice Guidelines by the Infectious Diseases Society of America (IDSA), American Academy of Neurology (AAN), and American College of Rheumatology (ACR): 2020 Guidelines for the Prevention, Diagnosis and Treatment of Lyme Disease. *Clin Infect Dis.* 2021 ;72(1):e1-e48.

## Case Report

# Familial hemophagocytic lymphohistiocytosis type 3: case report

Laure Guérit <sup>a</sup>, Samuel Balbeur <sup>a,b</sup>, Nathalie Bilem <sup>a</sup>, Bénédicte Brichard <sup>b</sup>, Cécile Boulanger <sup>b</sup>

<sup>a</sup>Department of Pediatrics, Clinique Saint-Pierre Ottignies, Belgium

<sup>b</sup>Department of Pediatric Hematology and Oncology, Cliniques universitaires Saint-Luc, Brussels, Belgium

dr.lguérit@gmail.com

### Keywords

Familial hemophagocytic lymphohistiocytosis, UNC13D, pancytopenia, case report

### Abstract

Hemophagocytic lymphohistiocytosis (HLH), including familial hemophagocytic lymphohistiocytosis (FHLH), is a rare and underdiagnosed syndrome of excessive immune activation which can be fatal if not treated. We report the case of a previously healthy 13-month-old girl who presented with prolonged fever, anaemia and hepatosplenomegaly, and then developed pancytopenia and biological signs of extreme inflammation. Genetic tests showed mutations in UNC13D gene, involved in FHLH type 3. Patient was treated with immunochemotherapy and underwent hematopoietic stem cell transplantation (HSCT). Awareness of this disease is crucial to make rapid diagnosis, in order to initiate a prompt treatment and quickly proceed to HSCT.

### Introduction

Hemophagocytic lymphohistiocytosis (HLH) is a rare and life-threatening syndrome, caused by excessive generation of inflammatory cytokines. There are two forms of HLH: primary HLH, encompassing several genetic diseases in which HLH is the predominant clinical manifestation, and secondary HLH, which is mainly driven by acquired or environmental mechanisms, such as rheumatic disease, malignancy, infection, or drugs (1). Diagnosis is based on a combination of several nonspecific signs and symptoms of extreme hyperinflammation and on genetic testing for the majority of primary HLH (2). HLH has to be rapidly diagnosed and prompt and aggressive treatment should be initiated, because of rapid progression to pancytopenia and multiorgan failure. The only curative treatment of primary HLH is allogeneic hematopoietic stem cell transplantation (HSCT) (3).

### Case report

A 13-month-old female patient was admitted in the emergency department because of persistent fever and mild anaemia. She was born from non-consanguineous parents and had no relevant personal or familial medical background.

Initially, she was treated for nasopharyngitis, then with amoxicillin/clavulanate for urinary tract infection, but fever did not resolve despite antibiotics. At

day 19 of persistent fever, physical examination showed skin pallor, a slight systolic murmur, and hepatosplenomegaly. A blood analysis was performed, revealing a normocytic regenerative anaemia (Hb 8.0 g/dL, reticulocytes 6%) without any signs of haemolysis. Indeed, levels of haptoglobin and bilirubin were normal, and reticulocytes were decreasing in the following blood tests. Currently, inflammatory markers were very low (CRP 8.8 mg/L (normal < 5 mg/L), ferritin 219 mcg/L (normal < 204 mcg/L)).

Ultrasound examination confirmed hepatosplenomegaly and showed lymphadenopathy in the hepatic hilum. At Day 21 of fever (38,4°C), she developed pancytopenia: anaemia (Hb 7.7 g/dL (normal: 10.5-12 g/dL)), neutropenia (990/mm<sup>3</sup> (normal: 1500-8500/mm<sup>3</sup>)), and thrombocytopenia (114 000/mm<sup>3</sup> (normal > 150 000/mm<sup>3</sup>)). Liver function test resulted in elevated alanine aminotransferase of 83 IU/L (normal < 34 IU/L) and aspartate aminotransferase of 89 IU/L (normal < 44 IU/L). Ferritin was slightly increased at 258 mcg/L. Acute leukemia was suspected. The patient was transferred to a tertiary centre for further examination. Bone marrow aspiration showed no signs of malignancy or hemophagocytosis. Bacterial and viral check-up were negative. At Day 22 of fever, she received a bolus of methylprednisolone (1 mg/kg) for transfusion reaction and fever transiently resolved but reappeared six days later.

**Table 1:** Diagnostic guidelines for HLH, based on HLH-2004 study; incomplete picture of the disease at admission of our patient; criteria fulfilled at diagnosis of our patient.

Diagnostic guidelines for HLH, established by HLH-2004	Criteria fulfilled at admission of our patient (3 out of 8)	Criteria fulfilled at diagnosis of our patient (6 out of 8)
Diagnostic of HLH if (1) or (2) is fulfilled:		
(1) <b>Molecular diagnosis of HLH</b>		
(2) <b>5 out of 8 of those following criteria</b>		
• Fever $\geq 38,5^{\circ}\text{C}$	+	+
• Splenomegaly	+	+
• Cytopenia ( $\geq 2$ of 3 lineages): Hb < 9.0 g/dL, platelets < $100 \times 10^9/\text{L}$ , neutrophils < $1.0 \times 10^9/\text{L}$	-	+
• Hypertriglyceridemia (fasting triglycerides $\geq 3.0$ mmol/L) and/or hypofibrinogenemia $\leq 1.5$ g/L	+	+
• Hemophagocytosis	-	-
• Low/absent NK-cell activity	Not tested	Not tested
• Hyperferritinemia $\geq 500$ mcg/L	-	+
• sCD25 $\geq 2,400$ U/ml (or according to the lab norms)	Not tested	+

At Day 35, biochemistry showed hyperferritinemia (1365 mcg/L). EBV and CMV serologies and PCR were negative. Flow-cytometry revealed a very elevated level of CD25s (18 295 pg/ml (normal < 1997 pg/ml)). Bone marrow aspiration performed again and still showed no signs of hemophagocytosis, but bone marrow biopsy revealed an increased number of macrophages. Analysis of cerebrospinal fluid (biochemistry, cytology) were negative. Magnetic resonance imaging of the brain showed a mild abnormal hypersignal in the periventricular white matter on T2 and FLAIR sequences. Diagnosis of HLH was made on all those criteria (Table 1).

Genetic tests showed compound heterozygous nonsense variants in the *UNC13D* gene: c.247C>T p.(Arg83\*) and c.640C>T p.(Arg214\*). These results confirm the diagnosis of familial hemophagocytic lymphohistiocytosis type 3, an autosomal recessive disease.

The patient was treated according to HLH-2004 protocol and received an HSCT, the only curative treatment (2, 3). Treatment was started before the result of genetic analysis was known.

## Discussion

HLH is a rare and life-threatening syndrome. It is characterized by an excessive activation of immune system, due to an uncontrolled proliferation of activated cytotoxic T lymphocytes and macrophages. There are two forms of HLH: primary HLH and secondary (or acquired) HLH. Primary HLH often occurs in infancy, in patients with a genetic disease in which HLH is the predominant manifestation. Secondary HLH can be diagnosed at any age, and may be triggered by malignancy, infection, immunosuppression, or auto-immune disorders (2, 4)

Physiopathology of HLH is resumed in Figure 1. A lack of normal cytotoxic function of cytotoxic T lymphocytes (CTL) and natural killer (NK) cells leads to a deregulated antigenic presentation, and then, to an excessive activation of CTL and NK cells. These hyperactivated cells cause an excessive secretion of cytokines. Hypercytokinemia, and particularly INF-g, leads to hyperactivation of macrophages, which themselves produce cytokines, amplifying the phenomenon. Hypercytokinemia stimulates secretion of cytokines by CTL, NK, and macrophages, causing a cytokine storm. Cytokine storm leads to vascular endothelium damage, myelosuppression, and finally fatal bleeding, severe infections, and multiorgan failure (5, 6).

Primary HLH encompasses a group of genetic diseases. This includes familial HLH (FHLH), but also several other genetic diseases in which HLH is a common manifestation. FHLH type 2 to 5 are autosomal recessive diseases, respectively caused by mutations in *PRF1*, *UNC13D*, *STX11* and *STXBP2* genes. The gene causing FHLH type 1 has not yet been identified. Those genes are

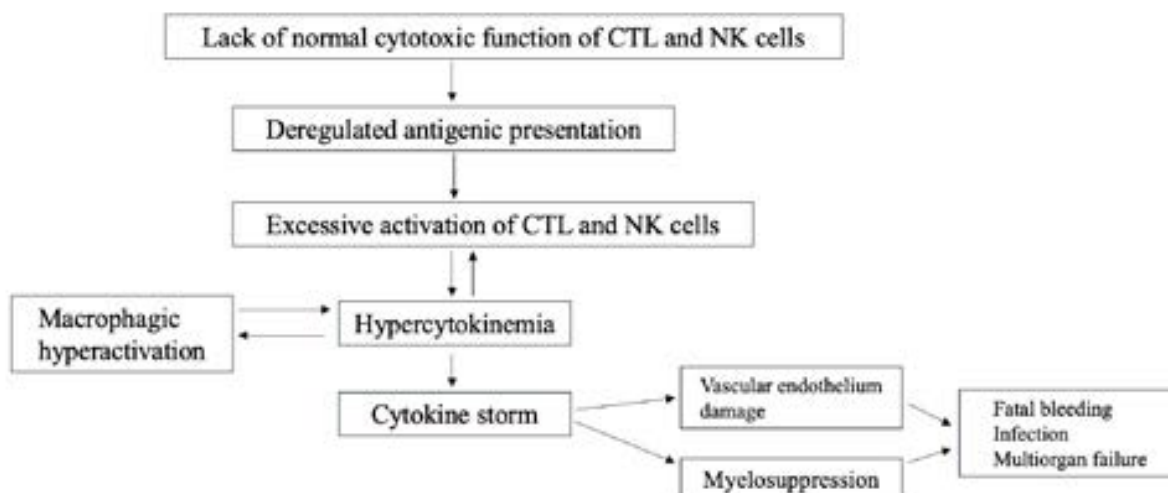
involved in the perforin-granzyme pathway. Perforin-granzyme pathway is one of the multiple pathways of NK/CTL-mediated cytotoxicity, inducing apoptosis. The first genetic defect was described in 1999 and involved the gene encoding perforin (7). In 2003, mutations in *UNC13D* gene, on chromosome 17q25, were discovered (8). *UNC13D* gene encodes a protein, Munc13-4, which is involved in the exocytosis of lytic granules, containing perforin and granzyme, in the immunological synapse (Figure 2). Mutations in *UNC13D* gene lead to FHLH type 3 (8). Other genetic diseases are associated with HLH, such as X-linked lymphoproliferative syndrome, Chédiak-Higashi syndrome, and Griscelli syndrome (2).

Analysis of *UNC13D* gene in our patient revealed a compound heterozygosity for c.247C>T p.(Arg83\*) and c.640C>T p.(Arg214\*) nonsense variants. Those variants were described in 2008 by Rudd & al (9). These patients were homozygous for one of those variants, while our patient was compound heterozygous for both. In our patient, we also detected another variant on *UNC13D* gene: c.2219C>T p.(Thr740Met) variant. This variant is classified as a variant of uncertain significance.

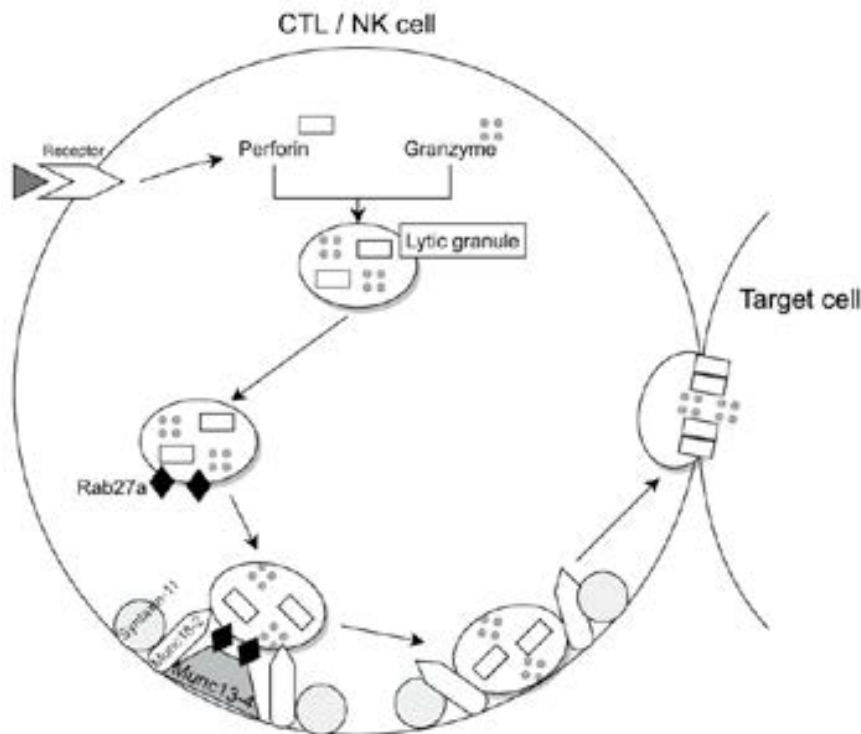
The diagnostic criteria, proposed by the Histiocyte Society in HLH-2004 study, are listed in Table 1. It is based on a molecular diagnosis consistent with HLH and/or unique combination of nonspecific clinical and biological features: fever, splenomegaly, cytopenia, hypertriglyceridemia and/or hypofibrinogenemia, hemophagocytosis, hyperferritinemia, high rate of soluble CD25, low or absent NK-cell activity (2). Patients may also develop central nervous system (CNS) involvement and liver dysfunction.

In this case, diagnosis was delayed due to several factors. First, fever was attributed to consecutive infections (pharyngitis, urinary tract infection). Secondly, the entire picture of the disease was incomplete when she arrived at the emergency department: initial blood analysis was not typical of HLH, with reticulocytosis and absence of inflammatory markers; and bone marrow was normal (Table 1). NK-cell activity was not assessed, although it is available in Belgium. Finally, CD25s is a nonspecific marker, and it is important to re-evaluate the patient multiple times, to re-consider the diagnosis each time and retest clinical examination and biological test in case of suspicion of HLH, even if the first dosages were normal. Once the diagnosis of HLH is made, in patients with severe systemic symptoms, treatment should be started as soon as possible, whether it is a secondary or primary HLH, except need to treat the cause for secondary HLH. For now, the only curative treatment for primary HLH is allogeneic HSCT. The initial therapy of the therapeutic regimen developed by the Histiocyte Society in HLH-2004 study is an immunochemotherapy (2). The aim of this immunochemotherapy is to suppress inflammation and to induce a transient control of the disease before HSCT. This therapy consists of dexamethasone, etoposide and cyclosporine A and, in patients with

**Figure 1 :** Physiopathology of HLH. Lack of normal cytotoxic function of CTL and NK cells leads to a deregulated antigenic presentation, and then, to an excessive activation of CTL and NK cells. These hyperactivated cells cause an hypercytokinemia, leading to hyperactivation of macrophages, which themselves produce cytokines, amplifying the phenomenon. Hypercytokinemia stimulates secretion of cytokines by CTL, NK, and macrophages, causing a cytokine storm. It leads to vascular endothelium damage, myelosuppression, and finally fatal bleeding, severe infections, and multiorgan failure.



**Figure 2 :** Perforin-granzyme pathway, one of the multiple pathways of NK/CTL mediated cytotoxicity. The activation signal leads to the formation of the lytic granule, containing perforin and granzyme. Rab27a, Syntaxin-11, Munc18-2 and Munc13-4 are involved in docking, priming and fusion of the lytic granule to the target cell. Polymerization of perforin induces formation of pores in the target cell, through which granzymes are released inducing cell apoptosis. Mutations in genes encoding perforin, Rab27a, Syntaxin-11, Munc18-2 or Munc13-4 are responsible for familial hemophagocytic lymphohistiocytosis. Mutations in UNC13D gene, encoding Munc13-4, leads to familial hemophagocytic lymphohistiocytosis type 3.



CNS involvement, intrathecal injection of methotrexate and hydrocortisone. This immunochemotherapy has a lot of adverse effects. Etoposide is myelo-suppressive and could induce secondary long-term cancers; cyclosporine A may induce hypertensive encephalopathy; and dexamethasone may lead to cardiac hypertension (10). In 2018, the Histiocyte Society published updated treatment recommendations, for the use of etoposide-based protocols and HSCT. Awaiting new alternative emerging drugs, the authors propose adapted doses of etoposide, based on patient's clinical and biological parameters (3).

Primary HLH is fatal if not treated. After diagnosis, median survival of untreated patients with active disease is about 2 months (2, 10). Mortality during treatment is high because of reactivation of disease or treatment-related morbidities. Patients can develop opportunistic infections, spontaneous bleeding, cardiac dysfunction, or multiorgan failure (10). In HLH-study, mortality before HSCT was 19%. 51% of patients underwent HSCT. The 5-year patient survival was 61% (11).

In the future, immunotherapy could have a place in the treatment of primary HLH. In the last years, several studies were conducted, with immunoactive agents as emapalumab, a human anti-interferon-gamma antibody, anti-JAK, alemtuzumab and ATG (1).

## Conclusions

HLH is a rare and underrecognized syndrome. It is important to know diagnostic criteria, because issue of this disease can be fatal if not treated. Several factors may lead to a delayed diagnosis, such as the lack of knowledge about this disease, an incomplete picture at the beginning, or the time to obtain some specific tests results. It is important to think about this diagnosis in patient with prolonged fever, pancytopenia and hepatosplenomegaly, and to continuously re-consider diagnosis even if criteria are uncompleted at the first evaluation. Once the diagnosis is made, treatment has to be rapidly started. For now, the only curative treatment for primary HLH is HSCT.

## Conflict of interest

The authors declare that there is no conflict of interest.

## REFERENCES:

1. S. W. Canina and R. A. Marsh, "Pediatric hemophagocytic lymphohistiocytosis," *Blood*, vol. 135, no. 16, pp. 1332-1343, Apr 2020.
2. J.-I. Henter, A. Horne, M. Arico, R. M. Egeler, A. H. Filipovich, S. Imashuku, S. Ladisch, K. McClain, D. Webb, J. Winiarski and G. Janka, "HLH-2004: Diagnostic and Therapeutic Guidelines for Hemophagocytic Lymphohistiocytosis," *Pediatr Blood Cancer*, vol. 48, no. 2, pp. 124-131, Feb 2007.
3. S. Elh, I. Astigarraga, T. von Bahr Greenwood, M. Hines, A. Horne, E. Ishii, G. Janka, M. Jordan, P. La Rosée, K. Lehmer, R. Machowicz, K. Nichols, E. Sieni, Z. Wang and J. Henter, "Recommendations for the Use of Etoposide-Based Therapy and Bone Marrow Transplantation for the Treatment of HLH: Consensus Statements by the HLH Steering Committee of the Histiocyte Society," *American Academy of Allergy, Asthma & Immunology*, vol. 6, no. 5, pp. 1508-1517, 2018.
4. E. Ishii, "Hemophagocytic Lymphohistiocytosis in Children: Pathogenesis and Treatment," *Front. Pediatr.*, vol. 4, p. 47, May 2016.
5. M. B. Jordan, C. E. Allen, J. Greenberg, M. Henry, M. L. Hermiston, A. Kumar, M. Hines, O. Eckstein, S. Ladisch, K. E. Nichols, C. Rodriguez-Galindo, B. Wistinghausen and K. L. McClain, "Challenges in the diagnosis of hemophagocytic lymphohistiocytosis: Recommendations from the North American Consortium for Histiocytosis (NACHO)," *Pediatr Blood Cancer*, vol. 66, no. 11, p. e27929, Nov 2019.
6. A. Morimoto, Y. Nakazawa and E. Ishii, "Hemophagocytic lymphohistiocytosis; Pathogenesis, diagnosis, and management," *Pediatrics International*, vol. 58, no. 9, pp. 817-825, Sep 2016.
7. S. E. Stepp, R. Dufourcq-Lagelouse, F. Le Deist, S. Bhawan, S. Certain, P. A. Mathew, J.-I. Henter, M. Bennett, A. Fischer, G. de Saint Basile and V. Kumar, "Perforin Gene Defects in Familial Hemophagocytic Lymphohistiocytosis," *Science*, vol. 286, no. 5446, pp. 1957-1959, Dec 1999.
8. J. Feldmann, I. Callebaut, G. Raposo, S. Certain, D. Bacq, C. Dumont, N. Lambert, M. Ouachée-Chardin, G. Chedeville, H. Tamary, V. Minard-Colin, E. Vilmer, S. Blanche, F. Le Deist, A. Fischer and G. de Saint Basile, "Munc13-4 Is Essential for Cytolytic Granules Fusion and is Mutated in a Form of Familial Hemophagocytic Lymphohistiocytosis (FHL3)," *Cell*, vol. 115, no. 4, pp. 461-473, Nov 2003.
9. E. Rudd, Y. T. Bryceson, C. Zheng, J. Edner, S. M. Wood, K. Ramme, S. Gavhed, A. G. G. Hellebostad, A. G. Bechensteen, H.-G. Ljunggren, B. Fadeel, M. Nordenskjöld and J.-I. Henter, "Spectrum, and clinical and functional implications of UNC13D mutations in familial hemophagocytic lymphohistiocytosis," *J Med Genet*, vol. 45, no. 3, pp. 134-141, Mar 2008.
10. M. B. Jordan, C. E. Allen, S. Weitzman, A. Filipovich and K. L. McClain, "How I treat hemophagocytic lymphohistiocytosis," *Blood*, vol. 118, no. 15, pp. 4041-52, Oct 2011.
11. E. Bergsten, A. Horne, M. Arico, I. Astigarraga, R. M. Egeler, A. H. Filipovich, E. Ishii, G. Janka, S. Ladisch, K. Lehmer, K. L. McClain, M. Minkov, S. Montgomery, V. Nanduri, D. Rosso and J.-I. Henter, "Confirmed efficacy of etoposide and dexamethasone in HLH treatment: long-term results of the cooperative HLH-2004 study," *Blood*, vol. 130, no. 25, pp. 2728-2738, Dec 2017.

## Case Report

# A case report of a rare cause of hypophosphatemic rickets-cystinosis

Maureen Vandebroucke<sup>a</sup>, Fanny Depasse<sup>b</sup>, Nadejda Ranguelov<sup>a,c</sup>, Eric Cavatorta<sup>d</sup>, Olivier Gilliaux<sup>a,e</sup>

<sup>a</sup>Pediatric department, CHU de Charleroi (Hôpital civil Marie Curie), Charleroi, Belgium

<sup>b</sup>Ophthalmology Department, HUDERF (Hôpital Universitaire Des Enfants Reine Fabiola), Brussels, Belgium

<sup>c</sup>Pediatric nephrology, Cliniques universitaires Saint Luc, Brussels, Belgium

<sup>d</sup>Head of Pediatric department, CHU de Charleroi (Hôpital civil Marie Curie), Charleroi, Belgium

<sup>e</sup>Laboratoire de médecine expérimentale (ULB222), Faculté de médecine, Université libre de Bruxelles, ISPPC CHU de Charleroi, Charleroi, Belgium

maureen.vandebroucke@huderf.be

## Keywords

children, hypophosphatemic rickets, cystinosis, failure to thrive, case report

## Abstract

**Background:** Bowed legs and failure to thrive in children must be thoroughly investigated.

Rickets results from deficient mineralization at the growth plate and can lead to bone deformation. The leading cause is vitamin D deficiency, but in rare cases, rickets can be caused by abnormalities of phospho-calcic metabolism, either primary (inherited) or secondary.

**Case:** A two-year-old boy presented with bowed legs and failure to thrive.

Investigations revealed hypophosphatemic rickets from renal Fanconi syndrome due to infantile cystinosis.

The patient was then treated with oral cysteamine and electrolytes, and the genu varum slowly improved.

**Conclusion:** Cystinosis is a rare disease with multiple presentations but should not be overlooked when diagnosing hypophosphatemic rickets.

## Introduction

Rickets is caused by deficient mineralization at the growth plate and ultimately can lead to bone deformation. It is mainly caused by vitamin D deficiency, but in rare cases, can also be caused by abnormalities of phospho-calcic metabolism, either primary (inherited) or secondary. This may be due to low calcium or phosphorus intake, poor mineral absorption, or excessive mineral excretion. Loss of phosphorus leads to hypophosphatemia, inhibiting caspase-9-mediated mitochondrial pathways and chondrocyte apoptosis and leading to growth-plate hypertrophy, osteoid accumulation, decreased strength, and stability bow-legs (1). Analysis of phosphocalcic blood balance and wrist and knee X-rays are recommended to confirm Rickets diagnosis.

In the case of elevated PTH (parathormone) with typical to low calcium

and phosphorus levels, 'the missing calcium' leads to 'calcipenic rickets,' in which vitamin D metabolism should be investigated. On average, with slightly elevated PTH with low phosphorus and normal calcium levels, lack of phosphorus leads to hypophosphatemic rickets (Table 1), and urine analysis should check phosphorus loss (2,3).

Fibroblast growth factor-23 (FGF-23), produced by osteocytes and osteoblasts, is the principal phosphate regulating hormone.

FGF-23 is elevated in a few HR phenotypes, decreasing phosphate reabsorption by downregulating sodium phosphate cotransporters in the proximal tubules, resulting in phosphaturia and hypophosphatemia (4).

**Table 1.** Hypophosphatemic rickets (HR): steps to diagnosis.

Serum PTH normal or low			
Low urine phosphorus	High urine phosphorus		
<ul style="list-style-type: none"> <li>· Insufficient phosphate intake</li> <li>· Decreased gastrointestinal absorption</li> <li>· Internal re-distribution</li> <li>· Dialysis</li> </ul>	Normal or low serum FGF-23		High serum FGF-23
	Excessive loss of amino acids, bicarbonate, and glucose in urine	Excessive loss of calcium in urine	<ul style="list-style-type: none"> <li>· Hereditary HR                             <ul style="list-style-type: none"> <li>- X-linked recessive HR (PHEX gene)</li> <li>- Autosomal dominant HR</li> <li>- Autosomal recessive HR</li> </ul> </li> <li>· Acquired HR</li> </ul>
	Fanconi Syndrome <ul style="list-style-type: none"> <li>· Acquired causes (drug, heavy metals)</li> <li>· Hereditary causes               <ul style="list-style-type: none"> <li>- Cystinosis (autosomal recessive)</li> <li>- Inborn errors of metabolism</li> <li>- Dent disease</li> <li>- ...</li> </ul> </li> </ul>	Hereditary HR with hypercalciuria (autosomal recessive)	

Hypophosphatemic rickets (HR) has many aetiologies: low phosphorus intake, urinary phosphate losses from proximal tubulopathy (renal Fanconi syndrome), or hypophosphatemia linked to fibroblast growth factor-23 (FGF-23).

Renal Fanconi syndrome can be inherited (cystinosis is the most common cause) or acquired (from drugs, heavy metals, chemotherapy) (Table 1).

Infantile cystinosis is a rare autosomal recessive condition caused by mutations in the *CTNS* gene, which causes a deficiency in cystinosis, a lysosomal proton-activated cystine transporter, with an incidence of 1 in 100,000 to 200,000. Cystine accumulates in lysosomes throughout the body, damaging cells and causing organ problems. Cystinosis is the most common hereditary cause of renal Fanconi syndrome, involving generalized proximal tubular dysfunction (5).

Rickets is caused by urine loss of phosphorus leading to hypophosphatemia. Clinical diagnosis of infantile cystinosis is based on symptoms such as vomiting and failure to thrive.

We report an unusual clinical presentation of Rickets in a two-year-old child.

## Case report

We report the case of a two-year-old boy with bowed legs and no medical history. He started irregularly walking at 13 months and had previously (during the first six months) received oral vitamin D supplementation.

Parents hadn't observed any signs of polydipsia or polyuria, though mild polydipsia was noticed after a thorough anamnesis.

### Clinical findings

The growth charts (Figure 1) showed failure to thrive (height: 73.5 cm (-4,8 SD); weight: 10 kg (-2,6 SD), BMI 18,5 kg/m<sup>2</sup> (1,9 SD)).

Overall, the physical exam was routine, except for bowed legs and red eyes (diffuse redness of the sclera).

### Diagnostic Assessment

An orthopedic surgeon was consulted initially for bowed legs. X-ray (Figure 2A) revealed severe bilateral genu varum suggesting rickets, and the patient was then referred to a rheumatologist.

Blood analysis (all values available in Table 2) revealed renal insufficiency (eGFR Schwartz equation, 60 ml/min/1.73 m<sup>2</sup>), hypophosphatemia, hyperchloremic acidosis, and low 25-hydroxyvitamin D. Thyroid hormones (TSH and T4 free), insulin-like growth factor-1, 1,25-hydroxyvitamin D and 1,84-parathyroid hormone were normal.

Normal PTH allowed us to exclude the hypothesis of calcipenic rickets. Alkaline phosphatases and C-terminal collagen crosslinks were elevated, suggesting an osteolytic process. Therefore, the patient was diagnosed with hypophosphatemic rickets. Proximal tubular acidosis related to renal Fanconi syndrome was diagnosed according to blood and urine results (all values available in Table 2), showing metabolic acidosis associated with urine losses: proteinuria (mixed proteinuria of nephrotic range), phosphaturia (according to TRP and TMP/GFR values), calciuria, natriuria, glycosuria, amino-aciduria and loss of bicarbonate. Alkaline urine in blood acidosis is suggestive of tubulopathy.

No history of medication or heavy metal exposure was reported. Renal ultrasonography showed accentuation of cortico-medullar differentiation and absence of established nephrocalcinosis; however spotty echogenic pyramids could have been caused by tubular deposits. Ophthalmologic examination revealed corneal cystine crystals, pathognomonic for cystinosis, thus establishing the diagnosis (Figure 2B).

The diagnosis was further confirmed by high levels of cystine found in WBCs three months after the first visit. Genetic analysis revealed two heterozygous mutations in the *CTNS* gene: a 65kb deletion and a nonsense mutation: c.978G>A – p.Trp326\*.


### Therapy

Treatment with 25-OH-vitamin D, alphacalcidol (0.04 µg/kg/day), and phosphorus with anhydrous phosphate solution (1 mmol/kg/day) were initiated.

Symptomatic treatment with sodium supplements, potassium bicarbonate, and carnitine was added later. Specific treatment with oral mercaptamine

**Figure 1 :** Growth charts.

Initiation of symptomatic followed by specific mercaptamine (cysteamine) treatment at 30 months of age. Persistence of short stature.



**Figure 2 :** Imaging results.

(A) X-ray of the front of right leg showing irregularities on femoral and tibial metaphyseal plates suggesting rickets. (B) Slit-lamp image revealing corneal cystine crystals pathognomonic for cystinosis.

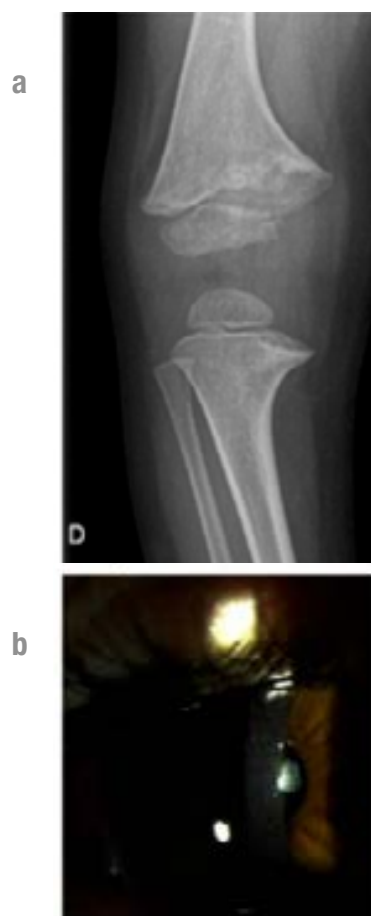

Table 2. Analyses

Analysis	Results	Norms	Units
<b>Biology (month 0)</b>			
Bicarbonate	16	(20 - 28)	mmol/L
Chlorine	110	(98 - 107)	mmol/L
Calcium	2.49	(2.20 - 2.70)	mmol/L
Phosphorus	1.04	(1.29 - 2.20)	mmol/L
Urea	24	(11 - 36)	mg/dl
Creatinine	0.54	(0.24 - 0.41)	mg/dl
Alkaline phosphatase	526	(156 - 369)	U/L
25-hydroxy vitamin D	20.3	(20 - 25)	ng/mg
1,25 (OH) <sub>2</sub> vitamin D	86	(25 - 86)	pg/ml
1,84-parathyroid hormone	24.1	(4.6 - 38.4)	ng/L
Carboxy-terminal collagen crosslinks	1140	(16 - 584)	pg/ml
<b>Urinalyses (month 0)</b>			
TRP	55	> 80	%
TMP/GFR	0.575	1.15 - 2.44	
Calcium U/ creatinine U	1.44	0.5 = P95	mg/mg of creatinine
Proteins/creatinine	3	< 0.2	g/g
<b>Biology (Month 3)</b>			
Bicarbonate	16	(20 - 28)	mmol/L
Anion gap	14	(8 - 16)	mmol/L
Carnitine	11.06	(23.9-51.9)	μmol/L
Intra-leucocyte cystine	7.17	< 0.4	nmol of 1-2 cystine per mg of protein
<b>Urinalysis (month 3)</b>			
pH	7.0		
Urinary anion gap	77.9		mmol/L
Glucose	5.2	< 0.15	g/L
Fractional excretion of sodium	1.5%		
Beta 2-microglobulin	120	< 0.2	mg/L
Microalbuminuria	886.2	< 30	mg/g of creatinine

(cysteamine), bitartrate, and mercaptamine chlorhydrate eye drops was started soon after diagnosis (at 30 months). Cysteamine at a starting dose of 10 mg/kg/day (0.2 g/m<sup>2</sup>/day) was increased over five weeks to 56 mg/kg/day (1.2 g/m<sup>2</sup>/day).

The patient then developed moderate polyuria, treated with indomethacin to minimize renal fluid and electrolyte losses.

### Outcomes

After nine months of treatment for phosphorus deficiency, leg straightening and improved walking was observed with the resumption of growth but the persistence of short stature (height: 85,5 cm (-3,1 SD) and stable weight charts (11 kg (-3 SD)) (BMI overall thus decreasing to 15 kg/m<sup>2</sup> (-0,6 SD)).

Renal insufficiency was improved: The Schwartz value increased to 75 ml/min/1.73m<sup>2</sup> corresponding to CKD2. Leucocyte cystine levels remained high, 2.95 and 6.5 nmol/1/2 cystine/mg protein, so cysteamine was increased to 73 mg/kg/day (1,6 g/m<sup>2</sup>/day). Mild photophobia appeared despite eye drops.

However, one year after establishing the diagnosis, compliance issues popped up.

To address these issues, a pediatric nephrology agreement provided free access to paramedical consultations (therapeutic education nurse, dietician, and psychologist). The social worker provides assistance to the family.

## Discussion

Infantile cystinosis (autosomal recessive disease) is caused by mutations in the *CTNS* gene (17p13.2), which codes for cystinosin, a lysosomal cystine-proton cotransporter. Cystinosin deficiency is associated with elevated cystine levels in lysosomes, defective endo-lysosomal trafficking, mitochondrial impairment, increase in ROS and apoptosis, and autophagy changes (6). Deficiency leads to the accumulation of cystine in all organs (6).

Fanconi syndrome is characterized by urine excretion of amino acids, glucose, bicarbonate, sodium, potassium, and phosphorus due to atrophy and death of cystinotic proximal tubular cells (6). Glomerular cells are progressively affected, inducing proteinuria. The end-stage renal disease occurs around ten years of age if untreated (6).

Extra-renal manifestations can also occur, causing ophthalmological, endocrine (thyroid), and neuromuscular issues (muscular weakness, swallowing issues...), etc. (7).

The accumulation of cystine crystals in the eyes can progressively lead to photophobia (related to the density of crystals, infiltration, inflammatory cells, and nerve damage within the cornea), blepharospasm, keratopathy, and corneal erosions (8).

Infantile cystinosis is a rare cause of hypophosphatemic rickets but the most frequent hereditary cause of renal Fanconi syndrome (5).

Renal Fanconi syndrome in infancy results in HR from hypophosphatemia, metabolic acidosis, 1,25-vitamin D deficiency, and hypocalcemia (9).

Patients with nephropathic cystinosis suffer from the cystinotic metabolic bone disease (CMBD), leading to HR and renal osteodystrophy. CMBD can cause osteomalacia, osteoporosis, bone deformation, short stature, and, more frequently, bone fractures. Uncorrected acidosis worsens bone damage and urinary calcium loss (9). Florenzano et al. discovered that rickets or osteomalacia from nephropathic cystinosis was responsible for 64% of the long bone deformities. The mean age of patients was 20 years old (5).

Contrary to this young patient, other reported cases of bone deformities occurred in older patients, with the initial presentation lacking bowed legs. (10, 11).

Early diagnosis of cystinosis relies on clinical information, urinalysis, and ocular slit-lamp examination. If the ophthalmologist confirms corneal crystals, a diagnosis of cystinosis should be made. Treatment should be started without molecular confirmation, considering corneal crystals could be absent in a very young patient.

After diagnosis, our patient received specific treatment with cysteamine. Oral cysteamine decreases glomerular renal function decline but has no direct effect on proximal tubulopathy or Fanconi syndrome (9). Phosphorus and bicarbonate supplementation minimize CMBD. Oral cysteamine delays renal failure and postpones metabolic bone disease due to CKD. Cysteamine eye drops are necessary because oral cysteamine does not reach the cornea, lacking a vascular system.

We observed a reduction in the redness of the sclera.

Treatment compliance was, however, poor, possibly because of polypharmacy.

The late diagnosis and concurrent late start of treatment partly explain our patient's chronic renal failure and bow legs. Electrolyte supplementation (phosphorus and bicarbonate) corrects the genu varum and prevents HR from getting worse.

When treatment is initiated before one year with correct compliance, end-stage renal disease in adulthood can be avoided. Therapeutic compliance remains difficult, however.

As shown in this case of a well-proportioned child, BMI is not enough. To monitor failure to thrive, every child should maintain growth charts.

Nutrition scores, such as the Waterlow score, were not used in this case, as small height related to cystinosis could have led to misinterpretation.

If failure to thrive and, in detail, short stature had been diagnosed and investigated earlier, Fanconi syndrome and cystinosis could have been diagnosed earlier, avoiding the appearance of rickets.

## Conclusions

We present a case of Rickets with an unusual appearance. Bowed legs, red eyes, and failure to thrive are all clinical signs that should be thoroughly investigated. Urinary dipstick, spot, and blood tests should rule out renal Fanconi syndrome. Cystinosis is one of the most common causes of hypophosphatemic rickets and the most common cause of inherited renal Fanconi syndrome. Early diagnosis, treatment, and care require multidisciplinary collaboration, partly because targeted early therapy improves prognosis.

## Conflict of interest

The authors have no conflict of interest to declare.

## REFERENCES:

1. Pai B, Shaw N. Understanding rickets. *Paediatr Child Health*. 2011;211:315-21.
2. Elder CJ, Bishop NJ. Rickets. *Lancet*. 2014;383(9929):1665-76.
3. Goretti M, Penido MG, Alon US. Hypophosphatemic rickets due to perturbations in renal tubular function. *Pediatr Nephrol*. 2014;29:361-73.
4. Baroncelli GI, Toschi B, Bertelloni S. Hypophosphatemic rickets. *Curr Opin Endocrinol Diabetes Obes*. 2012;19:460-67.
5. Florenzano P, Ferreira C, Nesterova G, Roberts MS, Tella SH, de Castro LF et al. Skeletal consequences of nephropathic cystinosis. *J of Bone Miner Research*. 2018;33:1870-80.
6. Cherqui S, Courtoy PJ. The renal Fanconi syndrome in cystinosis: pathogenic insights and therapeutic perspectives. *Nat Rev Nephrol*. 2017;13:115-31.
7. Veys KR, Elmonem MA, Arcolino FO, van den Heuvel L, Levtchenko E. Nephropathic cystinosis: an update. *Curr Opin Pediatr*. 2017;29:168-78.
8. Liang H, Baudouin C, Tahiri Joutei Hassani R, Brignole-Baudouin F, Labbe A. Photophobia and corneal crystal density in nephropathic cystinosis: an in vivo confocal microscopy and anterior-segment optical coherence tomography study. *Invest Ophthalmol Vis Sci*. 2015;56:3218–3225.
9. Hohenfellner K, Rauch F, Ariceta G, et al. Management of bone disease in cystinosis: Statement from an international conference. *J Inherit Metab Dis*. 2019;42:1019–1029.
10. Bacchetta J, Greco M, Bertholet-Thomas A, Nobili F, Zustin J, Cochat P et al. Skeletal implications and management of cystinosis: three case reports and literature review. *Bonekey Rep*. 2016;5:828
11. Klusmann M, Van't Hoff, Monsell F, Offiah AC. Progressive destructive bone changes in patients with cystinosis. *Skeletal Radiol*. 2014; 43:387-91.

## Case Report

# Pituitary stalk interruption syndrome. Case report and literature study

Astrid Jeunen<sup>a</sup>, Lieve Sevenants<sup>a</sup>, Thomas Deprest<sup>b</sup>, Kristina Casteels<sup>a-c</sup>

<sup>a</sup>Department of Pediatrics, University Hospitals Leuven, Leuven, Belgium

<sup>b</sup>Department of Radiology, University Hospitals Leuven, Leuven, Belgium

<sup>c</sup>Department of Development and Regeneration, KU Leuven, Leuven, Belgium

astrid.jeunen@hotmail.com

## Keywords

Pituitary stalk interruption syndrome, growth hormone deficiency

## Abstract

Growth hormone deficiency is common, with an incidence of 1-3/10.000 live births. In most children, no cause can be identified and it is called idiopathic. Pituitary stalk interruption syndrome is a congenital anomaly characterized by hypoplasia/aplasia of the anterior pituitary, pituitary-stalk dysgenesis, and/or an ectopic pituitary gland. Growth hormone deficiency is always present. Deficiencies of other anterior pituitary hormones may develop gradually and clinicians should be aware of associated problems to initiate appropriate follow-up and treatment. This paper addresses the importance of early diagnosis of pituitary stalk interruption syndrome by highlighting the symptoms and the need of follow-up. Early treatment of pituitary hormone deficiencies can prevent severe morbidity.

## Introduction

Short stature is defined as a height more than two standard deviations (SDS) below the mean for age. The initial evaluation of short stature should include a thorough history and physical examination. Accurate serial measurements, determination of growth velocity, midparental height, and bone age are important to study growth. Short stature can be familial or caused by constitutional delay of growth and puberty. Pathologic causes of short stature include chronic diseases, genetic diseases (e.g. Turner syndrome, Noonan syndrome, Silver-Russel syndrome...), or growth hormone deficiency. The term 'idiopathic short stature' was first used in the 1970s and describes non-syndromic short children with undefined etiology (1).

When diagnosing growth hormone deficiency (GHD), which can be congenital or acquired, further radiologic and endocrinologic assessment is necessary (2). Pituitary stalk interruption syndrome (PSIS) is a congenital disorder with a marked phenotypical heterogeneity. The hormonal profile, age, and associated abnormalities determine the patients' clinical picture (3).

PSIS belongs to the spectrum of midline malformations and is often associated with other midline extra-pituitary malformations. Other deficiencies may develop over time and result in panhypopituitarism (4-7).

In this paper, we present a patient with short stature, a stagnating growth curve, and episodes of asthenia, pallor, excessive sweating, somnolence, and abdominal pain. After confirmation of growth hormone deficiency, central imaging was performed and showed an interrupted pituitary stalk, hypoplastic anterior pituitary, and ectopic posterior pituitary. The diagnosis of PSIS was made.

## Case report

A 4.2-year-old boy was referred to the general pediatrics outpatient clinic for growth retardation and short stature. He was born at 37+4/7 weeks of gestation after an uncomplicated pregnancy and delivery.

Weight, length, and head circumference at birth were 2950 grams (standard deviation score (SDS) 0.8), 48 cm (SDS -1.1) and 35 cm (SDS 0.0). The neonatal period was uncomplicated except for a period of transient hypothermia (35.5°C). Episodes of pallor, excessive sweating, somnolence, and abdominal pain since the age of 2 were reported.

At the age of 4.2 years, his height was 92 cm (-3.2 SDS), far below the target height (0.5 SDS). His weight was 12.4 kg (-3.2 SDS) and head circumference

was 49.8 cm (-0.3SDS). The growth chart showed a growth retardation from the age of 10 months onwards (Fig. 1A). No dysmorphic features nor other abnormalities were noted at clinical examination.

Hormone blood levels showed the following results: undetectable IGF-1 (<35 µg/L), IFGBP-3 1046 g/L (normal value >1177 g/L), thyroid stimulating hormone (TSH) 1.83 mIU/L (0.27- 4.20 mIU/L), free T4 16.7 pmol/L (12.9-23.2 pmol/L), adrenocorticotrophic hormone (ACTH) 21.9 ng/L (10.0-60.0 ng/L), morning cortisol 9.3 µg/dL (6.2 – 18.0 µg/dL), LH 0.3 IU/L (1.7 – 8.6 IU/L), FSH 0.3 IU/L (1.2-7.7 IU/L), and prolactin 10.4 µg/L (2.0-18.0 µg/L). The X-ray showed a bone age (according to the Greulich and Pyle method) delayed by 1 year (bone age of 2.84 year for a chronologic age of 3.86 year) (Fig 1B).

A glucagon challenge test was performed. The peak serum GH concentration was 2.5 ng/mL at 90 minutes which was compatible with GHD (normal value >7.5-10 ng/mL) (6). The maximal cortisol response was 14.2 µg/dL. An episode of pallor, excessive sweating, somnolence, and abdominal pain was observed during the challenge test. A hypoglycemia of 39 mg/dL was measured at that moment, for which a bolus of glucose 5% was administered with subsequent normoglycemia.

Magnetic resonance imaging (MRI) revealed an interruption of the pituitary stalk, ectopic posterior pituitary, and hypoplastic anterior pituitary, prompting the diagnosis of PSIS (Fig 1C). Additionally, hypoplasia of the optic tract was diagnosed. An additional ophthalmological evaluation was performed but was normal apart from myopia for which glasses were prescribed. Genetic analysis was requested but is still ongoing.

Recombinant GH therapy was initiated with an obvious improvement in both height and weight. The episodes of asthenia, excessive sweating, and somnolence disappeared.

## Discussion

PSIS is a congenital pituitary abnormality with a heterogeneous clinical presentation. Due to the low number of reported cases, the exact incidence is difficult to determine. An estimated prevalence of 6.8% PSIS in the population with diagnosed GHD has been reported (n=1019/15043) (7). The etiology of PSIS has not yet been completely elucidated. Molecular defects in genes involved in pathways critical during early embryogenesis might play a role. Pathogenic mutations have been described in the POU1F1, PROP1, HESX1,

LHX3-4, SOX1-3, OTX2-3, POKR2, TGIF, GPR161, CDON, GLI1-2, OTUD4, and ROBO2 genes (1). Novel variants in candidate pathogenic genes of the hedgehog pathway (PTCH1, PTCH2...) have also been proposed (2). A polygenic and multifactorial etiology of PSIS has to be considered, because only 5% of cases can be explained by Mendelian heredity (3). Genetic analysis was requested in our patient but is still ongoing.

The clinical presentation of PSIS is variable and depends on the time of presentation, the hormone profile, and the associated abnormalities. A severe and permanent GHD is always present (3).

Hypoglycemia, prolonged hyperbilirubinemia, cryptorchidism, and/or a micropenis are frequent neonatal presentations of a pituitary disorder. Due to the regular isolated occurrence of these problems in otherwise healthy neonates, the correct diagnosis is often postponed. One clinical study described that in patients diagnosed with PSIS during adolescence, (missed) signs had already been present at neonatal age in 30% of cases (n=14/47) (4). Older patients are usually diagnosed within the context of growth retardation and short stature. Other possible causes of a growth retardation (e.g., disorders in another organ system, allergy, malabsorption, nourishment difficulties, abuse, ...) have to be taken into account in the differential diagnosis.

The GH axis is the first pituitary axis to fail. Afterwards, multiple hormonal defects (MHD) and even panhypopituitarism develop while the function of the posterior pituitary is usually preserved. A retrospective longitudinal study following disease progression in 67 patients with PSIS over a period of 20 years (1984-2014) confirmed the regression of residual pituitary function (4). This failure of the various axes does not occur in a set order but some deficiencies are more common: failure of thyroid hormones (70.3-79.8%) is the most prevalent, followed by failure of the gonadotropin hormones (65.1%-97.2%) and ACTH (65.1%-97.2%) (5,8-9). Both hyper- and hypoprolactinemia may occur. The majority of patients have normal levels of antidiuretic hormone. At the age of 4 years, our patient only had an isolated GHD. The diagnosis of growth hormone deficiency (GHD) is a challenge due to the lack of a true gold standard (10). Provocative GH tests continue to play a primary role in the diagnosis of GHD but are invasive, take 2–4 hours in duration, and have potential risks and side effects. A peak stimulated GH of less than 10 µg/L is the usual cut-off for GH deficiency in children in the United States, whereas European countries employ cut-offs as low as 6 µg/L. Two separate growth hormone provocation tests are often advised for a definitive diagnosis. In our patient, only one provocation test was performed as hypoglycemia occurred and an MRI had already confirmed the diagnosis.

MRI is essential for the definite diagnosis of PSIS, to visualize interruption or severe hypoplasia (<1 mm) of the pituitary stalk, hypoplasia/aplasia of the anterior pituitary, and/or an ectopic posterior pituitary. Isolated agenesis or ectopia of the posterior pituitary is not a pathognomonic sign of PSIS.

PSIS can be situated within the spectrum of midline defects, as the genes with pathogenic mutations are described as playing a role in the organogenesis of multiple midline structures. The initial presentation may therefore be based on associated congenital abnormalities such as an unusual facial phenotype (sparse hair, frontal bossing, hypertelorism, broad nasal root, prominent philtrum, cheilo-/palatoschisis, retrognathia, single median incisor) (Fig 2) and central nervous system defects (microcephaly, hydrocephalus, cerebellar atrophy, septo-optic dysplasia, corpus callosum agenesis, cerebellar vermis atrophy, Arnold-Chiari I malformation, aquaeductal stenosis, optic tract hypoplasia, coloboma of the retina). Other syndromes such as CHARGE syndrome and Fanconi anaemia are also associated with PSIS (11). (Table 1) It is unclear whether the presence of associated abnormalities increases the likelihood of developing MHD, (4,9). Clinical follow-up and measurement of hormone levels thus remain of utmost importance.

GHD is treated with daily subcutaneous injections of recombinant GH (0.025 - 0.032 mg/kg/day). The patient's height at the beginning of treatment and the growth rate in the first year after starting treatment are two favorable factors that determine the final height (6,11). Our patient showed an obvious improvement in both height and weight curves. There were no more episodes of asthenia, excessive sweating, and somnolence, which had probably been caused by hypoglycemia. It is known that hypoglycemia can occur in GHD due to increased insulin sensitivity and changes in gluconeogenesis.

**Table 1:** Clinical manifestations and hormonal status in patients with PSIS

Dysmorphic features	Sparse hair, broad forehead with frontal bossing, hypertelorism, broad nasal root, prominent philtrum, cheilo-/palatoschisis, microphthalmia, anophthalmia, single median incisor, bulbous nasal tip, thin upper lip, and retrognathia
Puberty and sexual development	Delayed or absent puberty, micropenis
Hormonal status	GH deficiency, TSH deficiency, LH/FSH deficiency, ACTH deficiency, ADH deficiency, hypoprolactinemia and hyperprolactinaemia.
Central malformations	Microcephaly, hydrocephalus, cerebellar atrophy, cerebellar dysgenesis, septo-optic dysplasia, corpus callosum agenesis, abnormality of septum pellucidum vermis atrophy, Arnold-Chiari I malformation, septal agenesis, aqueductal stenosis and optic tract hypoplasia, coloboma of the retina, craniopharyngeal canal, holoprosencephaly, bilateral perisylvian polymicrogyria
Other	Cryptorchidism, neonatal hypoglycemia and hyperbilirubinemia, Pallister-Hall syndrome, Stilling Duane syndrome, CHARGE syndrome, Rieger syndrome, Fanconi anemia, epilepsy, intellectual disability, strabismus

If ACTH or TSH deficiency is confirmed, administration of hydrocortisone (8-15 mg/m<sup>2</sup>/day) or L-thyroxine (1.5-2.0 µg/kg/day) is required. Glucocorticoids must be substituted first before starting L-thyroxine, because an euthyroid status may destabilize a patient with ACTH deficiency. For dose adjustment, blood tests to determine end-organ and pituitary hormones are carried out at regular intervals, taking diurnal variation into account.

## Conclusion

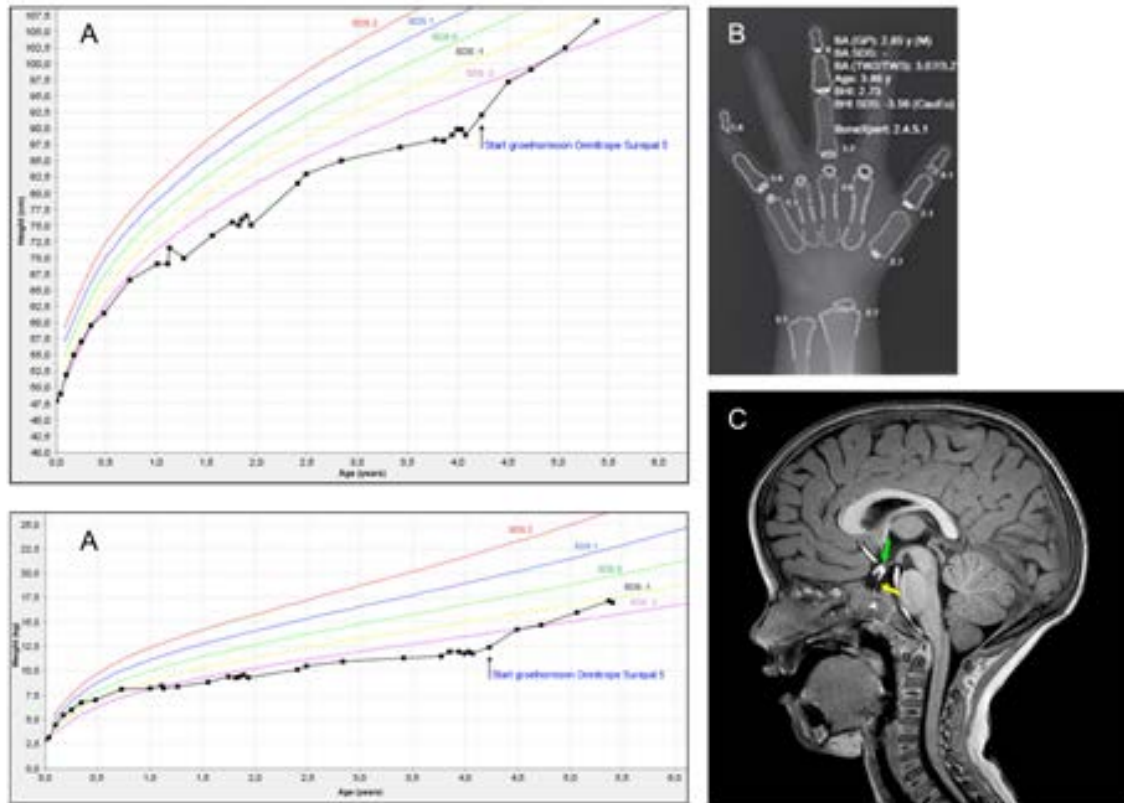
PSIS is a congenital disorder with marked phenotypical heterogeneity. The hormone profile, age, and associated abnormalities determine the clinical picture but the majority of children presents with short stature. Children with GHD are recommended to undergo a thorough neuroradiographic and endocrine evaluation. Characteristic radiological features of PSIS are an interrupted pituitary stalk and a hypoplastic or aplastic anterior pituitary. The posterior pituitary may be absent or ectopic. Several pathogenic and candidate genes have been proposed but polygenic and environmental factors are both likely to play a role in the pathogenesis.

In addition to GHD, other hormone deficiencies may also occur (TSH deficiency, ACTH deficiency, gonadotropin deficiency etc.) in various degrees of severity, but since pituitary function tends to deteriorate in PSIS, rigid follow-up is necessary.

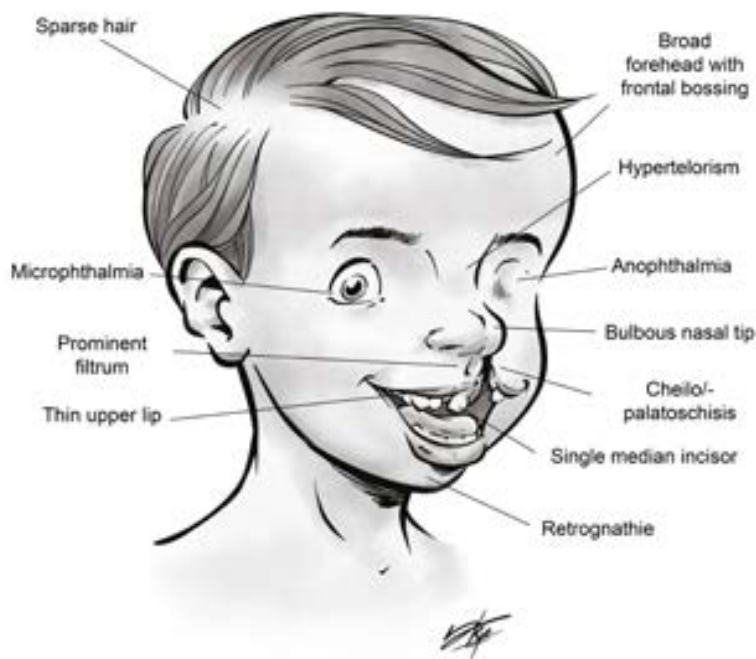
## Conflict of interest

The authors of this article declare that they have no conflict of interest. They do not have any affiliation with or involvement in any organization or entity with a financial or non-financial interest in the subject matter or the materials discussed in this case report.

**Figure 1 :** Figure 1A. Height and weight curves of the patient. Downward sloping starts from age of 10 months onwards, and height is far below the target height (183.5 cm). Recovery of the downwards slope after administering replacement growth hormone at the age of 4 years and 3 months. B. X-ray of the left hand: delayed bone age of 1 year (according to the Greulich and Pyle method). C. MRI of the pituitary: T1 weighted image with confirmation of PSIS. The yellow arrow indicates an interrupted pituitary stalk, the white arrow the hypoplastic anterior pituitary, and the green arrow the ectopic posterior pituitary.



**Figure 2 :** Dysmorphic facial features matching PSIS



REFERENCES:

- Rapaport R, Wit JM, Savage MO. Growth failure: 'idiopathic' only after a detailed diagnostic evaluation. *Endocr Connect.* 2021;10(3):125-138.
- Fang X, Zhang Y, Cai J, Lu T, Hu J, Yuan F, et al. Identification of novel candidate pathogenic genes in pituitary stalk interruption syndrome by whole-exome sequencing. *J Cell Mol Med* 2020;24(20):11703-11717.
- Brauner R, Bignon-Topalovic J, Bashamboo A, McElreavey K. Pituitary stalk interruption syndrome is characterized by genetic heterogeneity. *PLoS One* 2020;15(12):e0242358.
- Bar C, Zadro C, Edouard T, Diene G, Oliver I, Pienkowski C, et al. Pituitary stalk syndrome from infancy to adulthood: clinical, hormonal and radiological assessment according to initial presentation. *PLoS One* 2015;10(11):e0142354
- Wang W, Wang S, Jiang Y, Yan F, Su T, Zhou W, et al. Relationship between pituitary stalk (PS) visibility and the severity of hormone deficiencies: PS interruption syndrome revisited. *Clin Endocrinol (oxf)* 2015;83(3):369-76.
- Yakovovitch M, Lazar L, Diamant R, Philip M, Oron T. Diagnosis of Growth Hormone Deficiency in Children: The Efficacy of Glucagon versus Clonidine Stimulation Test. *Horm Res Paediatr* 2020;93(7-8):470-6.
- Maghnie M, Lindberg A, Koltowska-Hägström M, Ranke M. Magnetic resonance imaging of CNS in 15043 children with GH deficiency in KIGS (Pfizer International Growth Database). *Eur J Endocrinol* 2013;168(2):211-7.
- Zhang Q, Zhang L, Li YJ, Han BY, Gu WJ, Yan WH, et al. Thyrotrophic status in patients with pituitary stalk interruption syndrome. *Medicine (Baltimore)* 2018;97(2):e9084.
- Reynaud R, Albarel F, Saveanu A, Kaffel N, Castinetti F, Lecomte P, et al. Pituitary stalk interruption syndrome in 83 patients: novel HESX1 mutation and severe hormonal prognosis in malformative forms. *Eur J Endocrinol* 2011;164(4):457-465.
- Stanley T. Diagnosis of growth hormone deficiency in childhood. *Curr Opin Endocrinol Diabetes Obes.* 2012;19(1):47-52.
- Vergier J, Castinetti F, Saveanu A, Girard N, Brue T, Reynaud R. Pituitary stalk interruption syndrome: etiology and clinical manifestations. *Eur J Endocrinol* 2019;181(5):199-209.

## Case Report

# Painful proptosis and compressive optic neuropathy in an 11-year-old girl with tuberculosis

Laurent Saikali<sup>a</sup>, Heidi Segers<sup>b</sup>, François Vermeulen<sup>c</sup>, Philippe Demaerel<sup>d</sup>, Ingele Casteels<sup>e</sup>

<sup>a</sup>Ophthalmology, Torbay and South Devon NHS Foundation Trust (UK) and KU Leuven

<sup>b</sup>Pediatric hemato-oncology, UZ Leuven

<sup>c</sup>Pediatric pneumology, UZ Leuven

<sup>d</sup>Radiology, UZ Leuven

<sup>e</sup>Ophthalmology, UZ Leuven

laurent.saikali1@gmail.com

### Keywords

Proptosis, tuberculosis, compressive optic neuropathy (CON), case report

### Abstract

An 11-year-old girl presented with sudden onset of unilateral proptosis and periocular pain. Initial examination revealed proptosis, restricted vertical ocular motility with vertical binocular diplopia, decreased visual acuity and visual field impairment in the left eye. Systemic work-up revealed extrapulmonary tuberculosis with an inflammatory lesion at the left orbital apex causing a compressive optic neuropathy (CON). Three months after treatment with anti-tuberculosis (TB) therapy the proptosis regressed, the ocular motility normalized, and the central visual acuity recovered. The optic atrophy persisted with partial loss of the visual field. This is a very rare presentation of tuberculosis in an 11-year-old child.

### Case Report

We report the case of an 11-year-old girl presenting at the University Hospitals Leuven with one week history of pain in the left eye and a progressively increasing left proptosis in the last month (fig. 1). There were no other general symptoms (no fever, weight loss or nocturnal sweating). The patient had immigrated from Somalia 3 years before.

At a first examination, elevation and depression of the left eye were restricted which induced binocular vertical diplopia. Central visual acuity was normal but visual field defects with globally reduced sensitivity were seen. Minimally impaired colour vision, a left relative afferent pupillary defect (RAPD), associated with moderate optic disc pallor, were suggestive for an optic neuropathy. Somatic examination showed no signs of meningism, no fever, no skin lesions. Pulmonary, abdominal and cardiac auscultations were normal and there were no abnormal systemic neurological findings. The only non-ocular pathological clinical finding was the presence of a palpable right abdominal soft tissue mass.

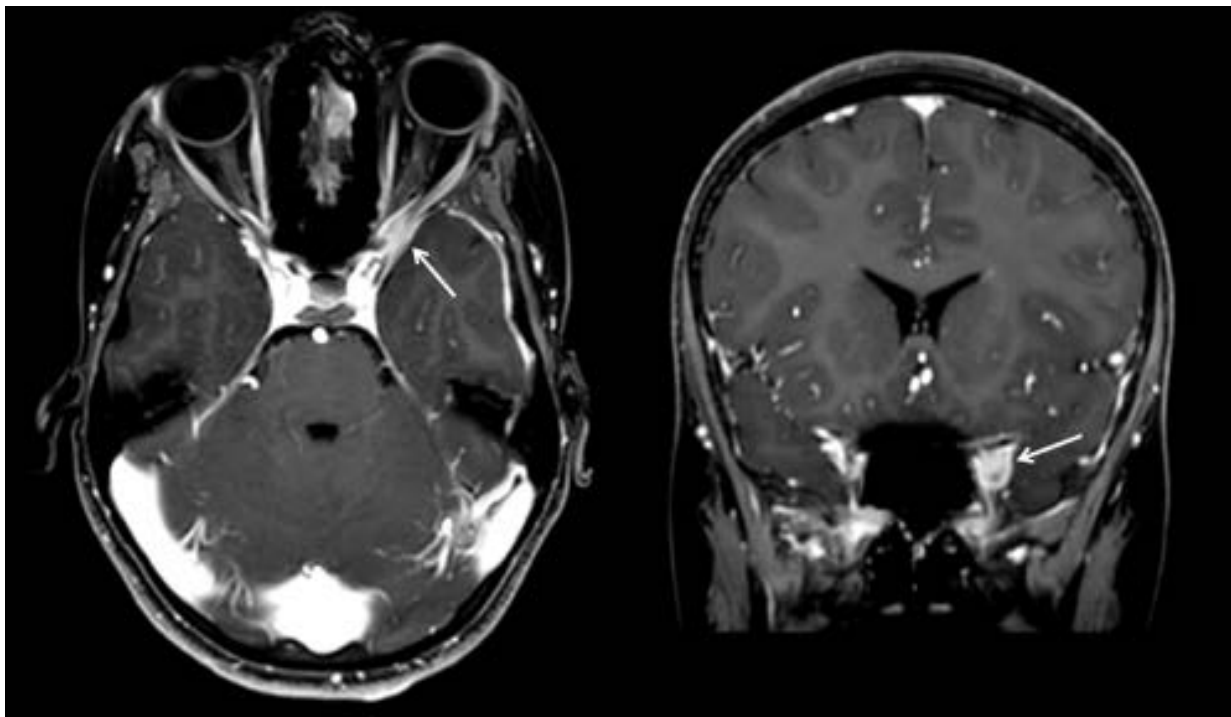
The cranial MRI showed an unsharply delineated intra-orbital lesion with a diameter of +/- 1 cm at the apex of the left orbit (fig. 2), causing a mass-effect and inducing proptosis and a compressive optic neuropathy (CON) without infiltration into the optic nerve, as well as two nodular lesions at the left lamina cribrosa with expansion into the ethmoid sinus. Whole body positron emission tomography and computed tomography (PET-CT) showed a pulmonary lesion in the left apex, two nodular lesions in the right kidney, a distal cortical left femoral lesion, mediastinal and abdominal lymphadenopathies were also visualized.

Purified protein derivative (PPD) skin test and interferon gamma release assay (IGRA) were both positive. A first biopsy of a mediastinal lymph node by mediastinoscopy was not conclusive but showed no arguments for a lymphoma (which was the first diagnosis to exclude in the differential). The bone marrow biopsy was normal. Before considering more invasive surgical biopsy of the abdominal lymph nodes, a transtracheal echo-guided subcarinal lymph node biopsy was performed. Polymerase chain reaction (PCR) and culture of

Figure 1 : Left proptosis



Figure 2 : T1-weighted images with contrast (Gadolinium), note the contrast enhancing lesion at the left orbital apex (arrow)



these samples were positive for *Mycobacterium tuberculosis*, sensitive to all first-line anti-tuberculosis drugs. Lumbar puncture was negative. There was no known family history of tuberculosis but the patient and her family were referred to the Flemish Association for Respiratory Medicine and Tuberculosis Management (VRGT) for contact tracing.

Treatment for extrapulmonary tuberculosis was prescribed, with rifampicin – isoniazid – ethambutol – pyrazinamide for 2 months, followed by bi-therapy (rifampicin - isoniazid) for 7 months. Three months after the start of the tuberculostatic therapy there was a clear clinical and radiologic regression of the orbital and extra-orbital lesions. The proptosis relative to the right eye decreased from 3 to 1 mm with improvement in ocular motility and resolution of the vertical diplopia. Visual acuity fluctuated during the first month but was ultimately preserved. The visual field improved slightly (possibly due to a learning artefact) but did not fully recover and the left relative afferent pupillary defect persisted, as expected due to the optic nerve atrophy (fig. 3).

## Discussion

The most frequent etiology of unilateral proptosis is thyroid eye disease (TED) in the adult, and infectious cellulitis in children (1). Any pathologic change in the orbit needs to be investigated swiftly and thoroughly as due to the proximity of the globe and the optic nerve, significant damage and visual loss can occur even with “benign” orbital diseases (1). Especially when a child presents with a sudden onset of proptosis urgent work-up is indicated as this sign is mostly associated with severe pathological changes and urgent therapy is often required. Rhabdomyosarcoma is the most common primary orbital malignant tumor in children and will present with a rapidly increasing proptosis (1-4). Other malignant and benign causes of paediatric proptosis, in decreasing frequency, are optic nerve gliomas, metastases of neuroblastoma, orbital neurofibromas, vascular malformations such as capillary hemangiomas, metastatic Ewing’s sarcomas, dermoid cysts, chloromas of acute myeloid leukemia, Burkitt lymphomas, Langerhans cell histiocytosis, retinoblastomas (only very severe cases expanding through the sclera beyond the eyeball) and arteriovenous/lymphatic malformations (2,3,8). Proptosis with spontaneous periorbital ecchymosis (raccoon eyes)

is especially suspect for malignancies (2). Inflammatory diseases such as thyroid eye disease can also cause proptosis in children (2-4).

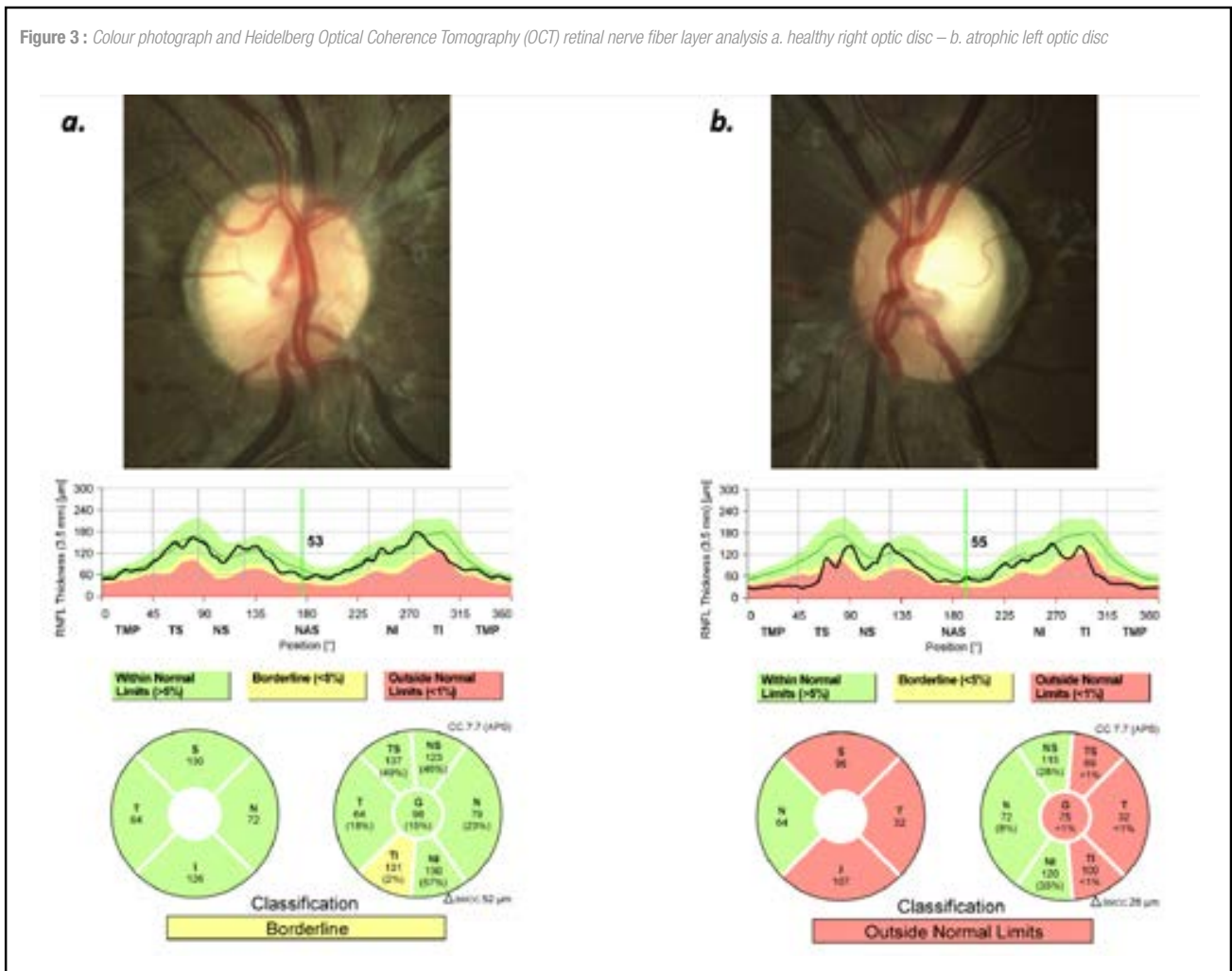
The presence of extra-orbital multiple disseminated lesions throughout the body associated with the country of origin of our patient guided us towards a possible diagnosis of tuberculosis, which was later confirmed.

The incidence of tuberculosis in Belgium is decreasing since the 1990’s but the decrease has slowed down more than in our neighboring countries over the last 25 years. In 2019 the general yearly incidence was 8,5/100.000 inhabitants (4,3/100.000 in Belgian citizens versus 38,9/100.000 for the non-Belgian population). For children between 0 and 14 years of age the incidence is 1,3/100.000 in Belgian compared to 10/100.000 in non-Belgian children (5). These discrepant numbers show the impact of immigration on the risk of developing tuberculosis.

When treating patients with tuberculosis it is important to keep in mind that toxic optic neuropathy can be caused by ethambutol or isoniazid toxicity. The most common ophthalmic manifestations of these toxic optic neuropathies are dyschromatopsia and scotomas (6). When symptoms occur, exposure to these drugs needs to be interrupted as soon as possible because damage to the optic nerve can be permanent. In our case no drug toxicity occurred.

Intra-orbital tuberculous lesions, although very rare in Europe, have been described before. Oakhill et al. published a case report in 1982 about orbital tuberculosis in an 11-year-old girl in the UK. She made a complete recovery when treated with anti-TB medication (7). She presented with proptosis but there is no description of visual loss or optic neuropathy. A few other cases were reported in Egypt and India. Hughes et al. published a case series of 7 adults (aged 24-44) who presented with orbital apex syndrome or optic neuropathy attributed to tuberculosis in the UK. Only 2 cases presented with proptosis and 1 with diplopia. All patients showed good visual recovery after treatment with high dose corticosteroids and anti-TB medication (8). Tenawade et al. described an orbital apex syndrome caused by tuberculosis in a 16-year-old adolescent girl in the UK. There was no proptosis but restricted motility and partial ptosis of the upper lid. MRI findings showed an infiltrative lesion around the optic nerve with crowding

Figure 3 : Colour photograph and Heidelberg Optical Coherence Tomography (OCT) retinal nerve fiber layer analysis a. healthy right optic disc – b. atrophic left optic disc



at the apex leading to a compressive optic neuropathy. The logMAR visual acuity dropped from 1.5 at presentation to perception of light 9 days later. The visual acuity did not recover and marked optic atrophy was noted 6 months after presentation (9).-

Although the central visual acuity was preserved in our patient, the optic nerve became atrophic due to longstanding compression with a permanent lasting relative afferent pupillary defect and visual field defects. Thanks to prompt diagnosis and treatment further damage could be prevented. No corticosteroids were started in our case as the visual acuity was conserved at the time of the exact diagnosis. Steroids could have masked a lymphoma if started immediately.

To the best of our knowledge, the combination of both proptosis and compressive optic neuropathy due to tuberculosis has not yet been described in a child.

The aim of this article is to report this unusual paediatric presentation of tuberculosis and to emphasize the importance of swift work-up in proptosis to prevent possible permanent visual loss.

#### Informed consent

Informed consent for publication of this case was given by the patient and her guardian.

#### Disclosure

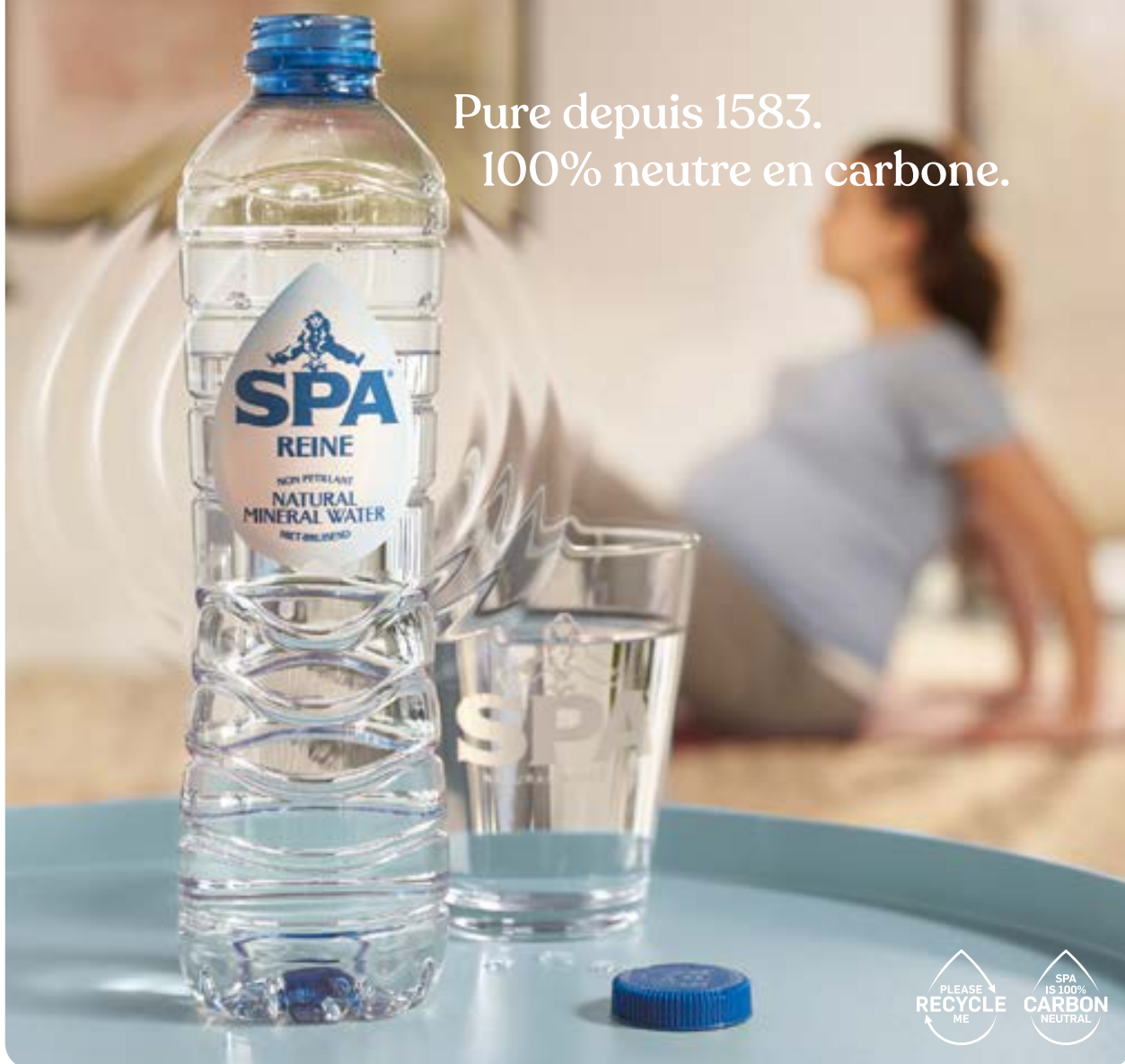None of the authors has a conflict of interest to disclose.

#### REFERENCES:

1. Topilow NJ, Tran AQ, Koo EB, Alabiad CR. Etiologies of Proptosis: A review. Intern Med Rev (Wash D C). 2020;6(3):10.
2. Neil J. Friedman, Peter K. Kaiser, William B. Trattler. Review of Ophthalmology. 3rd Edition. Philadelphia: Elsevier; 2018.
3. Sindhu K, Downie J, Ghabrial R, Martin F. Aetiology of childhood proptosis. J Paediatr Child Health. 1998;34(4):374-6.
4. Altonbary Y, Mansour AK, Sarhan M, Alwakeel AA, Abdelmabood S, Elmahdi HS et al. Proptosis is a Pediatric Dilemma. Ann Pediatr Child Health 2015;3(4):1066.
5. Arrazola de Oñate W, De Smet P, Janssens K. Tuberculoseregister België 2019. Leuven: Vlaamse Vereniging voor Respiratoire Gezondheidszorg en Tuberculosebestrijding VRGT vzw; 2019 [cited 2021 Dec 20]. 58 p. Available from: <https://tuberculose.vrgt.be/facts-figures-tuberculose>.
6. Grzybowski A, Zülsgdorff M, Wilhelm H, Tonagel F. Toxic optic neuropathies: an updated review. Acta Ophthalmol. 2015;93(5):402-10.
7. Oakhill A, Shah KJ, Thompson AG, Stokes MJ, Mann JR. Orbital tuberculosis in childhood. Br J Ophthalmol. 1982;66(6):396-97.
8. Hughes EH, Petrushkin H, Sibtain NA, Stanford MR, Plant GT, Graham EM. Tuberculous orbital apex syndromes. Br J Ophthalmol. 2008;92(11):1511-7.
9. Tanawade RG, Thampy RS, Wilson S, Lloyd IC, Ashworth J. Tuberculous Orbital Apex Syndrome with Severe Irreversible Visual Loss. Orbit. 2015;34(3):172-4.

# Restez pur.

Pure depuis 1583.  
100% neutre en carbone.



## Mieux boire. Mieux vivre.

**SPA® REINE** est une eau minérale naturelle **extrêmement pure**, qui peut être bue par tout le monde, à tout moment de la journée, sans la moindre restriction. Le secret de cette pureté légendaire? Une **protection draconienne de l'environnement** et un très long voyage

accompli dans le sous-sol des Fagnes. Grâce à cette purification souterraine, SPA® REINE bénéficie d'**une composition unique**: elle est très pauvre en sels minéraux (38 mg/l) et **convient idéalement pour la préparation des repas des nourrissons.**

# Mustela®



Voor de  
**hele familie**



## De juiste zonnebescherming

Hoge tolerantie voor baby's en kinderen, geschikt vanaf de geboorte\*  
en voor zwangere vrouwen in geval van onvermijdelijke blootstelling

\*Baby's die de neonatologie hebben verlaten - Respect oceaan: filters overeenkomstig de Hawaïaanse regelgeving, zonder oxybenzone en octinoxaat. Bio geÛpcyclede avocado's afkomstig van duurzame landbouw en verantwoorde bevoorradingsketen

# Long-term outcomes of hypospadias: Urological and psychosexual function and endocrine-reproductive capacity

PhD thesis presented on 09/03/2022 at Ghent University, Ghent, Belgium.

Lloyd J.W. Tack<sup>a</sup>

**Promotors:** Martine Cools<sup>a</sup>, Anne-Françoise Spinoit<sup>b</sup>, Hannah Verdin<sup>c</sup>

<sup>a</sup> Division of Paediatric Endocrinology, Department of Internal Medicine and Paediatrics, Ghent University Hospital, Ghent University, Ghent, Belgium.

<sup>b</sup> Division of Paediatric Urology, Department of Urology, Ghent University Hospital, Ghent University, Ghent, Belgium.

<sup>c</sup> Center for Medical Genetics, Ghent University Hospital, Ghent, Belgium.

lloyd.tack@uzgent.be

## Keywords

Hypospadias, long-term outcome, Testicular Dysgenesis Syndrome, Penile function, Testicular function

## Background

Male genital development is a complex process requiring the intricate and delicate interaction of genetic, hormonal and mechanical factors. It is therefore unsurprising that male genital development frequently hampers, commonly presenting with some form of hypospadias. Although roughly 1/200 newborn males is born with hypospadias, very little is known regarding their long-term outcomes (1). This gap in knowledge renders surgical, endocrine, fertility and genetic counseling of patients and parents difficult. Performing long-term outcome studies is therefore imperative to be able to provide tailored follow-up and guidance to men born with hypospadias and their parents.

## Methodology

The main aim of this PhD thesis was to explore the outcome of children and young men born with various forms of non-syndromic hypospadias and elucidate the genetic factors underlying the development of hypospadias. A first, cross-sectional study was performed exploring the psychosexual, urological, endocrine outcome and seminal parameters of adolescent and young adult men (AYA) born with non-syndromic hypospadias compared to healthy, male peers. In total, 193 hypospadias cases and 50 typical males, all aged 16-21 years, were recruited in Ghent university hospital and medical university Vienna. DNA samples were obtained for in depth genetic tests in cases with familial or severe hypospadias or those with a suboptimal endocrine or reproductive outcome (n=99). These data were supplemented by a second, retrospective study focusing on the endocrine outcome of children and adolescents with severe forms of hypospadias, differentiating between boys born small for gestational age (SGA; n=115) and boys born appropriate for gestational age (AGA; n=64). Data were obtained from twelve DSD-reference centers from across the world through the I-DSD consortium ([www.i-dsd.org](http://www.i-dsd.org)). Lastly, a prospective collection of foreskin samples obtained through routine hypospadias repair (n=197) and circumcision (n=198) was used to compare androgen receptor expression in Dartos tissue.

## Results

The overall psychosexual outcome of AYA who underwent childhood hypospadias repair was suboptimal, but overall not different from male peers (2). Several risk factors were associated with impaired psychosexual outcomes, such as the severity of hypospadias, need for multiple penile surgeries and dissatisfaction regarding genital appearance. Nonetheless, the vast majority of patients were happy they had underwent the hypospadias repair during their childhood and experienced a positive attitude towards the current practice of childhood surgery. Regardless of the sometimes

suboptimal esthetic outcome, as assessed by a physician, only two men (1%) had received negative comments from their sexual partners. Of note, in both cases the comments were restricted to penile size and were not based on the overall esthetics of the genital appearance (e.g. scar tissue, curvature, penile axis). Patients rated the esthetic outcome of their genitals overall better than the physician and were often not bothered by esthetic and functional imperfections. Mild erectile dysfunction and a wide range of ejaculatory problems were reported in 11.2% and 12% of AYA, respectively. Both the erectile dysfunction and ejaculatory problems were unrelated to patient or surgical factors and thus likely caused by underlying psychosexual factors. Based on these data, we would recommend a restrictive attitude towards re-interventions for non-functional problems. Furthermore, psychosexual counseling could also benefit the well-being of men born with hypospadias, especially in those with severe forms or when repeated penile surgeries are needed. Although the majority of patients and parents had remained positive towards the childhood hypospadias repair, many parents indicated that they had experienced the entire diagnostic and therapeutic process as very stressful. Early psychological support may thus be helpful for some parents of boys born with hypospadias.

Regarding the surgical and urological outcome, we discovered a surgical re-intervention rate of 39.2% of those who had their first hypospadias repair in Ghent university hospital or medical university Vienna, thus excluding those who were referred for failed surgery from a different center (3). Suboptimal urinary and/or sexual outcomes were found in 52.9% of cases, with 24.9% of the AYA having residual hypospadias and 5.7% having a fistula at the time of the study. Of note, these boys were not actively seeking medical counseling for these problems. Taking into account that these complications sometimes arose many years after the first hypospadias repair, we recommend the organization of urological follow-up for decades after the initial surgery. Furthermore, our data support the organization of a specialized urology team for hypospadias repair and deferral of hypospadias repair until the age of at least 12 months, as this could reduce the complication rate. Smaller adult stretched penile lengths and more severe hypospadias were also associated with worse outcomes and warrant a cautious surgical approach.

In 2001, Skakkebaek et al. (4) postulated that hypospadias, cryptorchidism, male infertility and testicular cancer are part of a spectrum with a common etiology. This testicular dysgenesis syndrome hypothesis has since then been supported by several studies. However, very little is known about the position of hypospadias within this spectrum. In our studies, we discovered subclinical Leydig cell dysfunction in childhood and young adulthood, with very few boys having encountered problems regarding their pubertal devel-

opment (5). Similarly, clinically relevant hypogonadism was not found in any of the cases of our cross-sectional study, even in those with profound undervirilisation (Tack LJW, EBioMedicine, in press). However, spermatogenesis was a major concern. Low sperm concentrations were common in men born with severe and complex forms of hypospadias and men born small for gestational age. Remarkably, in men born SGA with hypospadias, the severity of hypospadias and overall severity of undervirilisation were unrelated to the risk of having reduced sperm concentrations. This group of men was also found to have poor growth, with approximately 30% having insufficient catch-up growth and 35% not reaching their target height based on mid-parental height. In the overall SGA population, poor catch-up growth and short stature are expected in 10% of cases (6). Therefore, referral to the pediatric endocrinologist is warranted in all SGA children born with hypospadias for follow-up of growth and if needed, initiating growth hormone treatment. Given that sub- and infertility were common in our cohort, we recommend discussing potential fertility issues during follow-up once the patient is deemed mature enough. If the patient is willing, he should be offered fertility assessment through semen analysis. Hormone assays using FSH or inhibin B were found unreliable markers to screen for potential sub- or infertility as the majority of men with low sperm concentrations would be missed when using the laboratory cut-off values. However, with careful counseling, most adult men (94.5%) were found to be willing to provide a semen sample which will yield direct evidence of impaired spermatogenesis. How the semen characteristics will evolve with the aging individual and which boys should opt for cryopreservation remains a point of debate and should be determined based on future studies.

In the final part of the PhD project, the underlying mechanisms in the development of hypospadias were sought. Androgen receptor expression in foreskin samples was found not to be different between boys born with hypospadias, versus healthy controls (7). Instead, age was found to be the principle determinant of androgen receptor expression, correlating with the phases in life during which there are high androgen levels (i.e. minipuberty and puberty). Although we failed to find differences in AR expression, these data do not exclude impaired androgen receptor functionality or downstream defects. Based on our data, when exploring the role of the androgen receptor in the development of hypospadias, strict age matching appears to be crucial. In-depth genetic tests were performed using whole exome sequencing to assess monogenic causes of hypospadias as well as oligenic variant combinations using the Oligogenic Resource for Variant Analysis (ORVAL) online platform (8). No monogenic variants or oligogenic variant combinations were found to be (likely) pathogenic as only variants of unknown significance were withheld. These findings suggest a multifactorial origin of hypospadias in which environmental and placental factors could play an important role as demonstrated by the higher incidence of hypospadias in SGA boys (9). We therefore do not recommend routine use of resource consuming gene panel testing, even in severe forms of hypospadias unless if an underlying syndrome is suspected.

## Conclusion

Most men born with hypospadias are satisfied with their urogenital outcome and support childhood hypospadias surgery. As a result, the psychosexual outcome of this group of men is generally not diminished compared to typical male peers. Nonetheless, complications following hypospadias repair are very common. They can arise long after the initial surgery, and can impact the psychosexual and urogenital outcome. Therefore, current practice should be optimized, and urological post-surgical follow-up during decades is recommended, including sometimes psychological guidance to some patients and sometimes their parents. Furthermore, multidisciplinary management of boys born with hypospadias is needed as growth and spermatogenesis are a major point of concern in some subgroups of men born with hypospadias. The exact cause of hypospadias remains elusive but is likely multifactorial and warrants further studies.

## REFERENCES:

1. Springer A, van den Heijkant M, Baumann S. Worldwide prevalence of hypospadias. *J Pediatr Urol.* 2016 Jun 1;12(3):152.e1-152.e7. doi: 10.1016/J.JPUROL.2015.12.002
2. Tack LJW, Springer A, Riedl S, Tonnhofer U, Weninger J, Hiess M, et al. Psychosexual Outcome, Sexual Function, and Long-Term Satisfaction of Adolescent and Young Adult Men After Childhood Hypospadias Repair. *J Sex Med.* 2020 Sep;17(9):1665–75. doi: 10.1016/j.jsxm.2020.04.002
3. Tack LJW, Springer A, Riedl S, Tonnhofer U, Hiess M, Weninger J, et al. Adolescent and Young Adult Urogenital Outcome following Childhood Hypospadias Repair: Perfection Revisited. *J Urol.* 2021 Sep;206(3):734-44. doi: 10.1097/JU.0000000000001869
4. Skakkebaek NE, Rajpert-De Meyts E, Main KM. Testicular dysgenesis syndrome: an increasingly common developmental disorder with environmental aspects: Opinion. *Hum Reprod.* 2001 May;16(5):972–8. doi: 10.1093/humrep/16.5.972
5. Tack LJW, van der Straaten S, Riedl S, Springer A, Holterhus PM, Hornig NC, et al. Growth, puberty and testicular function in boys born small for gestational age with a nonspecific disorder of sex development. *Clin Endocrinol (Oxf).* 2022 Feb;96(2):165–74. doi: 10.1111/CEN.14614
6. Hokken-Koelega ACS, De Ridder MAJ, Lemmen RJ, Den Hartog H, De Muinck Keizer-Schrama SMPF, Drop SLS. Children born small for gestational age: Do they catch up? *Pediatr Res.* 1995;38(2):267–71. doi: 10.1203/00006450-199508000-00022
7. Tack LJW, Praet M, Van Dorpe J, Haid B, Buelens S, Hoebeke P, et al. Androgen receptor expression in preputial dartos tissue correlates with physiological androgen exposure in congenital malformations of the penis and in controls. *J Pediatr Urol.* 2020 Feb;16(1):43.e1-43.e8. doi: 10.1016/j.purol.2019.10.031
8. Renaux A, Papadimitriou S, Versbraegen N, Nachttegaal C, Boutry S, Nowé A, et al. ORVAL: a novel platform for the prediction and exploration of disease-causing oligogenic variant combinations. *Nucleic Acids Res.* 2019 Jul 1;47(W1):W93–8. doi: 10.1093/nar/gkz437
9. Gatti JMM, Kirsch AJJ, Troyer WAA, Perez-Brayfield MRR, Smith EAA, Scherz HCC. Increased incidence of hypospadias in small-for-gestational age infants in a neonatal intensive-care unit. *BJU Int.* 2001 Apr 1;87(6):548–50. doi: 10.1046/j.1464-410X.2001.00088.x

Figure 1 : Summary of recommendations for the follow-up of boys/men born with hypospadias.

Assess need for psychological / psychosexual counseling				
Follow-up				
(Pediatric) urologist*	<p><b>Therapeutic options:</b></p> <ul style="list-style-type: none"> <li>• Consider minimal touch</li> <li>• Avoid surgery &lt;12 months</li> <li>• Avoid re-interventions when possible</li> </ul>	<ul style="list-style-type: none"> <li>• Patient's genital perception</li> <li>• Uroflowmetry when possible</li> </ul>	<ul style="list-style-type: none"> <li>• Patient's genital perception</li> <li>• Uroflowmetry</li> <li>• Pubertal onset/progression</li> <li>• Erectile/ejaculatory problems</li> <li>• Discuss fertility screening</li> <li>• Consider testicular ultrasound</li> </ul>	<ul style="list-style-type: none"> <li>• Patient's genital perception</li> <li>• Uroflowmetry</li> <li>• Erectile/ejaculatory problems</li> <li>• Discuss fertility screening</li> <li>• Consider testicular ultrasound</li> </ul>
	<p><b>Refer to: Complex / Proximal hypospadias or SGA</b></p> <p><b>Complex / Proximal hypospadias:</b></p> <ul style="list-style-type: none"> <li>• Blood sampling during meplatibity</li> <li>• Consider stimulation test in selected cases</li> <li>• Karyotype + Additional genetic work-up if syndrome is suspected</li> <li>• Discuss future fertility screening</li> </ul> <p><b>SGA:</b></p> <ul style="list-style-type: none"> <li>• Assess growth at 4-5 years, initiate growth hormone therapy if eligible</li> <li>• Discuss future fertility screening</li> </ul>	<p><b>Discuss:</b></p> <ul style="list-style-type: none"> <li>• Fertility screening</li> <li>• Testicular ultrasound</li> </ul> <p><b>Delayed / non-progressive puberty:</b></p> <ul style="list-style-type: none"> <li>• Hormonal work-up</li> <li>• Consider genetic work-up</li> </ul> <p><b>SGA:</b></p> <ul style="list-style-type: none"> <li>• Continue GH therapy until final height is reached</li> </ul>	<p><b>Fertility screening:</b></p> <ul style="list-style-type: none"> <li>• Complex hypospadias</li> <li>• SGA and hypospadias</li> <li>• If requested by patient after counseling</li> </ul> <p><b>Testicular ultrasound:</b></p> <ul style="list-style-type: none"> <li>• Complex hypospadias</li> <li>• On clinical indication</li> </ul>	<p>*Time points:</p> <ul style="list-style-type: none"> <li>• Infancy</li> <li>• Post-surgical:               <ul style="list-style-type: none"> <li>• 1 week</li> <li>• 3 months</li> <li>• 6 months</li> </ul> </li> <li>• Posty training               <ul style="list-style-type: none"> <li>• 6 years</li> <li>• 10-12 years</li> <li>• 16-17 years</li> </ul> </li> <li>• Adulthood: when problems arise</li> </ul>
Pediatric endocrinologist or andrologist	<p><b>Refer to: Complex / Proximal hypospadias or SGA</b></p> <p><b>Complex / Proximal hypospadias:</b></p> <ul style="list-style-type: none"> <li>• Blood sampling during meplatibity</li> <li>• Consider stimulation test in selected cases</li> <li>• Karyotype + Additional genetic work-up if syndrome is suspected</li> <li>• Discuss future fertility screening</li> </ul> <p><b>SGA:</b></p> <ul style="list-style-type: none"> <li>• Assess growth at 4-5 years, initiate growth hormone therapy if eligible</li> <li>• Discuss future fertility screening</li> </ul>	<p><b>Discuss:</b></p> <ul style="list-style-type: none"> <li>• Fertility screening</li> <li>• Testicular ultrasound</li> </ul> <p><b>Delayed / non-progressive puberty:</b></p> <ul style="list-style-type: none"> <li>• Hormonal work-up</li> <li>• Consider genetic work-up</li> </ul> <p><b>SGA:</b></p> <ul style="list-style-type: none"> <li>• Continue GH therapy until final height is reached</li> </ul>	<p><b>Fertility screening:</b></p> <ul style="list-style-type: none"> <li>• Complex hypospadias</li> <li>• SGA and hypospadias</li> <li>• If requested by patient after counseling</li> </ul> <p><b>Testicular ultrasound:</b></p> <ul style="list-style-type: none"> <li>• Complex hypospadias</li> <li>• On clinical indication</li> </ul>	<p>*Time points:</p> <ul style="list-style-type: none"> <li>• Infancy</li> <li>• Post-surgical:               <ul style="list-style-type: none"> <li>• 1 week</li> <li>• 3 months</li> <li>• 6 months</li> </ul> </li> <li>• Posty training               <ul style="list-style-type: none"> <li>• 6 years</li> <li>• 10-12 years</li> <li>• 16-17 years</li> </ul> </li> <li>• Adulthood: when problems arise</li> </ul>
	General pediatrician or practitioner	<p><b>Document:</b></p> <ul style="list-style-type: none"> <li>• Severity of underfertilization</li> <li>• Birth weight/length+gestational age</li> </ul> <p><b>Consider:</b></p> <ul style="list-style-type: none"> <li>• Umbilical syndrome</li> <li>• CAH (bilateral cryptorchidism)</li> <li>• Early referral</li> </ul>	<p><b>Special attention:</b></p> <p>Growth in SGA boys</p>	<p><b>Refer to urological complaints / infections</b></p> <p><b>Special attention:</b></p> <p>Pubertal onset and progression</p>
Prenatal / Neonatal	Childhood	Adolescence	Adulthood	

In collaboration with Cebam, Cochrane Belgium  
(<http://belgium.cochrane.org>)

## Music therapy for autistic people

Anne-Catherine Vanhove, Trudy Bekkering, Filip Cools

Cochrane Belgium, Belgian Centre for Evidence-Based Medicine (Cebam)

[info@cochrane.be](mailto:info@cochrane.be)

### Question

What are the effects of music therapy (alone or added to standard care) for autistic people?

### Context

Autism is a lifelong neurological condition that usually manifests in early childhood. Social interaction and social communication are the central areas of difficulty for autistic people. Music therapy uses music experiences and the relationships that develop through them and is delivered by a professional music therapist. The therapy enables people to relate to others, to communicate and to share their feelings. In this way, music therapy addresses the core challenges for autistic people. The application of music therapy requires specialized academic and clinical training which allows the music therapists to tailor the intervention to meet the individual's therapeutic goals and their specific needs. The aims in music therapy for autistic people can be wide including the work on communication and interaction, sensory processing and integration, affect regulation as well as creative and recreational needs that can lead to increased quality of life.

The Cochrane review update aimed to assess the effects of music therapy for autistic people, including children. The present version is an update of the previous review update published in 2014 with the original Cochrane review published in 2006.

### Criteria for study selection

The review included studies comparing music therapy as a standalone or added to standard care with placebo, no treatment or standard care in people with a diagnosis of autism spectrum disorder. Placebo therapy consists of a similar intervention without the elements specific to music therapy such as play therapy without music, or music listening without interaction with a music therapist. The primary outcomes included global improvement, social interaction, non-verbal communication, verbal communication, quality of life, total autism symptom severity and adverse events.

### Summary of the results

This review update included 16 new studies bringing the total number of included studies to 26 (with 1165 participants). Twenty-one studies included young children aged from two to 12 years. The other five studies included children, adolescents and/or young adults. Severity levels, language skills and cognition varied widely. The studies mostly investigated the short- and medium term effects of music therapy interventions with the intervention lasting from three days to eight months. Music was provided either individually or in group settings. Most studies were conducted in North America (12 studies) and Asia (seven studies), with four studies conducted in Europe.

Immediately after the intervention, music therapy, compared to placebo therapy or standard care, probably results in global improvement (RR\*: 1.22 (95% CI<sup>^</sup>: 1.06 to 1.40); 8 studies, 583 participants, moderate-certainty evidence) and in a slight increase in quality of life (SMD<sup>§</sup>: 0.26 (95% CI: 0.06 to 0.49); 3 studies, 340 participants, moderate-certainty evidence). Moreover, music therapy probably results in a large decrease in total autism symptom severity (SMD: -0.83 (95% CI: -1.41 to -0.24); 9 studies, 575 participants, moderate-certainty evidence). Music therapy compared to placebo therapy and standard care may make little or no difference to social interaction or non-verbal communication

immediately post-intervention (low-certainty evidence), though they may improve during the intervention. We are uncertain about its effects on verbal communication (very low-certainty evidence). Only two studies investigated adverse events. One of them reported no adverse events, while the other found very few adverse events (mainly pre-planned institutional stays) in both control and intervention group. This results in a very wide confidence interval and the range where the actual effect may be includes both an increase as well as a decrease in adverse events (RR: 1.52 (95% CI: 0.39 to 5.94); 2 studies, 326 participants, moderate-certainty evidence).

Unfortunately, very few studies examined the long-term effects of music therapy. Most studies measure outcomes immediately after the intervention i.e. within a month of concluding the therapy. Only one study studied outcomes between 6-11 months post intervention. Moreover, for some of the outcomes the certainty of the evidence remains limited mostly due to issues with the study design and lack of blinding: those who measured the outcomes often knew whether or not participants had received music therapy which may have influenced their assessments.

Compared to earlier versions of the review, however, the new studies helped to increase the certainty and applicability of this review's findings due to larger sample sizes, extended age groups, longer intervention durations and the use of validated scales measuring generalized behavior (e.g. behavior outside of the therapy context). The interventions in the newer studies also corresponded well with music therapy in clinical practice concerning methods and settings

### Conclusion

Music therapy probably increases the chance of global improvement and probably results in a slight increase in quality of life and in a large decrease in total autism symptom severity immediately post-intervention. It may increase social interaction and non-verbal-communication during the intervention but not afterwards. The evidence on verbal communication is uncertain.

### Implications for practice

This update shows that music therapy can not only have an effect on outcomes measuring autism symptom changes but also general domains such as quality of life which is very important to patients and their families. The fact that skills seem to improve during but not after the intervention could be due to the known challenge of skill generalization across contexts and interaction partners.

#### REFERENCE:

Geretsegger M, Fusar-Poli L, Elefant C, Mössler KA, Vitale G, Gold C. Music therapy for autistic people. Cochrane Database of Systematic Reviews 2022, Issue 5. Art. No.: CD004381.DOI: 10.1002/14651858.CD004381.pub4.

Access the full text of these reviews via the Cebam Digital Library for Health ([www.cebam.be/nl/cdlh](http://www.cebam.be/nl/cdlh) or [www.cebam.be/fr/cdlh](http://www.cebam.be/fr/cdlh))

\* RR: risk ratio

<sup>^</sup> CI: confidence interval

<sup>§</sup> SMD: standardized mean difference

# Editorial Policy

## Aims and scope

*The Belgian Journal of Paediatrics (BJP)* is the Official Journal of the Belgian Society of Paediatrics.

*The Belgian Journal of Paediatrics* publishes peer reviewed original articles, review articles, short communications and case reports on all aspects of paediatrics. In addition, all official reports of the Belgian Academy of Paediatrics are published in the journal.

The Belgian Journal of Paediatrics aims to connect all Belgian paediatricians with stimulating, scientifically sound, peer-reviewed articles.

The Journal is published quarterly. The journal is available in a printed version and electronic version. The electronic version is accessible through the website of the Belgian Society of Paediatrics at <https://bvksbpb.be/bjp.php>.

## Editors

Editors-in-Chief: M. Raes, C. Chantrain

Associate editors: C. Barrea, O. Danhaive, I. Decuyper, S. Derechter, E. Duval, N. Francotte, L. Hoste, L. Panneel, A. Rochtus, Y. Vandenas, K. Van De Maele, K. van Hoeve, A. Vuckovic, M. Wojciechowski

Editorial office: N. Meignen, UZ Leuven, Herestraat 49, 3000 Leuven

Publisher: Vivactis, Gustave Demey Avenue 57, B-1160 Auderghem, Belgium.

Owner: Belgische Vereniging voor Kindergeneeskunde –  
Soci t  de P diatrie

## Editorial principles

**Editorship:** All papers at *Belgian Journal of Paediatrics* are previewed by a member of the editorial team. Papers that are of sufficient novelty and impact for publication are forwarded for peer review. Other papers are returned without review after editorial decision. If one of the editors has a conflict of interest with a submitted manuscript or with the authors, he or she will abstain from the editorial board decision process.

**Invited Editors:** Invited Editors are appointed by the Editors to coordinate the compilation of a special chapter of the Journal dedicated to a particular subject. They choose the topics of the chapter, they contact the authors with expertise in the field and protect the expected deadlines for the reviews. In addition, they write an editorial letter for the special chapter.

**Manuscript submission:** Guidelines for preparing and submitting manuscripts are described in the section 'Instructions for authors'. No publication fee is charged, neither for the manuscript nor for illustrative figures whether or not in colour. The editors will ensure the confidentiality of the author's work.

**Authorship criteria:** Authors should meet the criteria for authorship according to the recommendations of International Committee of Medical Journal Editors (ICMJE) available at [www.icmje.org](http://www.icmje.org). Only persons that have substantially contributed to all of the following are considered as authors: conception and design, acquisition, analysis and interpretation of data; drafting the article or revising it critically; final approval of the version published. The corresponding author should declare in the online submission that these criteria have been satisfied. Persons who have contributed to the study or manuscript but who do not fulfil the criteria for authorship have to be listed under a heading 'acknowledgments'. Financial and material support should also be acknowledged. Any change in authors after initial submission must be approved by all authors and must be explained to the Editor. The Editor may contact any of the authors and / or contributors to verify whether they agree to any change. The authors are fully responsible for the propositions and statements in their article. Although the Editors try to recognize and reject misconduct to the best of their ability, neither the Editorial Board of the Belgian Journal of Paediatrics, nor the Executive Board of the Belgian Paediatric Society are responsible for malpractice by authors.

**Misconduct:** Reviewers of the manuscripts and readers of the journal are encouraged to report malpractice. Whenever misconduct is effectively established, the Editors will notify the author's institution and inform the readers of the Journal.

**Copyright:** By accepting publication in the Belgian Journal of Paediatrics authors automatically transfer copyright to the journal.

**Ethical standards:** Human subjects research requires ethics committee approval. This should be documented in the 'methods' section of the paper. It is the author's

responsibility to ensure that a patient's anonymity is carefully protected. Information that could possibly identify patients should not be included in the paper, unless the information is essential for scientific purposes and a written informed consent for publication was obtained from patients and both their parents or guardians. This should be added as a separate page(s) to the manuscript. Even when consent was given, identifying details should be omitted if not essential. Special attention should be given to patient's images, names, initials, hospital numbers.

The registration number and the site of registry of clinical trials should be provided in the 'methods' section of the manuscript.

When reporting experiments on animals, authors should indicate whether the institutional rules and/or national legislation for the care and use of laboratory animals was respected.

**Negative studies:** The Belgian Journal of Paediatrics agrees with the International Committee of Medical Journal Editors statement regarding the obligation to publish negative studies.

**Duplicate or prior publication:** Only original manuscripts that have not been published before (except in the form of an abstract or as part of a published lecture or a thesis) can be accepted.

**Reproduction of material from other sources:** any written or illustrative material that has been or will be published elsewhere must be duly acknowledged and accompanied by the written consent of the copyright holder and credit the source(s) in the article.

**Publication embargo:** Every submission accepted for publication in the Belgian Journal of Paediatrics is under embargo until it is published. This means that until then it may not be disclosed to third parties. However, prior presentation of study data as an abstract or poster at a scientific meeting is acceptable, as well as publication of abstracts in print and online conference proceedings, but authors should not distribute copies of the original manuscript.

**Peer review:** All received papers will be peer reviewed after editorial approval by at least two external and independent reviewers solicited by the Editors. In order to avoid conflicts of interest, these reviewers cannot belong to the same institution as the authors. Following the review process, a decision will be made to accept as such or with minor or major revisions, or to reject. In case of controversy or strong disagreement regarding the merits of the work, an additional review may be solicited or one of the journal's editors might give an evaluation. The reviewers' names will be blinded to the authors. Manuscripts will be resubmitted to the reviewers after revision by the authors if the manuscript satisfactorily addresses the comments from the reviewers and editors. The editors are responsible for the final decision to accept or reject a manuscript. Authors will be notified about the decision and, if the manuscript is accepted, the timing of publication. Roles and responsibilities of peer reviewers are described in the section 'Instructions for peer reviewers'.

**Advertising:** Advertisers are not allowed to influence or modify the content of accepted articles before publication. Advertisement of products like alcohol, tobacco or products known to be harmful for children's health are not allowed in the journal. Editors have the final authority to accept advertisements in each published issue of the Journal. Each advertisement is clearly identified as such and is not inserted in the body of the manuscript. The Belgian Society of Paediatrics oversees the advertising policy of the Journal.

The Editors are not responsible for the advertising on linked sites of the electronic version of the journal.

**Complaints:** Complaints regarding Editorial decisions have to be addressed to the Editorial Office [bjp@belgijpaediatrics.be](mailto:bjp@belgijpaediatrics.be). All complaints will be analysed by the Editorial Team and a detailed answer will be provided.

## Instructions for authors

### Journal Sections

*The Belgian Journal of Paediatrics publishes the following types of manuscripts:*

**Research Articles:** Research articles are papers reporting the results of original research (clinical study, clinical trial, meta-analysis). Articles are limited to 250 words for the Abstract, 500 words for the Introduction, 1500 words for the Discussion and overall 4500 words, 30 references and eight figures or tables. Note that BJP does not permit supplementary material, hence all of the methods and results must be described in the body of the paper. We ask authors to aim for accuracy, clarity and

brevity and to not describe results in detail that are clearly shown in a table or figure. We encourage the use of the EQUATOR reporting guidelines (<https://www.equator-network.org>). For clinical trials and clinical studies the number and place of approval by an ethical committee has to be mentioned in the methodology section, as well as the registration number and the site of registry for clinical trials.

**Review Articles:** Review articles are broadly based and are meant to cover an important field in an authoritative way. Reviews should include an abstract of no more than 250 words and have a mean text range between 1500-4000 words, with up to 30 references.

- Systematic Review: A PRISMA style flow diagram has to be included (<http://prismastatement.org/PRISMAStatement/FlowDiagram.aspx>).

- Narrative Review: A narrative review gives an update on the current understanding of the pathophysiology, diagnosis and treatment of a disease. A narrative review may be illustrated by one or more case descriptions.

**Case Reports:** Case reports are limited to an abstract of 100 words, main text of 1500 words, three tables and/or figures, and 10 references. Authors are encouraged to follow the CARE Case Report Guidelines (<https://www.care-statement.org>).

**Short Communications:** Short Communications are limited to an abstract of 100 words, main text of 1500 words, 1 table and/or 1 figure, and 10 references.

- Brief communication: Contains reports of original research. Can include any of the study types listed under Research Articles.

- Made in Belgium: Summary of a PhD thesis defended in Belgium. The title of the PhD thesis must be followed by a subtitle "PhD thesis presented on [date] at [university or high school], [city], Belgium. The author is the PhD student. Promoters and co-promoters are listed under the author.

- Focus on symptoms: A short schematic or algorithmic approach to symptoms with which a clinician is regularly confronted. For this article type, no abstract is requested.

**Correspondence to the Editor:** Correspondence to the Editor should be limited to 400 words and may include one table or figure, if essential, and five or fewer references. Two types of correspondence are accepted:

- Letters to the Editor addressing previously published articles.

- Personal opinion: can address any important topic in paediatric medicine, public health, research, discovery, prevention, ethics and commentaries on all aspects of paediatrics.

**Reviews of books:** Book reviews related to paediatrics can be submitted by authors who want to share their experience with the readers of the journal. Book reviews should not exceed 500 words. The editors take the decision whether or not to publish.

## Submission information

Manuscripts must be submitted online at <http://belgijaediatrics.be/index.php/bjp/submissions>.

### Outline of the online submission process

The online submission platform consists of five modules: 'Start', 'Upload Submission', 'Enter Metadata', 'Confirmation', 'Next Steps'.

#### 1. 'Start'

1.1. Make a choice of section and category of the manuscript.

1.2. Check all submission requirements.

1.3. Comments for the editor: authors can provide a brief explanation of why the manuscript should be considered for publication in the Belgian Journal of Paediatrics and mention additional information that may be useful to the editor.

1.4. Check author under 'Submit As'.

1.5. Check 'Acknowledge the copyright statement'.

#### 2. 'Upload submission'

2.1. Pay attention please: in this module only the manuscript body and supplementary files (such as figures, tables, authorizations, parental consent, or other supplements) can be uploaded. The title, abstract, authors' names

and affiliations and keywords should be entered in the metadata module.

2.2. Manuscripts should be submitted as single-line spaced Word files in Arial font size 10.

2.3. Please read carefully and apply the editorial rules underneath before submitting your manuscript.

#### 3. 'Enter Metadata'

3.1. Title, abstract, list of contributors and keywords

3.2. Authors should be entered in the list of contributors. Author's affiliation, e-mail address, and other personal data can be edited. The order of authors and corresponding author (principal author) can be defined.

4. Confirmation: go back to review and adjust any of the information you have entered before continuing. When you are ready, click "Finish Submission".

**Authors** should meet the criteria for authorship according to the "Uniform Requirements for Manuscripts Submitted to Biomedical Journals: Writing and Editing for Biomedical Publication" available at [www.icmje.org](http://www.icmje.org). Each person listed as an author is expected to have participated in the manuscript to a significant extent. Persons who have contributed to the study or manuscript but who do not fulfil the criteria for authorship have to be listed under a heading 'acknowledgments'. Although the editors and reviewers make every effort to ensure the validity of published manuscripts, the final responsibility rests with the authors, not with the Journal, its editors, or the publisher.

**Language:** Manuscripts must be submitted in English. The chosen English spelling, UK or US spelling must be used consistently throughout the article. It is recommended that authors, who are not very familiar with English, are strongly encouraged to seek assistance in writing the article.

### Scientific writing:

- Bacteria names should be italicized, e.g. *Staphylococcus aureus*. After writing the complete name of a microorganism upon first use, the genus name can be shortened to just the capital letter, e.g. *S. aureus*. When discussing unnamed species the abbreviation 'sp.' is used to refer to a single unnamed species, and 'spp.' refers to more than one unnamed species. More information can be found at <https://www.enago.com/academy/write-scientific-names-in-a-research-paper-bacteria/>.

- Virus names (the organism that makes you sick) should not be italicized. Virus species names should be written in italics and should not be abbreviated. More information can be found at <https://talk.ictvonline.org/information/w/faq/386/how-to-write-virus-species-and-other-taxa-names>.

- Gene symbols should be italicized, e.g. CFTR gene. Full written gene names should not be italicized, e.g. cystic fibrosis transmembrane conductance regulator gene. Gene products should not be italicized, e.g. CFTR protein. More information can be found at <https://insight.jci.org/kiosks/publish/genestyle>.

Information that may allow identification of patients: information that could possibly identify patients should not be included in the paper, unless the information is essential for scientific purposes. A signed informed consent from patients and their parents or legal guardians authorizing publication should be added as a separate file to the manuscript.

**Abstracts:** Abstracts should not contain references. Preferably, abbreviations should not appear in abstracts. However, if important for readability two or three different abbreviations can be accepted. These abbreviations should be spelled out at their first occurrence in the abstract. Abstracts for Research articles must be limited to 250 words and must be structured to the following headings: Objective, Methods, Results, Interpretation / Conclusion. Abstracts for Case reports or Short Communications must be limited to 100 words and should not include subsections.

**Abbreviations:** Always spell out abbreviations at first mention and place the acronym or abbreviation in parentheses immediately after. All subsequent uses, including tables and figures, should use the abbreviation or acronym. Abbreviations should be limited to terms that are both long and frequently (more than three times) repeated in the text. Try to avoid using more than six abbreviations in a paper,

otherwise the text appears to be written in code.

**Text:** Organise the manuscript according to the instructions in the article type section. Sections must appear in the following order: Introduction, Materials and Methods, Results, and Discussion, Conclusion, Acknowledgements if any, Conflicts of Interest, References, Figure legends. Acknowledgements should include individuals who have contributed to the work (provided materials, technical assistance, etc.), but do not fulfil the criteria for authorship; all such individuals should agree to being included in this way before the manuscript is submitted. The Acknowledgements should also include sources of financial support for the work.

**Data Analysis:** Description of data analysis should provide the specific methods used, their rationale, the underlying assumptions, whether data met those assumptions, and how any missing data were handled.

Units of measurement and laboratory values: Follow internationally accepted rules and conventions: use the international system of units (SI). If other units are mentioned, please give their equivalent in SI. If applicable, normal values should be given in parenthesis when the value is first stated.

Drugs and other products: non-proprietary names of drugs or other products should be used, unless a specific trade name is essential for discussion.

Eponyms and acronyms: Eponyms should be used in their non-possessive form (e.g. Down syndrome and not Down's syndrome). Acronyms should be avoided. If this is not possible, they should be fully explained when first used.

Tables: Tables should be printable in a single page in portrait orientation. They should be typed in the same font as the rest of the paper, as text tables (rather than as figures). Screen captured tables are not allowed. Tables should be numbered in order of appearance in the text. Tables and their legends should be submitted as separate files.

**Figures:** All figures must be submitted as separate files in JPEG format. Do not submit your figures embedded in a Microsoft Word or Adobe PDF document (i.e., as a .DOC or a .PDF file). The resolution must be at least 600 dpi. Figures should be cited in order of appearance. Each figure must have a legend. Figure legends should appear after the References, as part of the main document of the paper.

Please do not include extra text (including keys and headings) in the artwork, spell out keys and headings in the figure legend instead. Photographs of recognizable persons should be accompanied by a signed release from the patient or legal guardian authorizing publication, as described above. Masking eyes to hide identity is not sufficient.

Patient privacy, informed consent and ethical standards: If the work involves the use of human subjects, the author should ensure that the work has been carried out in accordance with The Code of Ethics of the World Medical Association (Declaration of Helsinki) for experiments involving humans. Authors should include a statement in the manuscript that written informed consent was obtained from the parents or guardians of the children who served as subjects of the study and, when appropriate, assent from the patients themselves. For clinical trials and clinical studies the number and place of approval by an ethical committee has to be mentioned in the 'methods' section, as well as the registration number and the site of registry for clinical trials. The privacy rights of human subjects must always be observed. Race / ethnicity, gender or religion should only be mentioned if relevant to the content or purpose of the article.

**Animal rights:** All animal experiments should comply with the ARRIVE guidelines and should be carried out in accordance with EU Directive 2010/63/EU for animal experiments, or the National Institutes of Health guide for the care and use of Laboratory animals (NIH Publications No. 8023, revised 1978) and the authors should clearly indicate in the manuscript that such guidelines have been followed. The sex of animals must be indicated, and where appropriate, the influence (or association) of sex on the results of the study.

**References:** Arrange references in order of first appearance in the text. The references must be formatted according to Vancouver style (Quick reference guide available from: [https://guides.lib.monash.edu/ld.php?content\\_id=48260115](https://guides.lib.monash.edu/ld.php?content_id=48260115)).

Reference numbers in the text must be put at the end of the sentence, between brackets and inside the punctuation. Separate by a comma if more than one reference is cited, for example (1,5,8). For sequences of consecutive numbers, the

first and last number of the sequence should be separated by a hyphen, for example (1-4). Only published papers or papers in press should be included in the reference list. Personal communications or unpublished data must be cited in parentheses in the text with the author's names, the source and year.

The reference list, numbered in the order of mention in the text, must appear at the end of the manuscript.

#### **For journal articles:**

Authors. Title of the Article. Name of the Journal. Publication year;Volume number (Issue number);pagination. According to the Uniform Requirements the first six authors are named, followed by et al. if there's more than six. Authors are referenced as their surname followed by initials. Separate authors' names by a comma if more than one author. Abbreviate journal titles in the style used in the NLM Catalog (available from: <https://www.ncbi.nlm.nih.gov/nlmcatalog/journals/>). If in a journal a volume page numbering goes uninterrupted, the number of the issue may be omitted.

#### **Examples:**

Less than 6 authors:

Gonzalez-Aguero A, Vicente-Rodriguez G, Gomez-Cabello A, Ara I, Moreno LA, Casajus JA. A combined training intervention programme increases lean mass in youths with Down syndrome. *Res Dev Disabil*. 2011;32(6):2383-8.

#### **More than 6 authors:**

Bervoets L, Van Noten C, Van Roosbroeck S, Hansen D, Van Hoorenbeeck K, Verheyen E, et al. Reliability and Validity of the Dutch Physical Activity Questionnaires for Children (PAQ-C) and Adolescents (PAQ-A). *Arch Public Health*. 2014;72(1):47.

#### **For an article published online ahead of the print version:**

Bilal J, Riaz IB, Naqvi SAA, Bhattacharjee S, Obert MR, Sadiq M, et al. Janus Kinase Inhibitors and Risk of Venous Thromboembolism: A Systematic Review and Meta-analysis. *Mayo Clin Proc*. 2021 Apr 8:S0025-6196(21)00054-9. doi: 10.1016/j.mayocp.2020.12.035. Online ahead of print.

#### **For electronic journal articles:**

The word [Internet] in square brackets should be inserted after the abbreviated journal title.

The date cited [in square brackets] must be included after the date of publication.

The URL (web address) must be included at the end of the reference.

For electronic journal articles with a DOI, include the DOI (digital object identifier) at the end of the reference, after the URL

#### **Examples:**

Stockhausen L, Turale S. An explorative study of Australian nursing scholars and contemporary scholarship. *J Nurs Scholarsh [Internet]*. 2011 Mar [cited 2013 Feb 19];43(1):89-96. Available from: <http://search.proquest.com/docview/858241255>

Kanneganti P, Harris JD, Brophy RH, Carey JL, Lattermann C, Flanigan DC. The effect of smoking on ligament and cartilage surgery in the knee: a systematic review. *Am J Sports Med [Internet]*. 2012 Dec [cited 2013 Feb 19];40(12):2872-8. Available from: <http://ajs.sagepub.com/content/40/12/2872> DOI: 10.1177/0363546512458223

#### **For a book:**

Print book: Authors. Title of book. Edition number (if not first). Place of Publication: Publisher; Year of publication. Pagination.

Electronic book: Authors. Title of web page [Internet]. Place of publication: Publisher (or sponsor of website); year published [cited YYYY Mon DD]. Number of pages. Available from: URL DOI: (if available).

#### **Examples:**

##### **For a book:**

Carlson BM. Human embryology and developmental biology. 4th ed. St. Louis: Mosby; 2009. 541 p.

##### **For an electronic book:**

Shreeve DF. Reactive attachment disorder: a case-based approach [Internet]. New York: Springer; 2012 [cited 2012 Nov 2]. 85 p. Available from: <http://dx.doi.org/10.1007/978-1-4614-1647-0>.

### **For a chapter in a book:**

In a print book: Authors. Title of chapter. In: Editor AA, Editor BB, Editors. Title of book. Edition number (if not first). Place of publication: Publisher, year of publication. Start and end page (of chapter).

In an electronic book: Authors. Title of chapter. In: Editor AA, Editor BB, Editors. Title of book [Internet]. Place of publication: Publisher, year of publication. [cited YYYYMonDD]. Page or chapter number/. Available from: URL DOI (if available) .

### **Example:**

#### **In a print book:**

Meltzer PS, Kallioniemi A, Trent JM. Chromosome alterations in human solid tumors. In: Vogelstein B, Kinzler KW, editors. The genetic basis of human cancer. New York: McGraw-Hill; 2002. p. 93-113.

#### **In an electronic book:**

Halpen-Felsher BL, Morrell HE. Preventing and reducing tobacco use. In: Berlan ED, Bravender T, editors. Adolescent medicine today: a guide to caring for the adolescent patient [Internet]. Singapore: World Scientific Publishing Co.; 2012 [cited 2012 Nov 3]. Chapter 18. Available from: [http://www.worldscientific.com/doi/pdf/10.1142/9789814324496\\_0018](http://www.worldscientific.com/doi/pdf/10.1142/9789814324496_0018)

More examples of other published, particularly material from internet, and unpublished material can be found in the quick Vancouver reference guide ([https://guides.lib.monash.edu/ld.php?content\\_id=48260115](https://guides.lib.monash.edu/ld.php?content_id=48260115)) or on the website of the U.S. National Library of Medicine: [https://www.nlm.nih.gov/bsd/uniform\\_requirements.html](https://www.nlm.nih.gov/bsd/uniform_requirements.html).

Refer to the List of Journals Indexed in Index Medicus for abbreviations of journal names, or access the list at <http://www.nlm.nih.gov/archive/20130415/tsd/serials/lji.html>.

Disclosure of potential conflicts of interest: The corresponding author should disclose any conflict of interest for any of the authors. The disclosure declaration must be written in a separate paragraph after the conclusion and before the references.

### **After submission**

Manuscripts must comply with the guidelines described in the instructions for authors. After submission, the manuscripts are first reviewed editorially. Manuscripts not prepared according to the instructions for authors will be returned to the author(s) before starting the review process.

All manuscripts considered for publication undergo peer review. The editors assign at least two external and independent reviewers. The reviewers' names are blinded to the authors. Reviewers are requested to maintain the confidentiality of the review process: not sharing, discussing with third parties, or disclosing information from the reviewed paper.

When resubmitting a manuscript after review the authors should indicate clearly their responses to the reviewers' comments. A document in which the reviewers' comments are answered point by point should be provided with the revised manuscript and include a copy of the original manuscript with track changes displaying the changes made. All co-authors should approve the revised manuscript version. The corresponding author should confirm approval in the point-by-point answer document. All components of the manuscript (point-by-point response letter, clean revised manuscript, manuscript with track changes, figures, tables, etc.) must be resubmitted even if no changes have been made at revision. To submit a revision, go to [bjp@belgipaediatrics.be](mailto:bjp@belgipaediatrics.be) and log in as an Author. Your submission record can be found by clicking on "View" → "Revisions" → "Upload file".

### **After acceptance**

Corresponding authors will receive electronic page proofs to check the copy-edited and typeset article before publication. Portable document format (PDF) files of the typeset pages and support documents will be sent to the corresponding author by e-mail. It is the author's responsibility to ensure that there are no errors in the proofs. Changes that have been made to conform to journal style will stand if they do not alter the authors' meaning. Only the most critical changes to the accuracy of the content will be made, no substantial changes can be made at this point. The publisher reserves the right to deny any changes that do not affect the accuracy of the content. Proofs must be checked carefully, and corrections returned within

1 week of reception. Any errors found after this time will result in an erratum and not an article correction.

Publication embargo: Publication embargo as described in the editorial policy section applies until effective publication of an accepted manuscript.

Corrections: Requests to publish corrections should be sent to the editorial office. Corrections are reviewed by the editors and published in the next journal issue as an erratum.

Copyright: By accepting publication in the Belgian Journal of Paediatrics authors automatically transfer copyright to the journal.

Reprints: Reprints are available from the website of the Belgian Society of Paediatrics at <http://bvksbp.be/bjp/php> .

## **Instructions for peer reviewers**

Review of a submitted manuscript by at least two external and independent reviewers who are solicited by the editors. The reviewers' names will be blinded to the authors. Authors' identities are not blinded to the reviewers.

Reviewers should only agree if they feel qualified to review a manuscript and are able to return the review within a reasonable time-frame of maximum three weeks. If they cannot review, it is helpful to make suggestions for alternative reviewers.

Reviewers must refuse to review a manuscript in case of any potentially conflicting or competing interest.

Reviewers are requested to maintain confidentiality about the manuscripts and the information they contain.

Reviewers must provide a fair, honest, and unbiased assessment of the strengths and weaknesses of the manuscript. Comments to the authors will be passed in full to authors. The reviewers can also provide additional confidential comments to the editors, which will not be passed to the authors.

If the reviewer has concerns about misconduct during the elaboration or submission of the manuscript he must notify the editor. This also applies to the case where the reviewer notices important similarities between the manuscript and a published article.

We are collaborating with platforms such as Publons to give you the recognition you deserve for your peer review contributions. On Publons you can effortlessly track, verify and showcase your review work and expertise without compromising anonymity.

## **Instructions for invited editors**

Each year, a number of issues address a special chapter dedicated to a particular topic. Two guest editors, a Dutch-speaking and a French-speaking, are responsible for the content of these chapters.

A number of six manuscripts per chapter is expected. If more than six articles are needed to elaborate the topic of the chapter correctly, the editors can decide to spread the chapter over two issues.

The tasks of the invited editors are:

- To make choices of topics
- To invite authors
- To supervise the manuscripts in terms of content
- To protect the expected deadline for publication
- To write an editorial introducing the chapter

Editorial review and solicitation of peer reviewers will be done by the editorial team of the BJP.



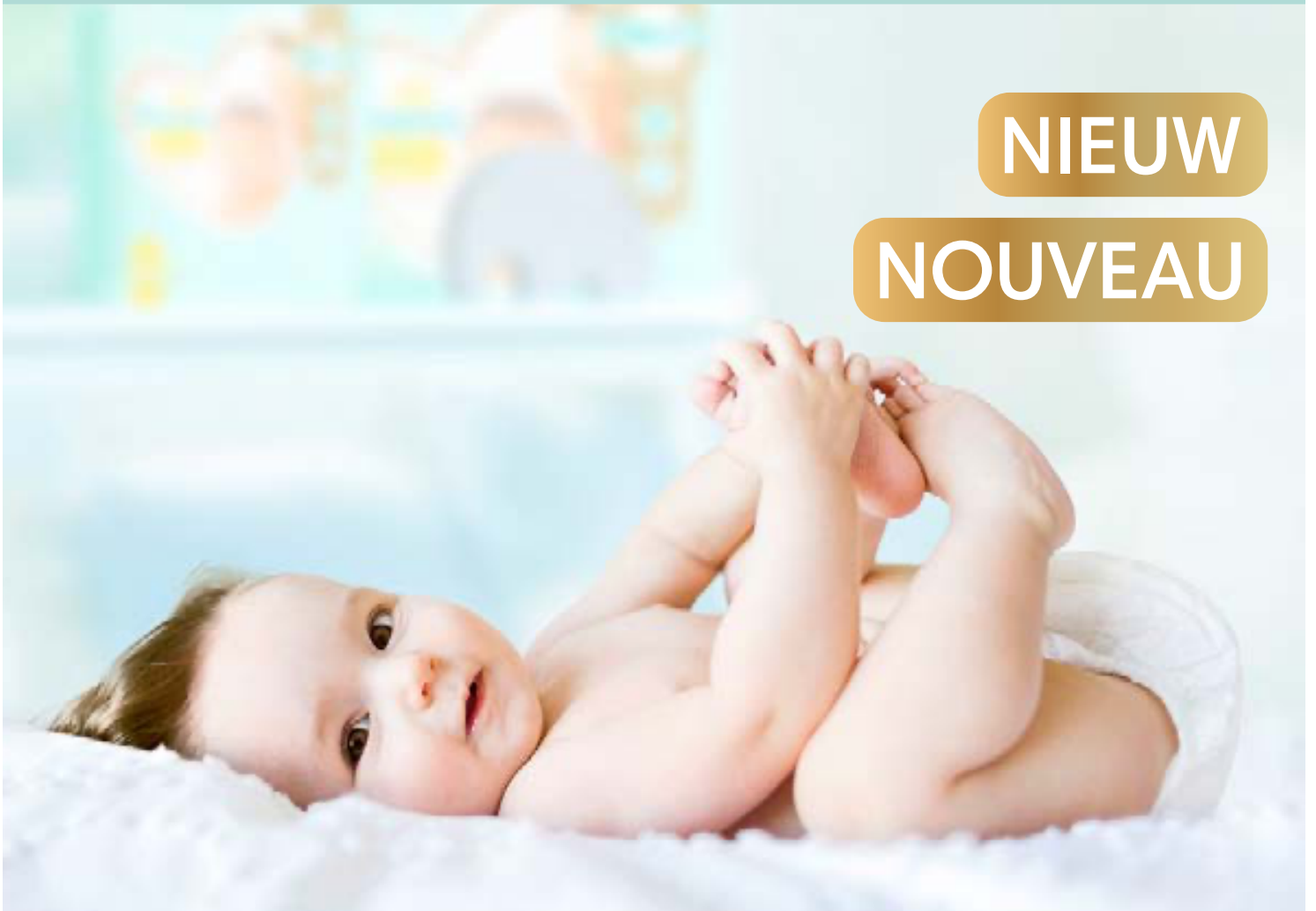Onze n°1 in zachtheid  
en bescherming van  
*de gevoelige huid*

Notre n°1 pour la douceur  
et la protection  
*des peaux sensibles*



**NIEUW**

**NOUVEAU**



Alles voor baby's, en zelfs nog  
een beetje meer.

Tout pour eux.  
Et même un peu plus.

- ✓ Zonder sacharose  
Sans saccharose
- ✓ Zonder aroma  
Sans arômes
- ✓ Zonder additieven  
Sans additifs



VITAMINE D

VEZELS  
FIBRES

PROBIOTICUM LGG+ HMO'S  
PROBIOTIQUE LGG+ HMO'S

ORS + PROBIOTICUM LGG  
ORS + PROBIOTIQUE LGG



CNK : 4265-294



CNK : 4265-302



CNK : 4265-328



CNK : 4265-310

Ontdek **NANCARE®**, een gamma voedingssupplementen en een rehydratieoplossing speciaal ontwikkeld voor baby's.

Découvrez **NANCARE®**, une gamme de compléments alimentaires et une solution de réhydratation spécialement conçues pour les bébés.

Nestlé  
**NANCARE®**  
Partner van hun welzijn  
Partenaire de leur bien-être

BELANGRIJKE INFORMATIE. Borstvoeding is de ideale voeding voor baby's. Voedingssupplementen mogen niet worden gebruikt ter vervanging voor moedermelk, een gevarieerde, evenwichtige voeding of een gezonde levensstijl. De aanbevolen dagelijkse dosis niet overschrijden. Buiten bereik van kinderen bewaren.  
AVIS IMPORTANT : Les compléments alimentaires ne doivent pas être utilisés comme substitut du lait maternel, d'une alimentation variée et équilibrée ou d'un mode de vie sain. Ne pas dépasser la dose journalière recommandée. Tenir hors de portée des enfants.  
VU/E.R. : Sophie Alexander BEO, Nestlé Belgilux SA, Rue de Birminghamstraat 221 - 1070 Bruxelles/Brussel, BCE/KBO 0402.231.383 - PID2868.